

Case Report

# Alleviating speech and deglutition: Role of a prosthodontist in multidisciplinary management of velopharyngeal insufficiency

Aditi Nanda, Dheeraj Koli, Sunanda Sharma, Shalini Suryavanshi, Mahesh Verma  
 Department of Prosthodontics, Maulana Azad Institute of Dental Sciences, New Delhi, India

**Abstract** Surgical resection of soft palate due to cancer affects the effective functioning of the velopharyngeal mechanism (speech and deglutition). With the loss of speech intelligibility, hyper resonance in voice and impaired function of swallowing (due to nasal regurgitation), there is a depreciation in the quality of life of such an individual. In a multidisciplinary setup, the role of a prosthodontist has been described to rehabilitate such patients by fabrication of speech aid prosthesis. The design and method of fabrication of the prosthesis are simple and easy to perform. The use of prosthesis, together with training (of speech) by a speech pathologist resulted in improvement in speech. Furthermore, an improvement in swallowing had been noted, resulting in an improved nutritional intake and general well-being of an individual. The take-home message is that in the treatment of oral cancer, feasible, and rapid rehabilitation should be endeavored in order to make the patient socially more acceptable. The onus lies on the prosthodontist to practise the same in a rapid manner before the moral of the patient becomes low due to the associated stigma of cancer.

**Key Words:** Multidisciplinary, oncology, prosthodontist, speech aid, velopharyngeal defect

**Address for correspondence:**  
 Dr. Aditi Nanda, Department of Prosthodontics, Maulana Azad Institute of Dental Sciences, Room No. 116, Bahadur Shah Zafar Road, New Delhi - 110 002, India. E-mail: aditinanda@yahoo.com  
**Received:** 13<sup>th</sup> March, 2015, **Accepted:** 13<sup>th</sup> June, 2015

**INTRODUCTION**

Tumors of the palatopharyngeal region, (when treated by surgical resection), result in anatomic insufficiency that can reduce the quality of life of the afflicted. Though the life span of the individual increases with the surgical elimination of neoplastic tissue, if the rehabilitation is either not done or is delayed, it can depreciate the quality of life of the afflicted. An efficient coordination of the

(head and neck) surgical and allied health care specialists (including the maxillofacial prosthodontist) in such a situation can help improve the health care service provided to such individuals.<sup>[1,2]</sup>

The palatopharyngeal valve mechanism is primarily associated with regulation of speech and swallowing. Loss of integrity of this mechanism is associated with hypernasality (during speech) and inability to swallow (due to nasal regurgitation). It is the responsibility of the prosthodontist to re-establish the palatopharyngeal integrity in such cases, in order to enable the patient to perform acceptable speech and swallowing.<sup>[3]</sup>

The role of prosthodontists in rehabilitating a patient with palatopharyngeal insufficiency by speech aid prosthesis after a prompt referral from the surgical and allied health care departments (oncology, speech pathology, and nutrition) has been described. The design of the prosthesis and method to fabricate is simple and easy to apply.

Video available on: [www.j-ips.org](http://www.j-ips.org)

Access this article online	
Quick Response Code:	Website: <a href="http://www.j-ips.org">www.j-ips.org</a>
	DOI: 10.4103/0972-4052.161573

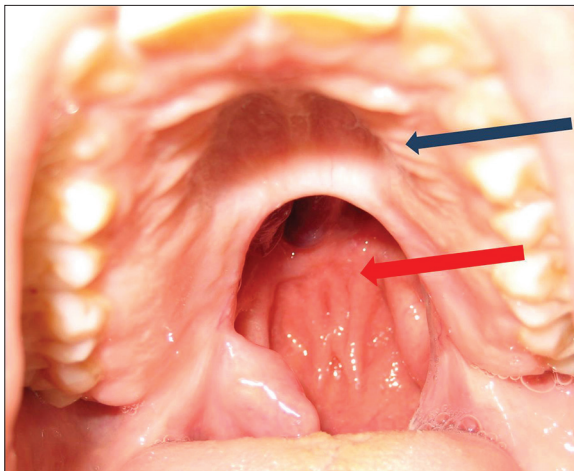
## CASE REPORT

A 60-year-old male patient was referred to the center with velopharyngeal inadequacy. The anatomic deficiency was due to surgical resection. The same was performed to treat squamous cell carcinoma. Surgical resection was done after the clinical findings and biopsy (histopathological findings) confirmed oral squamous cell carcinoma. The patient reported 4 months after surgical resection with the chief complaint of difficulty in swallowing and unclear speech. Following surgical resection the patient had also undergone radiation therapy (total of 44 Gy dose), which was completed 4 weeks before the patient had reported to the center. Extra oral inspection and palpation revealed no relevant findings. Intraoral findings revealed an anatomic deficiency of a portion of the hard palate and soft palate [Figure 1]. A triangle shaped defect extending from the midline (apex of triangle) and covering the junction of hard and soft palate on the left side was seen. The defect included the entire portion of the soft palate on the left side and 1 cm (from the midline) on the right side. The massive extent of the defect caused difficulty in swallowing [Video 1] and during speech (speech intelligibility score of 6 and hypernasality score of 5) [Video 2].<sup>[4]</sup> Full complement of the dentition was present. Mild decrease in saliva content was noted.

### Treatment plan

For the decreased saliva content, the patient was advised to use a saliva substitute spray (Mouth Kote Dry mouth spray, Parnell Pharmaceuticals, Inc., USA). The patient was advised to use it by spraying in the mouth 3–5 times a day, swirl for 8–10 s each time and then spit out.

For the anatomic deficiency of hard palate, an immediate treatment plan was to provide continuity of the velopharyngeal mechanism by artificial prosthesis (speech aid appliance) in heat polymerized polymethyl methacrylate.



**Figure 1:** Preoperative view showing the soft palate insufficiency (red arrow), intact hard palate (blue arrow)

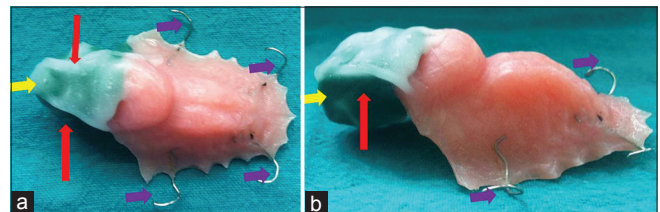
### Fabrication of the appliance

Primary impressions (in irreversible hydrocolloid) were made, and primary model was obtained in Type III gypsum. On the model, a heat polymerized tray, extending to cover the entire recorded area of the defect was formed. This tray was used to record the movement of the posterior pharyngeal wall (blue arrow) and a lateral pharyngeal wall (red arrow). For the same, low fusing compound was adapted to the posterior-most extent of the tray, and the patient was asked to perform side to side movement, bend head in front and back direction following a circular path. Following this the patient was asked to swallow. This helped to record the anterior and posterior tonsillar pillars, tori tubari, Passavant's ridge, and the anterior tubercle of the atlas. Shiny areas (that indicated the lack of tissue contact) were remolded.

Once satisfactory molding was ensured (by speech and swallowing), about 2 mm of the surface of the molded impression was reduced and tissue conditioner was applied all over the surface of the remaining impression. All the molding movements were repeated, and the molded tray was left in the patient's mouth for 1 day [Figure 2a and b]. The following day the tray was removed and the impression recorded was processed in heat polymerized resin. Prior to polymerization of speech aid prosthesis, an index of the inferior (tongue) surface was made in polyvinyl siloxane (PVS) in putty consistency. The same was used to form the "lid" after hollowing the speech aid bulb.

After the completion of polymerization of the speech aid prosthesis, hollowing of the speech aid bulb was done, and the inferior (tongue) surface was formed in self-cure resin as a separate lid. Self-polymerizing resin was adapted in dough stage over the previously formed PVS index as a flat sheet of 2 mm. The region of resin in contact with the index helped to duplicate the tongue impression during swallowing. The resin lid formed was removed from the PVS index and seated on the hollowed out speech aid bulb. This was done as the size of the speech bulb was large. If the entire bulb had been fabricated in heat polymerized resin, there was a chance of increasing the weight of the prosthesis.<sup>[3-8]</sup>

The final speech aid prosthesis was inserted, and pressure spots were observed using a pressure indicating paste. The tongue



**Figure 2:** Molded tray in low fusing impression compound relined by tissue conditioner. Recorded anterior and posterior tonsillar pillars (red arrow) and the anterior tubercle of the atlas (yellow arrow) clasps (purple). (a) Superior view, (b) Lateral view

surface was made a concave, and the superior surface was made convex and smooth to deflect the secretions into the oral cavity [Figure 3a-c].

Speech therapy (two sessions per week, each session lasting for 2 h) was performed by a speech pathologist for 1 month. To correct hypernasality tactile feedback was taught to the patient. Improvement in the speech was noted after 1 month. Improvement of swallowing was also evident during the follow-up. The speech intelligibility score and hypernasality score attained after the prosthesis and speech therapy was 1 each.<sup>[4]</sup>

### Follow-up

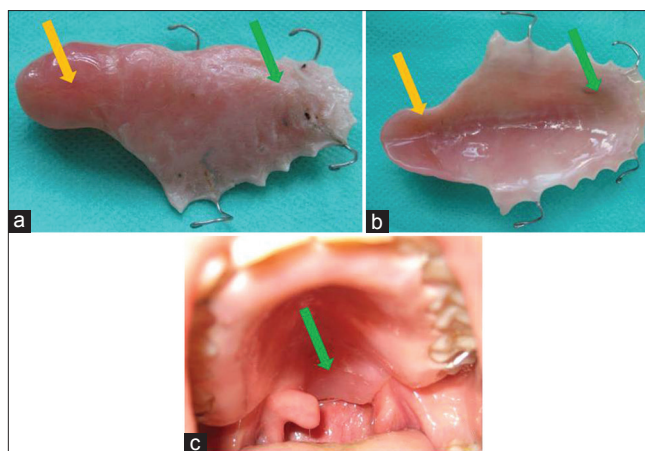
A follow-up of 9 months revealed improvement in speech [Video 3] and a better control in swallowing with no nasal regurgitation [Video 4]. An overall improvement in quality of life was evident with the patient showing a healthier state both physically (attributed to improved nutritional intake) and mentally (improved confidence). Continuous use of saliva substitute also showed a more lubricated oral cavity, facilitating easier deglutition.

### DISCUSSION

A simple and efficient method to fabricate speech aid prosthesis has been described which enabled the patient to lead a socially normal life. In the absence of any such rehabilitation, patient lacks the confidence to face the society and persists to live with the stigma of cancer.

The speech aid prosthesis serves the main function to control the air emission during speech and prevent the leakage of the material into the nasal passage during deglutition. However, improvement of speech is possible only when the prosthesis is used along with training from a speech pathologist. Moreover, an improvement can be noted by either using perceptual scales like temple street scale,<sup>[9]</sup> noting speech intelligibility changes or hypernasality changes<sup>[4]</sup> or more objective measurement tools like aerodynamic assessment.<sup>[10]</sup>

The authors emphasis the same must be practised in future in all such cases rehabilitated in order to motivate positively, the patient to continue wearing the appliance through feedback. This will also enable the operator to maintain a sound scientific data. Improvement in deglutition is possible by the patient's active participation in the treatment. Hence, rehabilitation of patients with velopharyngeal incompetence requires not just the



**Figure 3:** (a) Fabricated Prosthesis-intaglio surface (plate – green arrow), (speech aid extension – brown arrow). (b) Fabricated Prosthesis-polished surface (plate – green arrow), (speech aid extension – brown arrow). (c) Fabricated Prosthesis-intraoral view (green arrow)

fabrication of the prosthesis but a team of multidisciplinary experts for improvising the utilization of the prosthesis.

### REFERENCES

- Shetty NB, Shetty S, Nagraj E, D'Souza R, Shetty O. Management of velopharyngeal defects: A review. *J Clin Diagn Res* 2014;8:283-7.
- Agrawal KK, Singh BP, Chand P, Patel CB. Impact of delayed prosthetic treatment of velopharyngeal insufficiency on quality of life. *Indian J Dent Res* 2011;22:356-8.
- Fox A. Prosthetic correction of severe acquired cleft palate. *J Prosthet Dent* 1958;8:542.
- de Carvalho-Teles V, Pegoraro-Krook MI, Lauris JR. Speech evaluation with and without palatal obturator in patients submitted to maxillectomy. *J Appl Oral Sci* 2006;14:421-6.
- Nidiffer TJ, Shipman TH. Hollow bulb obturator for acquired palatal openings. *J Prosthet Dent* 1957;7:126.
- Buckner H. Construction of a denture with hollow obturator, lid, and soft acrylic lining. *J Prosthet Dent* 1974;31:95-9.
- Matalon V, LaFuente H. A simplified method for making a hollow obturator. *J Prosthet Dent* 1976;36:580-2.
- Schneider A. Method of fabricating a hollow obturator. *J Prosthet Dent* 1978;40:351.
- Shifman A, Finkelstein Y, Nachmani A, Ophir D. Speech-aid prostheses for neurogenic velopharyngeal incompetence. *J Prosthet Dent* 2000;83:99-106.
- Bispo NH, Whitaker ME, Aferri HC, Neves JD, Dutka Jde C, Pegoraro-Krook MI. Speech therapy for compensatory articulations and velopharyngeal function: A case report. *J Appl Oral Sci* 2011;19:679-84.

**How to cite this article:** Nanda A, Koli D, Sharma S, Suryavanshi S, Verma M. Alleviating speech and deglutition: Role of a prosthodontist in multidisciplinary management of velopharyngeal insufficiency. *J Indian Prosthodont Soc* 2015;15:281-3.

**Source of Support:** Nil, **Conflict of Interest:** None declared.