

## Narrow Ridge Management with Ridge Splitting with Piezotome for Implant Placement: Report of 2 Cases

Deepak Agrawal · Alka Sanjay Gupta ·  
Vilas Newaskar · Amit Gupta · Subhash Garg ·  
Deshraj Jain

Received: 13 July 2012 / Accepted: 11 November 2012 / Published online: 25 November 2012  
© Indian Prosthodontic Society 2012

**Abstract** Narrow dentoalveolar ridges remain a serious challenge for the successful placement of endosseous implants. Several techniques for this procedure may be considered, such as guided bone regeneration, bone block grafting, and ridge splitting for bone expansion. The ridge split procedure provides a quicker method wherein an atrophic ridge can be predictably expanded and grafted with bone allograft or autograft, eliminating the need for second surgical site. Traditionally, osseous surgery has been performed by either manual or motor-driven instruments. Piezosurgery is a relatively new technique for osteotomy and osteoplasty that utilizes ultrasonic vibration which allows clean cutting with precise incisions. This case series describes reports of 2 such cases in which narrow

mandibular ridge splitting was carried by mean of piezotome with immediate placement of implants in the osteotomy site. Five months later, the implants were uncovered followed by impression and restored with implant-supported porcelain-fused-to-metal crowns.

**Keywords** Implants · Narrow ridge · Ridge split · Piezotome

### Introduction

Dental implants have become an integral part of comprehensive management of dental patients. Successful implant therapy often requires sound osseous support. Scipioni et al. [1] suggests that wherever dental implants are placed, a minimum thickness of 1–1.5 mm of bone should remain on both buccal and lingual/palatal aspects of the implant(s) to ensure a successful outcome. For most standard implants, a minimum of 6 mm width is necessary for favourable outcome. A major limitation for successful implant placement remains the problem of inadequate ridge. Several methods have been described to augment the alveolar crest such as guided bone regeneration, bone block grafting, ridge splitting for bone expansion, and distraction osteogenesis.

Ridge splitting creates a sagittal osteotomy of the edentulous ridge using instruments such as chisels between the two cortical plates to expand the ridge width and consequently allow for the placement of implants. Ridge splitting approach has also been referred to as bone spreading, ridge expansion, lateral ridge expansion technique or the osteotome technique. Osborn [2] described this as ‘extension plasty’.

Several methods have been accomplished for the osteotomy procedure, manually with osteotomes or motor-driven engine. Recently Piezosurgery is being used for

---

D. Agrawal · V. Newaskar  
Department of Oral and Maxillofacial Surgery, Govt. College  
of Dentistry, Indore, Madhya Pradesh, India  
e-mail: fordeepak1@yahoo.co.in

V. Newaskar  
e-mail: vilasnewaskar@yahoo.com

A. S. Gupta (✉) · D. Jain  
Department of Prosthodontics, Govt. College of Dentistry,  
Indore, Madhya Pradesh, India  
e-mail: Dr.alka2000@gmail.com

D. Jain  
e-mail: drdeshrajain@rediffmail.com

A. Gupta  
Department of Orthodontics, Modern Dental College and  
Research Centre, Indore, Madhya Pradesh, India  
e-mail: amidont@yahoo.com

S. Garg  
Department of Periodontics, Govt. College of Dentistry, Indore,  
Madhya Pradesh, India  
e-mail: drsubhasgarg@rediffmail.com

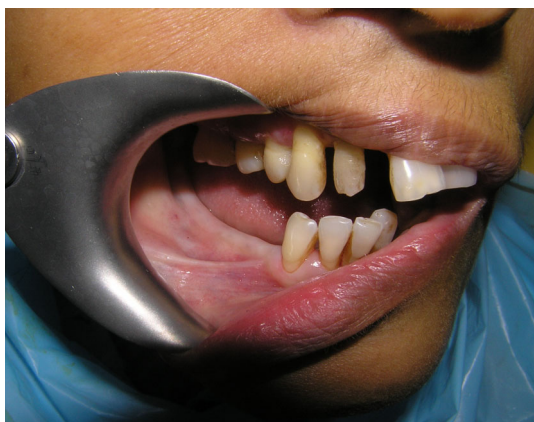osteotomy and osteoplasty that utilizes ultrasonic vibration. This article describes two such cases of narrow ridge managed with ridge splitting with the help of piezotome.

### Case I

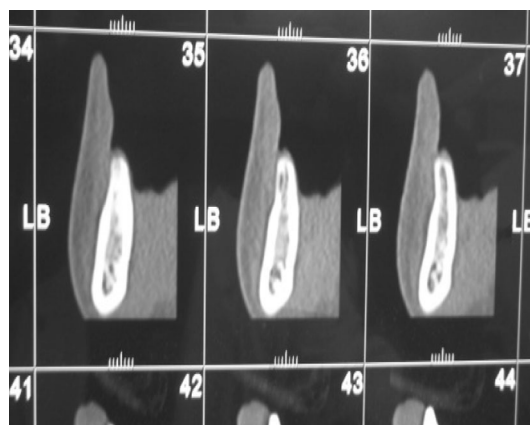
A 42-year-old woman without medical complications presented for the replacement of a missing mandibular right first, second premolar and first molar (Fig. 1). The teeth had been extracted 4 years before. Clinical examination revealed very thin ridge with adequate interarch space. The patient was keen for fixed partial prosthesis. So the patient was planned for placement of implant. A detail dentascan view revealed presence of pointed to 3 mm of ridge width at first premolar region, the proposed site for placement of implant (Fig. 2). Ridge expansion with ridge splitting technique was planned. The procedure was performed under local anaesthesia (Articane 2 %, epinephrine 1:100,000). A full thickness mucoperiosteal flap was raised from left canine region to first premolar region on right side. Osteotomy was performed with piezotome (Ultrasonic bone surgery unit, Resista Verbania, Italy) (Fig. 3). A midcrestal bone cut along with anterior releasing bony cut was performed (Fig. 4). The divided ridge was gradual expanded with increasing size of osteotomes. Implants of sizes  $4.2 \times 11.5$  mm,  $3.75 \times 10$  mm, and  $4.2 \times 10$  mm were respectively placed at #28, #29 and #30 region (Fig. 5). Autogenous bone harvested from symphysis region locoregionally was packed in the expanded crypt (Fig. 6). Rehabilitation with full composite splinted crowns was done after 5 months (Fig. 7, 8).

### Case II

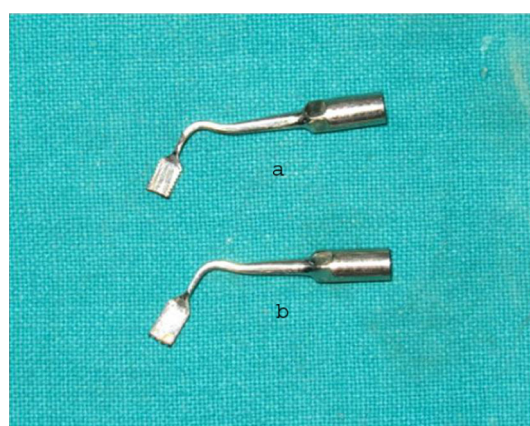
A 24 years young female approach for replacement of missing lower left second premolar and first molar. The



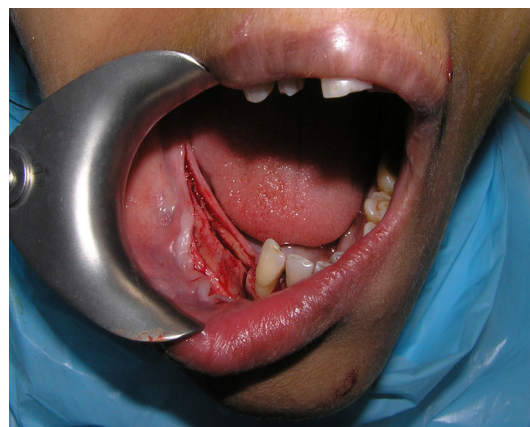**Fig. 1** Missing teeth distal to #27 with narrow ridge crest



**Fig. 2** Dentascan distal to #27 revealing ridge crest of 3 mm

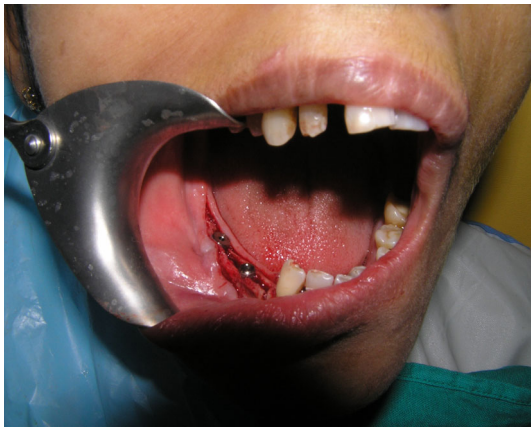

**Fig. 3** Piezotome tips used for osteotomy **a** side cutting, **b** end cutting

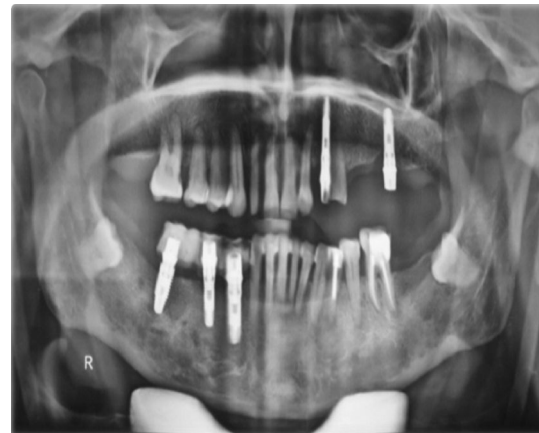

**Fig. 4** Midcrestal osteotomy with anterior releasing vertical bony cut

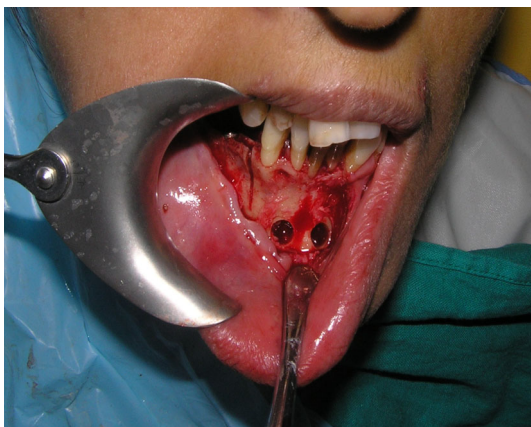teeth have been extracted 3 year ago for grossly carious non restorable reason. The patient has been planned for implant placement. Clinical examination revealed very thin ridge width with adequate bone height for implant



**Fig. 5** Implants placed in the splitted ridge in #28, #29 & #30 region



**Fig. 8** Post-op orthopantomogram showing stable implants in #28, #29 & #30 region with splinted crowns

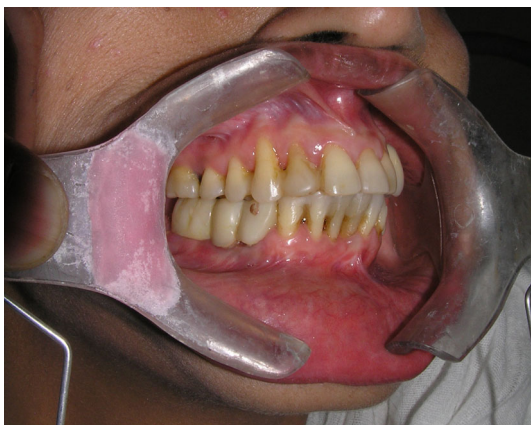

**Fig. 6** Autologous graft harvested from symphysis region

distal ends were performed with Piezotome (Fig. 9). Osteotomes of increasing width were used for further expansion of the splitted ridge. Implants of size 4.2 × 13 mm and 5 × 13 mm were placed in #20 and #19 region. The expanded crypt was packed with allograft Ossifi (Equinox) Biphasic hydroxyapatite beta tricalcium phosphate. After a healing period of 5 months the rehabilitation was done with porcelain fused to metal splinted bridge (Fig. 10).

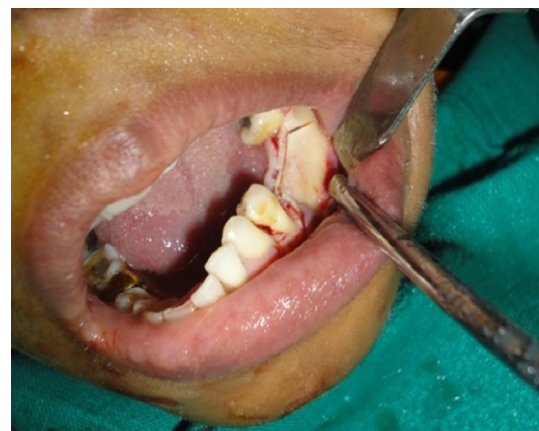**Discussion**

The ridge split procedure represents one form of augmentation technique for narrow ridges. The procedure can be considered for simultaneous placement of implants in addition to ridge expansion, thus reducing the overall time for implant therapy. Ridge splitting for root-form implant placement was developed in the 1970s by Dr. Hilt Tatum [3]. Tatum developed specific instruments including

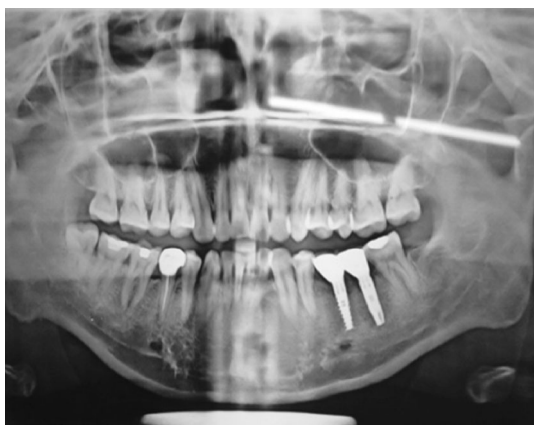

**Fig. 7** Implant retained composite splinted crown in #28, #29 & #30 region

placement. So ridge splitting was planned under local anaesthesia. A full thickness mucoperiosteal flap was elevated from first premolar to second molar. Midcrestal osteotomy along with vertical bony cuts on mesial and



**Fig. 9** Ridge splitting with midcrestal incision and mesial and distal vertical osteotomy cuts



**Fig. 10** Post-op orthopantomogram showing stable implanted with splinted PFM crowns n #19 & #20 region

tapered channel formers and D-shaped osteotomes to expand the resorbed residual ridge. Summers [4] later revived the interest in this technique; he reported that in 143 maxillary implants placed using the osteotome technique, only 5 failed (96 % implant survival). In 1992, Simion et al. [5] introduced a split-crest bone-manipulation technique by means of provoking a longitudinal greenstick fracture at the top of the bone that would split the atrophic crest in two parts. In 1994, Scipioni et al. [6] presented the clinical results of an edentulous ridge expansion technique. They placed 329 implants in 170 patients with success rate of 98.8 %. Sethi and Kaus [7] placed 449 implants in 150 patients in thin maxillary ridges of adequate height and comprising 2 separate cortical plates with intervening cancellous bone and observed them for a period of up to 93 months. A 97 % implant survival rate after a 5-year observation period was found.

Ridge split augmentation aims at the creation of a new implant bed by longitudinal osteotomy of the alveolar. To start, adequate bone height for implant placement should be present because the splitting of the crest will not increase bone volume vertically. A minimum of 3 mm of bone width, including at least 1 mm of cancellous bone, is desired to insert a chisel between cortical plates and consequently expand the cortical bones.

Ridge splitting is more applicable to the maxilla than the mandible. The thinner cortical plates and softer medullary bone make the maxillary ridge easier to expand.

Favorable conditions for the posterior mandible include a long edentulous span (missing molar and premolar teeth), abundant bone height superior to the mandibular canal (>12 mm), and the presence of some cancellous bone between the dense outer cortical plates. These considerations for ridge splitting were favourable for both of our cases.

Several authors have suggested the use of a partial thickness flap to help immobilize the displaced buccal

cortical plate. In cases where there is thin connective tissue, the partial-thickness flap procedure becomes extremely difficult, and the remaining tissue over the alveolar bone is too thin to protect the bone adequately. In the presented cases, the use of a full-thickness flap helped to avoid excessive bleeding, resulting in better visualization of the operating sites and better handling of the surgical steps.

Number of surgical techniques has been employed for ridge splitting. The initial osteotomy can be performed on midcrestal bone using a No. 15 blade or a carbide tungsten bur, Flat-end Fissure 701 (Brasseler USA, Savannah, GA, USA). Suh et al. [8] describe the microsaw technique which provides better control when preparing a cut along a narrow alveolar ridge and appears less traumatic to the bone. Additionally, less bone is lost because the microsaw creates much thinner cuts compared to conventional burs. In the present clinical report, a piezoelectric surgery system was used to create the vertical and horizontal corticotomies. Advantages of piezoelectric ultrasonic surgical instruments are

1. micrometric bone cut
2. selective cut
3. clear surgical field.

Microvibrations cut hard tissue with precision and accuracy. The Piezotome device operates with modulated ultrasound micromovements and with an oscillating frequency of 29 and 32 kHz, making it specifically suitable for osteotomies but not soft tissue cutting. The accidental slipping of the titanium tips onto surrounding soft tissue does not cause any injuries if only a very small degree of pressure is adopted, as recommended by the manufacturer. Unlike rotary bur, ultrasonic device can be used in ridge splitting of as narrow as 2 mm ridge without bony perforation. Thanks to cavitation effect of the sterile saline as coolant, maximum surgical visibility is allowed during osteotomy. Insignificant noise and vibrations compared to the ones by rotary bur or saw provide better comfort to patients.

The mid crestal osteotomy should come within to 2 mm of the adjacent teeth but not closer. Because of the thickness of the cortical bone in the mandible, one or two vertical osteotomy cuts are required, extending from the edges of the initial midcrestal osteotomy. Typically the length of the bony cut will be 3 mm shorter than the final length of the implant. The length of the osteotomy along the edentulous span should extend well beyond the planned implant sites. This extended length will allow the plates to expand or bow during preparation of the osteotomy and implant insertion (Case I).

Chisels or Osteotomes of increasing width and a mallet were used to further enlarge the osteotomy to a point 3 mm shorter than the final length of the implants to be placed.

The osteotomes are gently malleted to expand the bone. The force should be directed over the long axis of the osteotome, and periodic pauses allow the viscoelastic bone to adapt to the expansion. The osteotome should be rotated with a gentle pulling force to allow atraumatic removal of the instrument.

To prevent a fracture of the buccal plate during the expansion process, Suh et al. [8] recommended an additional apical osteotomy connecting the apical ends of the two “bony verticals” cuts in cases of more cortical mandibular bone. Enislidis et al. [9] and Elian et al. [10] recommended a staged approach to avoid postoperative complications from malfracture of the buccal segment in which midcrestal osteotomy was carried out in stage one followed by ridge expansion and implant placement in stage two.

The segmental ridge split procedure creates a crypt surrounded by bone and periosteum into which implants and bone graft material can be introduced with reasonable confidence that new bone can be constructed and this new bone will produce a solid bone for dental implants. Different combinations of autogenous and alloplastic graft materials have been employed. The site is then covered with a bioresorbable membrane. Scipioni et al. [11] have found that a bone graft is usually unnecessary. In general, interpositional grafts have an improved prognosis because they have an enhanced vascular bed in an osteogenic environment and are protected from masticatory function. In our study, in case I, autogenous bone harvested from symphysis region have been employed while in case II allograft Ossifi (Equinox) Biphasic hydroxyapatite beta tricalcium phosphate molecule have been used as interpositional material.

Wound healing in these cases is similar to the fracture repair of bone. The gap fills with a blood clot that organizes and is replaced with woven bone. This immature osseous tissue develops into load-bearing lamellar bone at the implant interface.

In the present clinical study, we used a tapered screw type implant to increase the initial stability and prevent buccal bone segment fracture. Brunski [12] reported that screw-shaped implants provided the strongest retention immediately after implant placement. Kan et al. [13] reported a notably greater implant survival rate for threaded implants (titanium 94.9 %; HA-coated 96.0 %) than for nonthreaded implants (HA-coated 75.4 %).

Second-stage surgery was performed 5 months later, healing abutments were placed, and the soft tissue were allowed to heal for an additional 2 weeks. Full composite splinted crowns (Fig. 8) and splinted porcelain-fused-to-metal (PFM) crowns (Fig. 10) supported by abutments then were delivered in case I and case II respectively. Thus, the overall treatment time has been shorten since this procedure allowed simultaneous placement of implants. Contrary, onlay bone grafting procedures require second

surgical site, which typically exhibit post-operative morbidity associated with bone harvesting. Additionally, onlay bone graft require a healing period of 6 months to a year before dental implants can be placed, and the onlay graft sometimes fails to fuse to the augmented site.

The disadvantage of ridge splitting is that if complications arise and bone loss occurs, then the patient is usually left with an even greater bone defect than before treatment. Mitigating factors that may produce less favourable results in ridge splitting include infections, implant loosening, sloughing of the implant edges, and loss of graft material.

## Conclusion

When judiciously used ridge splitting is helpful technique in managing narrow ridges. Since this approach allows simultaneous placement of implants, shortening the overall treatment time. The implementation of newer cutting tool Piezotome allows precise osteotomy.

## References

- Scipioni A, Bruschi GB, Calesini G (1994) The edentulous ridge expansion technique: a five-year study. *Int J Periodontics Restorative Dent* 14(5):451–459
- Osborn JF (1985) Die alveolar-expansions-plastik. *Quintessenz* 39:9–14
- Tatum H (1986) Maxillary and sinus implant reconstructions. *Dent Clin N Am* 30:207–229
- Summers RB (1994) A new concept in maxillary implant surgery: the osteotome technique. *Compend Contin Educ Dent* 15:152–160
- Simion M, Saldoni M, Zaffe D (1992) Jawbone enlargement using immediate implant placement associated with a split crest technique and guided tissue regeneration. *Int J Periodontics Restorative Dent* 2:462
- Scipioni A, Bruschi GB, Calesini G (1994) The edentulous ridge expansion technique: a five-year study. *Int J Periodontics Restorative Dent* 14:451
- Sethi A, Kaus T (2000) Maxillary ridge expansion with simultaneous implant placement: 5-Year results of an ongoing clinical study. *Int J Oral Maxillofac Implants* 15:491
- Suh JJ, Shelemay A, Choi SH, Chai JK (2005) Alveolar ridge splitting: a new microsaw technique. *Int J Periodontics Restorative Dent* 25(2):165–171
- Enislidis G, Wittwer G, Ewers R (2006) Preliminary report on a staged ridge splitting technique for implant placement in the mandible: a technical note. *Int J Oral Maxillofac Implants* 21:445
- Elian N, Jalbout Z, Ehrlich B et al (2008) A two-stage full-arch ridge expansion technique: review of the literature and clinical guidelines. *Implant Dent* 17:16
- Scipioni A, Bruschi GB, Giargia M et al (1997) Healing at implants with and without primary bone contact. *Clin Oral Implants Res* 8:39 (14:451, 1994)
- Brunski JB (1992) Biomechanical factors affecting the bone-implant interface. *Clin Mater* 10:153
- Kan JY, Rungcharassaeng K, Kim J et al (2002) Factors affecting the survival of implants placed in grafted maxillary sinuses: a clinical report. *J Prosthet Dent* 87:485