

Aesthetic and Functional Rehabilitation of a Case of Mutilated Dentition and Loss of Vertical Dimensions

Parag Dua · J. P. Singh · Anu Aghi

Received: 2 October 2010 / Accepted: 21 July 2011 / Published online: 12 August 2011
© Indian Prosthodontic Society 2011

Abstract Cases of severe attrition are a common finding in daily clinical practice. Attrition leads to loss of vertical dimension, chewing inefficiency and poor esthetics. These cases require complete oral rehabilitation which can be successfully achieved by a systematic approach integrating various concepts of prosthodontics. The primary aim of such complex treatment modalities is to regain the lost function, esthetics, comfort and confidence for the patient. The following case report describes the complete oral rehabilitation of a patient diagnosed of mutilated dentition and reduced vertical dimensions due to severe attrition. A detailed treatment plan was chalked out which included

institution of proper oral hygiene measures, extraction of teeth with poor prognosis, restoration of carious teeth, endodontic treatment for carious teeth with periapical involvement. This was followed by foundation restorations of teeth that were crucial for the final prostheses. Patient was given transitional restorations for about 6 weeks with the aim of regaining the lost vertical dimensions. Final rehabilitation was done by fixed dental prostheses.

Keywords Attrition · Full mouth rehabilitation · Mutilated dentition · Reduced vertical dimensions

The case report was presented at '37th Indian Prosthodontic Society Conference—Thrissur' in the faculty session and was awarded the 'best faculty paper' award.

P. Dua · J. P. Singh
Department of Dental Surgery, Division of Prosthodontics,
Armed Forces Medical College, Pune 411040, Maharashtra,
India

Present Address:
P. Dua (✉)
357 Field Hospital, Manipur, C/0 99 A.P.O., India
e-mail: duaparag@gmail.com

Present Address:
J. P. Singh
Command Military Dental Centre (Southern Command),
Pune 411040, Maharashtra, India

A. Aghi
Military Dental Centre, Bombay Engineering Group,
3, East Kirkee, Pune, India

Present Address:
A. Aghi
2016 Field Hospital, Pathankot, C/0 99 A.P.O., India

Introduction

Full mouth rehabilitation employs all diagnostic, therapeutic and restorative procedures for the replacement of lost oral structures. The reasons for the loss of oral tissues could be one too many. A common complaint of geriatric patients is attrition of teeth which causes difficulty in mastication and depressed facial appearance. Severe attrition leads to reduced vertical dimension of occlusion, loss of teeth and other potential problems related to unfavorable neuromuscular coordination of the stomatognathic system. Understanding vertical dimension and how and when it should be altered is a situation commonly faced by the clinician. It involves a number of prosthodontic considerations such as analysis of the existing occlusion and occlusal plane; availability of freeway space; size and location of edentulous areas; number, position and condition of the teeth in each arch; the need for altering the vertical dimensions and restoration of function and esthetics.

This clinical report describes the esthetic and functional rehabilitation of a patient with severe attrition. Complete

oral rehabilitation was successfully done by integrating the concepts of fixed prosthodontics.

Case Report

Chief Complaint

A 61-year-old male patient presented to the dental centre with the chief complaints of attrition, difficulty in chewing and a depressed facial look due to mutilated teeth.

Case History

The patient gave a history of gradual wearing away of teeth over almost a decade. During last couple of years he had to undergo extraction of upper right side premolar and molar and lower left side molar due to attrition and carious fracturing. There was no history of loosening of teeth or any other periodontium related problem that might be indicative of a periodontal pathology. The upper front teeth had undergone gradual attrition and fractured over a period of time. This had caused deterioration of the patient's facial appearance making his jaw to overclose in the anterior region. Patient also complained of increased sensitivity in his back teeth due to enamel wear. He had been rehabilitated with an acrylic partial denture 1 year back but could not adjust to it and therefore stopped wearing it. Patient had, since then, been without any prosthesis. Patient had also undergone root canal treatment of his upper left incisor 1 year back as the tooth had got infected due to caries and fractured.

Extra-oral examination revealed an obvious overclosure from the frontal aspect indicative of reduced vertical dimensions. Intra-oral examination (Figs. 1, 2, 3, 4) revealed missing maxillary right second premolar, first and third molars and mandibular left first molar. Maxillary anterior teeth had undergone severe attrition. Maxillary right central and lateral incisors and left central incisor had practically fractured and were reduced to root stumps. The

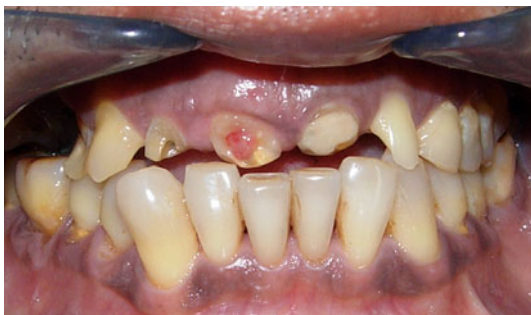

Fig. 1 Pre-op labial view

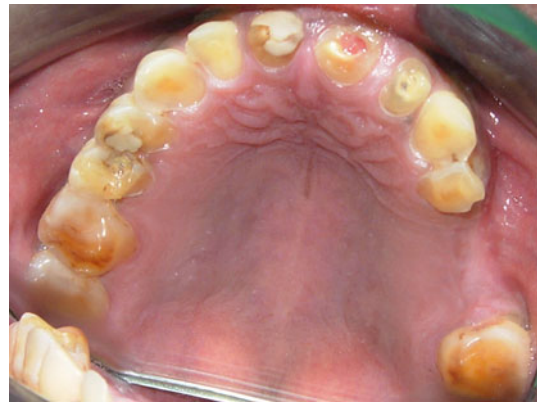

Fig. 2 Pre-op intraoral view of maxillary teeth

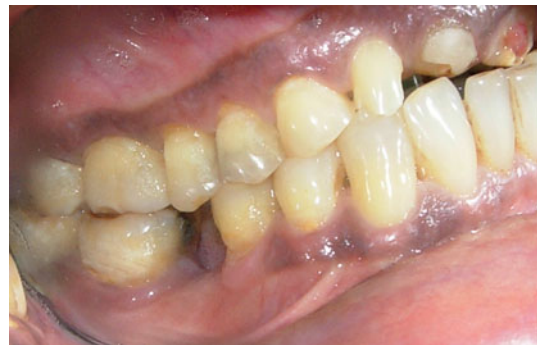

Fig. 3 Pre-op intraoral view (left side)

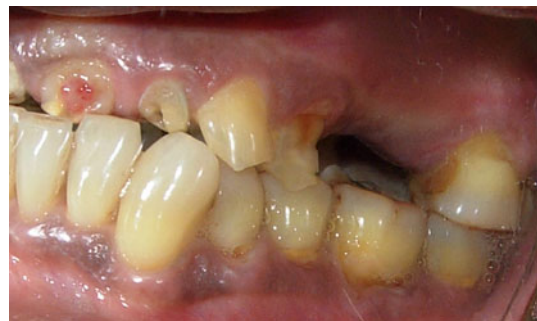

Fig. 4 Pre-op intraoral view (right side)

root stump of maxillary right central incisor showed a pulp polyp and was severely tender. Maxillary left central incisor had been root canal treated and showed a large glass ionomer cement restoration. The lack of opposition from maxillary anterior teeth had caused mild supraeruption of mandibular anterior teeth. Maxillary right first premolar showed excessive cervical abrasion and attrition of palatal surface. Mandibular left second molar had a large mesio-occlusal amalgam restoration which showed marginal ditching. There was mesial drifting of mandibular left second molar and distal drifting of mandibular left second premolar due to missing first molar. Mandibular right first

molar was highly tender to percussion. It had a large silver amalgam restoration and was supraerupted due to missing opposite molar. Mandibular right second molar also had mesio-occlusal caries. There was attrition on the occlusal surfaces of all posterior teeth. Maxillary right central and lateral incisors and mandibular right first molar were indicated for extraction due to periapical infection not responding to endodontic treatment.

Diagnosis

“Mutilated dentition with reduced vertical dimensions due to severe attrition.”

Treatment Objectives and Treatment Plan

The problem areas were identified and the following treatment objectives were outlined:

1. Conservation of remaining teeth by reinforcing them with foundation restorations.
2. Regaining the lost vertical dimensions.
3. Restoration of proper occlusion, esthetics and function by integrating sound concepts of fixed prosthodontics.

An integrated approach was planned comprising of the following phases:

1. Preliminary phase: extraction of teeth with poor prognosis.
2. Diagnostic phase: diagnostic mounting on a semi-adjustable articulator and wax mock-up.
3. Periodontal phase: institution of immaculate oral hygiene measures coupled with periodic recall and review.
4. Restorative phase: restoration of carious teeth, endodontic treatment of teeth with periapical infection.
5. Endodontic and prosthodontic phases: endodontic treatment wherever indicated; fabrication of foundation restorations for crucial abutments; fabrication of interim prosthetic restorations for a transitional phase to regain vertical dimensions; fabrication of fixed dental prostheses on a semi-adjustable articulator.

Treatment Procedures

In the preliminary phase the maxillary right central and lateral incisors and left second premolar and mandibular right first molar were extracted due to non-resolving periapical infection. Diagnostic casts were fabricated and mounted on a semi-adjustable articulator. A diagnostic wax up was done to analyze the need of altering the vertical dimension of occlusion, occlusal plane, tooth contours,

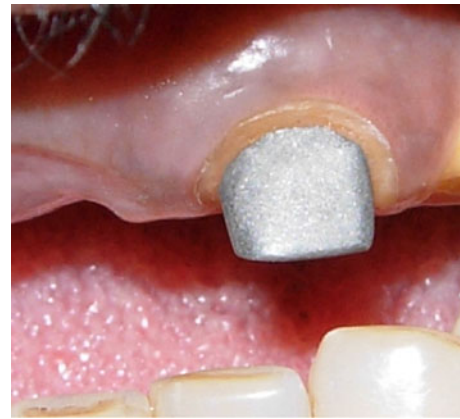

Fig. 5 Custom cast post and core (maxillary left central incisor)

position and esthetics. This helped in an approximate visualization of the final prosthetic restoration. Clinical analysis showed a freeway space of 4 mm. Therefore, a 2.5 mm increase of vertical dimension was planned. In the periodontal phase thorough supra and subgingival scaling was carried out and immaculate oral hygiene maintenance measures were instituted to obtain an excellent oral hygiene and health of remaining crucial teeth meant to serve as crucial abutments for the final prostheses. Endodontic treatment was carried out for the crucial abutments. A custom cast post and core was fabricated for maxillary left central incisor (Fig. 5). Prefabricated screw post was placed in maxillary left first premolar followed by core fabrication with light cure composite core build up material. Mandibular left and right second molars, which had large ditched amalgam restorations, were endodontically treated and restored with core build up restorative material.

Prosthodontic Phase

Crown preparations were carried out as per the treatment plan. Interim prostheses were fabricated and inserted (Fig. 6). These were fabricated at an increased vertical

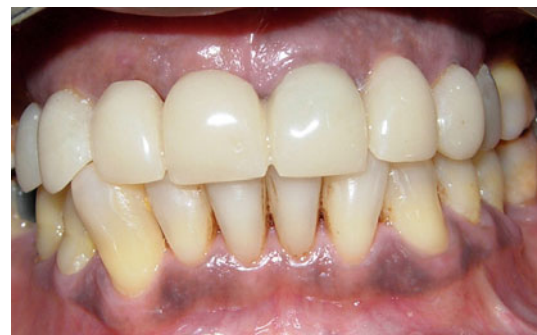

Fig. 6 Provisional restorations




Fig. 7 Face bow transfer to Hanau H2 Semi adjustable articulator

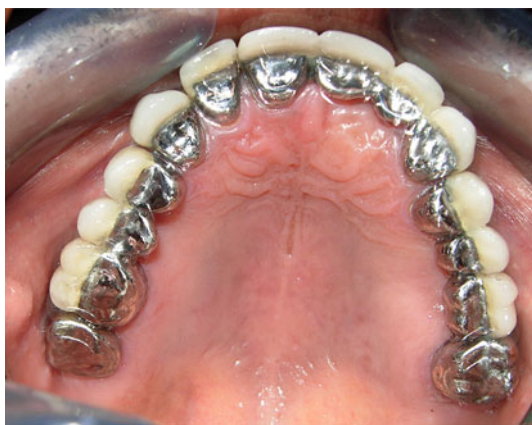

Fig. 8 Post-insertion maxillary view

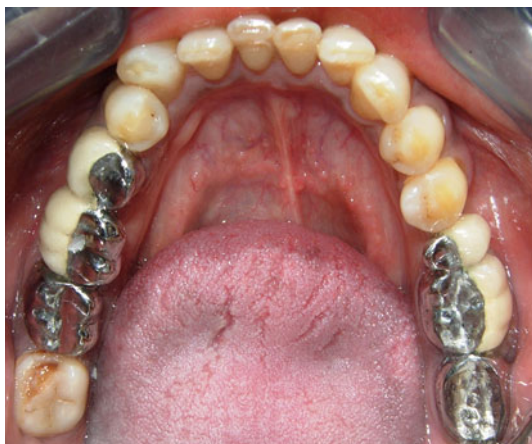

Fig. 9 Post-insertion mandibular view

dimension of approximately 2.5 mm as planned. The patient was kept on an interim phase of about 6 weeks with regular review to check for any subjective symptoms of TMJ discomfort. Patient's esthetics and phonetics were checked and found appropriate. The final prosthetic phase commenced after 6 weeks. Elastomeric impressions

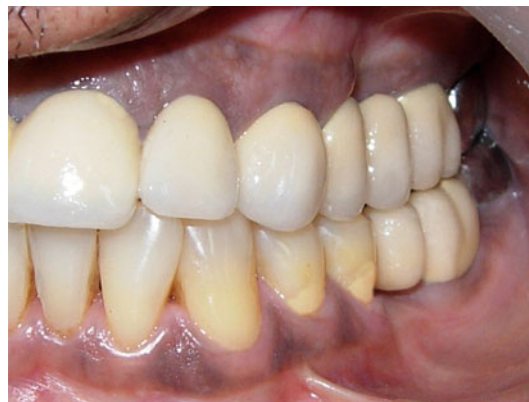

Fig. 10 Post-op intraoral view (*left side*)

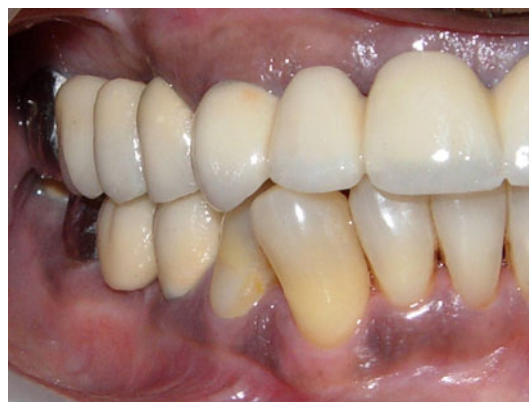

Fig. 11 Post-op intraoral view (*right side*)

(ESPE-3 M addition poly-silicon) were made and multiple dies fabricated. Orientation relation was recorded and transferred to a semi-adjustable articulator (Hanau-H2) with the help of a spring face bow transfer (Fig. 7). Mounting of casts was done followed by protrusive and lateral records. To regain the vertical dimension of occlusion the incisal pin was dropped by 2.5 mm, as planned, and wax patterns fabricated accordingly. A canine protected occlusion was incorporated. The metal used for fabrication for copings was Bellabond Plus (company—Bego Bremer) with Belasum investment material and Begosol investment liquid. Copings were tried intraorally. The final restorations were cemented with luting glass ionomer cement. The patient was educated about the maintenance of oral hygiene (Figs. 8, 9, 10, 11, 12).

Discussion

The employment of all the diagnostic, therapeutic and restorative procedures available for the treatment and prevention of dental diseases is referred to as 'Full Mouth Rehabilitation' [1]. The primary aim of the process of mouth




Fig. 12 A satisfied patient

rehabilitation is to restore the functional and structural integrity of dental arches by using inlays, onlays, crowns, bridges, implant supported prostheses and partial dentures. The objective of utilizing all the available treatment modalities is to provide an appropriate occlusion that optimizes function, esthetics and comfort of the patient. Some of the complex, yet common clinical situations that require full mouth rehabilitation are: severe attrition; poorly fabricated fixed partial dentures; developmental anomalies; skeletal dentofacial deformities such as severe class II or class III and multiple fractured or missing teeth. For complex cases involving esthetic and functional rehabilitation, the clinician must plan the treatment diligently, taking into account the need of altering the vertical dimensions and the type of occlusal scheme to be incorporated.

Meticulous ‘Diagnosis and Treatment Planning’

For treating severe attrition Morales WC and Mohl ND [2] laid down certain basic guidelines such as: (i) Comprehensive orofacial and dental examination and history, TMJ screening. (ii) Diagnostic mounting, wax mock-up and diagnostic occlusal adjustment on the mounted casts. (iii) Careful planning for need of preliminary treatment. (iv) Patient education about treatment alternatives and modalities and prognosis of the treatment. (v) Careful execution of the treatment plan. These guidelines provide a clear path for the clinician to follow during the planning stages of treatment and maximize the chances of a successful outcome.

Alteration of Vertical Dimensions in Complex Prosthetic Reconstructions

Schweitzer JM [3] emphasized that the reconstructive procedures employed must be within the tolerable limits of

TMJ, neuromuscular complex, and the periodontium. The need for altering vertical dimensions is imminent for rehabilitating complex clinical situations such as attrition or multiple missing teeth. Brown KE [4] outlined a clinical approach based on the need for an increase in the occlusal vertical dimension prior to the definitive treatment. He suggested a sequential approach towards fixed reconstruction which avoids inaccuracies of multiabutment registration and orientation associated with complete arch preparation.

According to Morales WC and Mohl ND [5] the health of the masticatory system is intimately related to the occlusal vertical dimension. Any radical alteration of the vertical dimension of occlusion is potentially harmful to the masticatory system with reduced tolerance to such procedures. Carlsson et al. [6] and Christensen [7] documented symptoms such as soreness and fatigue of masticatory muscles due to increased vertical dimension of occlusion. It is advisable to provide the patient an interim prosthesis in the form of a partial denture or provisional restorations for the transitory phase especially in situations requiring alteration of vertical dimension of occlusion. Increased vertical dimension also effects the phonetics (especially the pronunciation of ‘S’ sound). This can be checked with the provisional restorations by shortening the mandibular incisors if they are involved in the final restoration. Adjustment of maxillary incisors should be kept to minimum due to esthetic implications and patient should be given some time for adaptation.

Techniques of ‘Occlusal Rehabilitation’

Different techniques of occlusal rehabilitation have been suggested by authors [8]. These techniques have their own merits and de-merits and their use varies depending on the existing clinical situation. In the ‘Quadrant arch technique’, one quadrant is treated at a time. This technique has the advantage that the vertical dimensions can be maintained and lengthy appointments are avoided. The ‘Simultaneous arch’ technique involves the reconstruction of maxillary and mandibular arches. In this technique, occlusion and esthetics achieved are better and number of appointments is reduced. The ‘Segmented simultaneous arch’ technique enjoys the merits of ‘Quadrant arch’ as well as ‘Simultaneous arch’ techniques.

‘Success and Longevity of Fixed Prosthesis’

Multiple fixed prostheses also enhance the chances of failure. Bell AM et al. [9] emphasized how these failures could be avoided. There are numerous factors that affect esthetic appearance and the longevity of these restorations such as a good crown preparation, accurate elastomeric impressions, proper selection of alloy and porcelain for

ceramometal or all ceramic restoration. The most important consideration in a ceramic restoration is the correct anatomy, placement, and harmonious blending with the oral and facial features of the patient. The distortion of porcelain during firing cycles also affects the durability and esthetics of the final restoration. Hobo [10] investigated the amount of vertical height distortion of porcelain cusps and fossae during glazing and concluded that the distortion can be minimized to an acceptable level. He said that: (i) Vertical height loss can be minimized by using opaque cones to support cuspal porcelain; (ii) The vertical distortion is less after the second glaze than the first. (iii) Adjustment of the occlusal surface after the first glaze followed by re-glazing minimizes distortion.

Conclusion

The primary objective of full mouth rehabilitation is preservation of health, restoring function and achieving esthetics and patient comfort. The concept of ‘preservation’ has further accentuated the need for complete oral rehabilitation. Successful rehabilitation of patients presenting with severe attrition requires meticulous and sequential treatment planning. The TMJ is a very delicate and complex structure. Any stress on the TMJ due to injudicious alteration of vertical dimensions will lead to a chronic and degenerative disease. Therefore, the clinician must have an in depth understanding of the affect of these procedures on the TMJ and masticatory system. Patient’s insistence for

esthetics leads the clinician to “bite raising”. There is no doubt that clinician should strive to obtain the best esthetic result, however, as in all human behaviors, moderation is the fundamental commandment for clinical success.

Conflict of interest None.

References

1. Landa JS (1955) An analysis of current practices in mouth rehabilitation. *J Prosthet Dent* 5:527–537
2. Morales WC, Mohl ND (1992) Restoration of the vertical dimension of occlusion in the severely worn dentition. *Dent Clin North Am* 36(3):651–664
3. Schweitzer JM (1981) An evaluation of 50 years of reconstructive dentistry. Part I: jaw relations and occlusion. *J Prosthet Dent* 45:383–388
4. Brown KE (1980) Reconstruction considerations for severe dental attrition. *J Prosthet Dent* 44:384–388
5. Morales WC, Mohl ND (1991) Relationship of occlusal vertical dimension to the health of the masticatory system. *J Prosthet Dent* 65:547
6. Carlsson GE, Ingerwal B, Kocak G (1979) Effect of increasing vertical dimension on the masticatory system in subjects with natural teeth. *J Prosthet Dent* 41:284–289
7. Christensen J (1970) Effects of occlusion raising procedures on the chewing system. *Dent Pract* 20:33–38
8. Binkley TK, Binkley CJ (1987) A practical approach to full mouth rehabilitation. *J Prosthet Dent* 57:261–266
9. Bell AM, Kurzeja R, Gamberg MG (1985) Ceramometal, crowns, bridges. Focus on failures. *Dent Clin North Am* 29(4):763–778
10. Hobo S (1982) Distortion of occlusal porcelain during glazing. *J Prosthet Dent* 47:154–156