

## Aesthetic Finger Prosthesis

N. Shanmuganathan · M. Uma Maheswari ·  
V. Anandkumar · T. V. Padmanabhan ·  
Shailee Swarup · Ahmed Hasan Jibrán

Received: 9 November 2010 / Accepted: 22 May 2011 / Published online: 21 June 2011  
© Indian Prosthodontic Society 2011

**Abstract** Complete or partial fingers are the most commonly encountered forms of partial hand losses. Though finger amputations are commonly due to traumatic injuries, digit loss may also be attributed to congenital malformations and disease. Irrespective of the etiology, the loss of a finger has a considerable functional and psychological impact on an individual. In order to alleviate these problems, partial or complete finger prosthesis may be fabricated. This clinical report portrays a method to fabricate silicone rubber prosthesis for a patient who has a partial finger loss caused due to trauma.

**Keywords** Amputated digit · Amputated finger · Amputee · Prosthetic finger · Silicon finger

### Introduction

A finger is a type of digit, an organ of manipulation and sensation found in the hands of humans and other primates. Normally humans have five digits, termed phalanges, on each hand. They enable us to interact with our environment and help in many day to day functions. It has been stated that the thumb is the most important digit from a functional standpoint [1].

“Amputation”, derived from the Latin word “amputare” (to excise, to cut out) has been defined as the “removal of part or all of a body part enclosed by skin”

(Online Medical Dictionary). Until the eighteenth century, with the exception of Pare, few physicians gave thought to the condition of the amputation stump for prosthetic appliance during the period 1846–1847. The introduction of antiseptics by Lister allowed surgeons to take more time to produce viable amputation stump capable of supporting prosthetics [2].

There are various types of amputations some of which are self-amputation, which occurs when a trapped person frees himself or herself by removing part or all of a body part, congenital amputation, which occurs when a person is born without part or all of a body part and traumatic amputation which may result from a factory, farm, powered tools or motor vehicle accidents, including industrial or environmental accidents, terrorist attacks, and lack of basic public health which often lead to diabetes, gangrene and/or infection. Whatever the indication of an amputation, the result is a limb stump [3].

Finger and partial finger amputations are some of the most frequently encountered forms of partial hand losses [4]. The most suitable treatment depends on the sort of injury and the involvement of other digits. Numerous techniques are available to restore fingertip amputations, with the common goal to reduce pain and preserve sensation at the tip [5]. The most suitable approach depends on the amount of tissue involved, the involvement of bone (distal phalanx), the angles and levels of amputation, and the involvement of other fingers.

The complete or partial loss of a finger results in significant functional deficiencies. In addition to immediate loss of grasp, strength and security, the absence of a finger may cause marked psychological trauma. Beasley has noted that individuals who keep their hands hidden inside pockets due to embarrassment over appearance are as functionally disabled as a forequarter (scapulothoracic) amputee [6].

N. Shanmuganathan (✉) · M. U. Maheswari · V. Anandkumar · T. V. Padmanabhan · S. Swarup · A. H. Jibrán  
Department of Prosthodontics, Faculty of Dental Sciences,  
Sri Ramachandra University, Porur, Chennai 600116, Tamil  
Nadu, India  
e-mail: shansdr@yahoo.co.in

Before the management of an amputee, the functional requirements of the individual and management options must be discussed with the patient. A complete hand examination should be performed, estimating the amount of injury to the fingertip, angles and levels of amputation, loss of tissue, involvement of nail, involvement of other fingers, neurovascular involvement, and function of the hand. After assessing the fingertip injury, a treatment plan should be formulated. Management starts with history elicited from the patient regarding the nature of the injury, age, hand dominance, occupation, recreational activities (including playing sports and musical instruments), previous history of hand injuries or problems, and other systemic diseases that affect wound healing. If more than one option is available, the potential benefits and risks of each option should be discussed with the patient before the final treatment is selected [5].

A prosthesis can often restore a near normal function in distal phalange amputations [7]. Individuals who desire for finger replacement usually have high expectations for the appearance of the prosthesis [8]. Various methods like titanium implants, osseointegration abutment, silicone elastomers are in use for replacing missing finger. Passing through various materials, the acceptance rate has been much higher when an individually sculpted custom restoration using silicone elastomer [8].

### Case Report

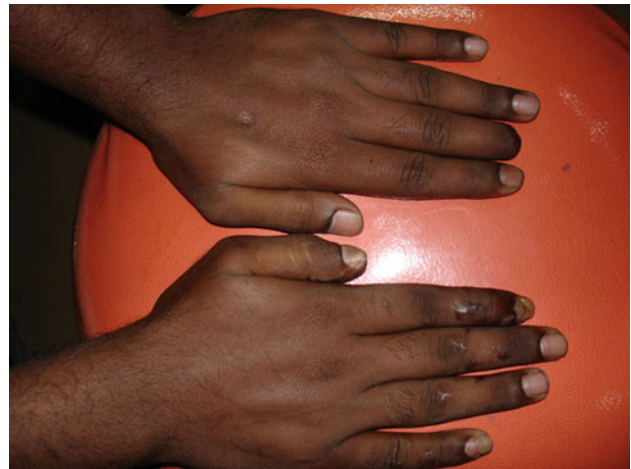A 25 years old male patient reported to the Department of Prosthodontics and Maxillofacial Prosthetics, Faculty of Dental Sciences, Sri Ramachandra University, Chennai with the complaint of a partially missing finger. The patient revealed a history of having lost the digit in a traumatic injury caused by a mechanical lathe.

A complete hand examination was carried out that revealed a residual stump; dark brown in colour on the middle finger of the left hand measuring 3 cm in height. The area around the residual stump was found to be clear of any signs of inflammation (Fig. 1).

The case was discussed and a method to replace the finger was formulated. The treatment plan was then discussed with the patient. As a part of protocol, and to ensure the patient's willingness and co-operation, an informed consent was signed before beginning the treatment.

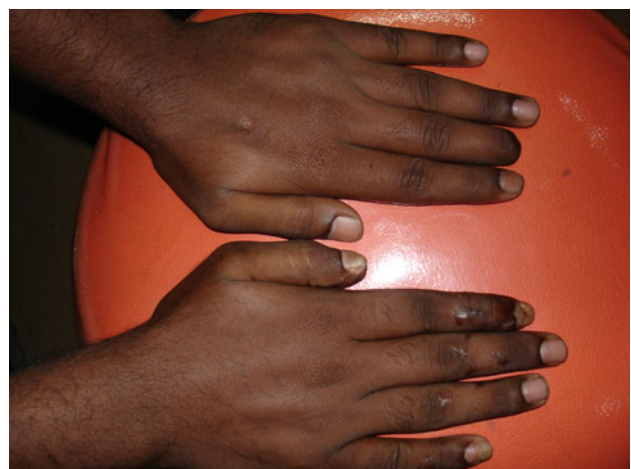
### Fabrication

The fabrication of the prosthesis consisted of the fabrication of a sleeve, the wax pattern followed by laboratory procedures to fabricate it into silicone rubber prosthesis.



**Fig. 1** Examination

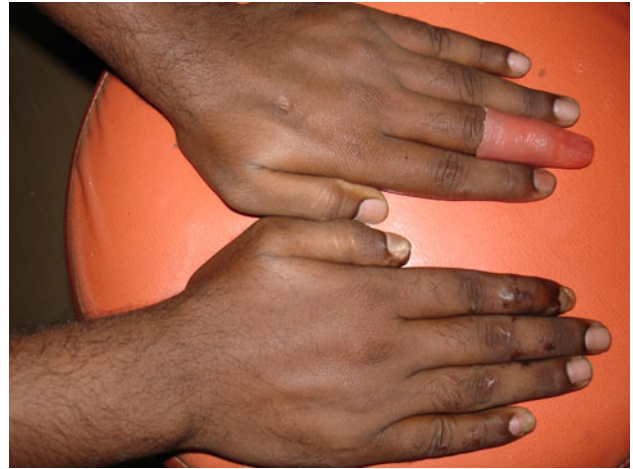
1. The middle finger of the patient's left hand was lubricated with a thin layer of petroleum jelly, to prevent the hydrocolloid impression material from adhering to it (Fig. 2). The amputated finger was then duplicated in a hydrocolloid impression material and replicated in dental stone material.
2. The middle finger model is then reduced by trimming with a bur. This is best achieved by following the margin line of the prosthesis and cutting to the depth of a 2 mm rose head steel bur. This means that the undersize sleeve when placed in position on the tissue of the residual stump will create a passive vacuum fit.
3. Sufficient silicone (M511 Cosmesil maxillofacial rubber, UK) was mixed and placed in a vacuum bell chamber for 10 min to remove excess air. The model was dipped, and the excess silicone was allowed to drain away (Fig. 3). Alternatively, the mix may be spatulated over the entire surface of the prosthesis contact area of the model. The model was then placed



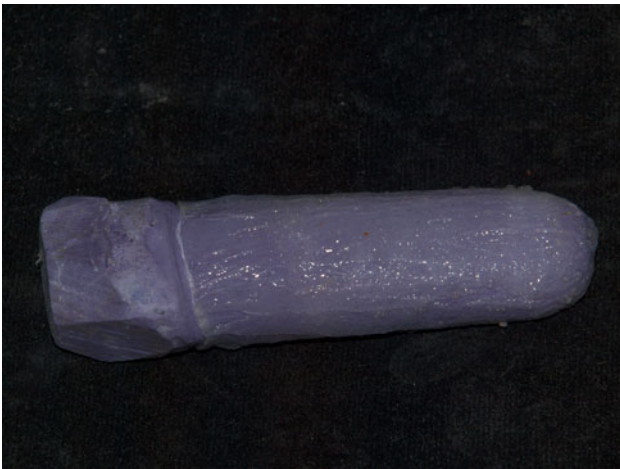**Fig. 2** Application of petroleum jelly



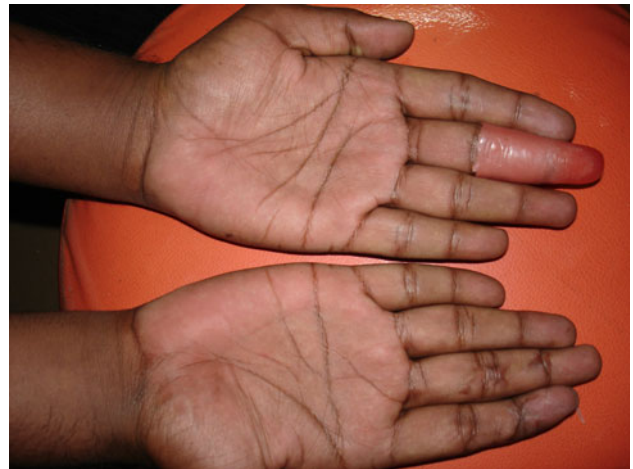**Fig. 3** Model dipped in silicone



**Fig. 5** Wax pattern-dorsal



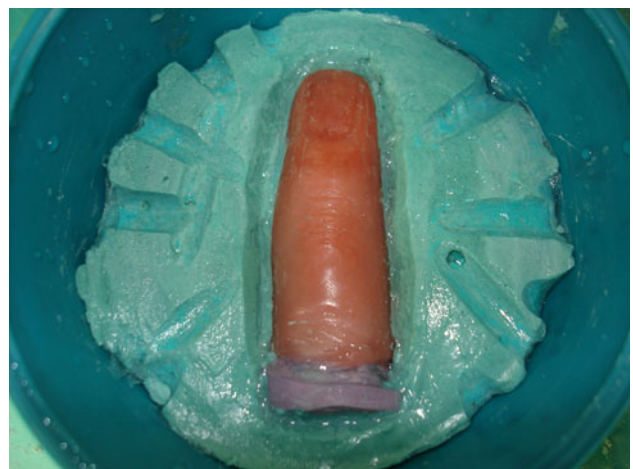**Fig. 4** Silicone sleeve



**Fig. 6** Wax pattern-ventral

in a preheated oven at 85°C for 15 min. The sleeve should be periodically checked for any bubbles trapped in the silicone that can be released with a metal wire probe. Once cured, if necessary a further coat of silicone may be applied (Fig. 4). The sleeve was tried and checked for a firm fit.

4. On the same visit a hydrocolloid impression of the middle finger of the right hand was made. Modelling wax (Hindustan Modelling Wax, India) was poured into this impression and allowed to cool until it solid. The wax pattern was modified and tried on the patients finger stump and checked for the measurements on both the dorsal and ventral aspects of both the middle fingers (Figs. 5, 6, 7). Provision for the finger nail was made on the wax pattern that was bonded to the final prosthesis.

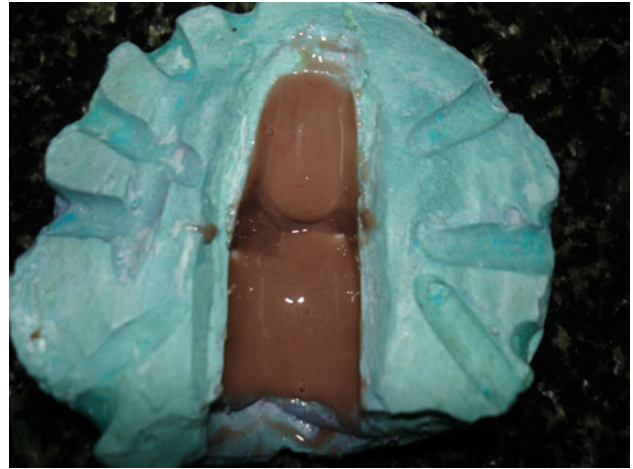

**Fig. 7** Wax pattern with nail bed flaked

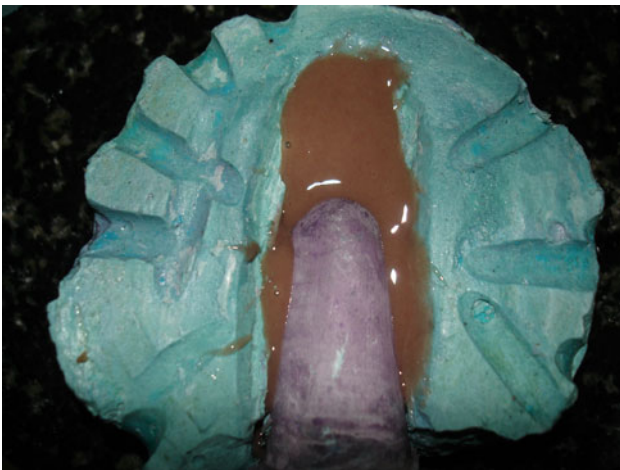



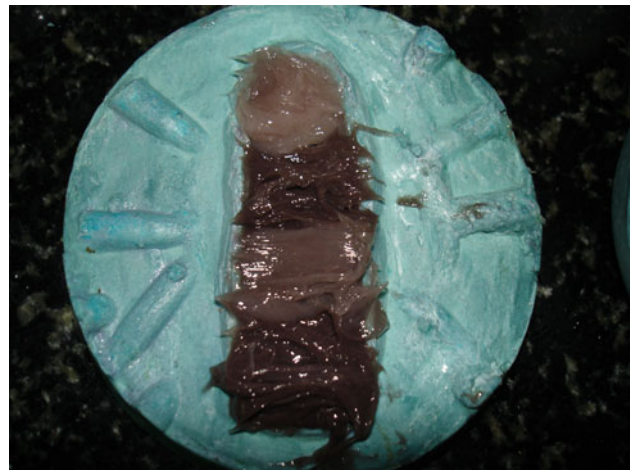
**Fig. 8** Dewaxed flask



**Fig. 10** Base colour silicone-dorsal



**Fig. 9** Base colour silicone-ventral



**Fig. 11** Colour matched and packed

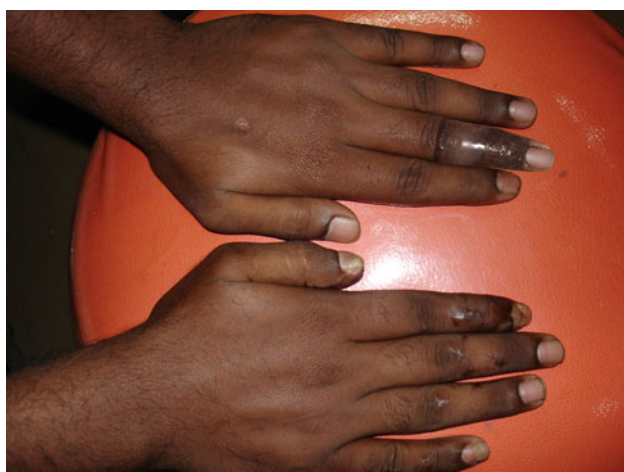5. This wax pattern was then seated in a flask with dental stone material covering it up to the sides. Markings were made on the cast to ensure the correct location of the stump. The undercut formed was to lock the stump to counter balance before flasking procedure. Indices were made on the mould surface to provide a definite location of the mould components. After applying separating medium (DPI) was counter flased and dewaxed (Fig. 8).
6. Appropriate shade matching was done during day light. Following completion of these separate colour swatches (dorsal and ventral surfaces), the colour were added to the corresponding areas of the mould surfaces. This was followed by the addition of base colour silicone and further application of localized swatch colour (Figs. 9, 10, 11). After attaining the

closest possible match on colour of the material, both halves of the mould were closed, placed under bench press and cured over night.

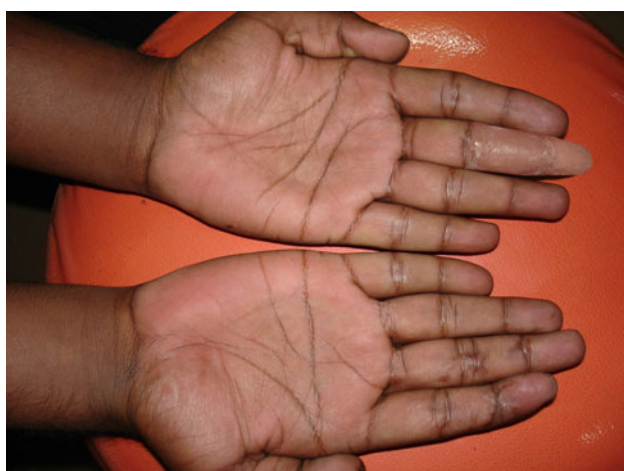
7. For its final curing, it was placed in a hot air oven for 1 h at 45°C. On completion of curing, the mould is removed from the oven and permitted to cool before opening (Fig. 12). The prosthesis was trimmed, finished and checked on the patient's left hand.
8. Acrylic nail was fabricated using tooth coloured acrylic resin material (DPI, cold cure). The fabricated nail shell was trimmed to conform to the nail bed that had been created on the silicone finger prosthesis. Once verified it was smoothed and polished. Single part silicone was dispensed onto the nail bed over which the finished nail shell was positioned and secured in place until it set (Figs. 13, 14).



**Fig. 12** Cured prosthesis



**Fig. 13** Final prosthesis-dorsal



**Fig. 14** Final prosthesis-ventral

## Discussion

The amputation of one or more fingers of the hand, as the consequence of trauma or congenital absence of one or more phalanges, carries a serious reduction of hand function and social dysfunction for the patient [9]. Many injuries and traumatic amputations of fingers can be rescued by microsurgery through re-implantation. However, it may not be advisable [10] or possible in some cases such as the patient's unwillingness or factors such as cost. It is in this group of patients that prosthesis can be provided and may offer great psychological aid [11]. According to Ware, individuals who sustain amputation of a finger or thumb often begin rehabilitation immediately following surgery. Although there are various ways to medically and surgically manage digital amputations, the goals of rehabilitation remain the same: preserve the functional length, preserve useful sensitivity, prevent symptomatic neuromas, prevent adjacent joint contractures, achieve short-duration morbidity, and enable the patient to perform tasks of daily life as quickly as possible [12]. Throughout the world, the major objective of prosthetics is to restore, the functional capacity formerly held by a limb deficient person while attaining the best cosmetic result [13].

Prostheses for the upper limb have been broadly classified as functional and aesthetic [14–18]. The patient may be treated with the surgical or non surgical approach. As the patient was not willing to bear any expenses, a non surgical method of rehabilitation was carried out. Aesthetic prosthesis has been defined as passive devices aimed at restoring normal appearance of the hand. It has also been stated that every case may not be indicated for rehabilitation by an aesthetic prosthesis [14].

Over time various materials have been used and have been developed further. Wood, leather, polyurethane and polyvinyl chloride (PVC) have been used to produce aesthetic prosthesis, but silicone rubber has proved to be the most promising in achieving the desired life like effects [14]. The acceptance of prosthesis has been much higher with the use of custom restoration using silicone elastomer [8]. Multiple layers of clear silicone over each layer of colour improves translucency and protects the coloration from environmental damage. The overall durability and stain resistance of silicone is far superior to any other material currently available for finger restorations. Almost all stains, including ballpoint ink, newsprint, clothing dyes, and food colorings can be removed easily with water and soap [19]. Silicone finger restorations may have additional functional benefits. Many traumatic amputees experience painful hypersensitivity at the termination of finger remnants. The gentle, constant pressure of elastomer prosthesis can help desensitize and protect the injured tip [20]. Some authors have noted that eventually, scar tissue contained

within a silicone prosthesis seems to become more pliant and comfortable [14]. Similar observations have been reported in the medical literature although no conclusive proof has been established [21–23]. Recent literature speculates that silicone gel improves the hydration of the stratum corneum of immature hypertrophic scars [24]. With the property of elasticity of silicone elastomer, it is possible to enhance retention further by scraping grooves into the positive model, creating separate vacuum chambers [25]. A lubricant should be used to lubricate the skin to facilitate donning and doffing of the prosthesis.

## Conclusion

For most patients, the aesthetic appearance of an amputated finger plays a more important role than function. With the advancement in skill, technology and materials available today, the rehabilitation of an amputated finger is no more aesthetically challenging. When fabricated with immense care, they can be made life-like. A well fabricated aesthetic prosthesis can help in providing the patients with psychological support.

## References

- James CH (2003) Amputations of hand. Campbell's operative orthopaedics, 10th edn. Mosby Inc., St. Louis, pp 611–622
- Meier RH (2010) History of arm amputation, prosthetic restoration, and arm amputation rehabilitation. [http://www.demosmedpub.com/files/Meier\\_01.pdf](http://www.demosmedpub.com/files/Meier_01.pdf)
- Fassler PR (1996) Fingertip injuries: evaluation and treatment. *J Am Acad Orthop Surg* 4(1):84–92
- Pillet J (1981) The aesthetic hand prosthesis. *Orthop Clin N Am* 12:961–970
- Murdoch G (1967) Levels of amputation and limiting factors. *Ann R Coll Surg Engl* 40(4):204–216
- Kolb LC (1959) Disturbances in body image. In: Arieti S (ed) *American handbook of psychiatry*. Basic Books, New York, pp 749–769
- Pillet J (1992) Partial-hand amputation-aesthetic restoration. In: Bowker JH, Michael JW (eds) *Atlas of limb prosthetics: surgical, prosthetic and rehabilitation principles*. CV Mosby, St. Louis, pp 227–235
- Buckner H (1980) Cosmetic hand prosthesis—a case report. *Orthot Prosthet* 34(3):41–45
- Cervelli V, Bottini DJ, Arpino A, Grimaldi M, Rogliani M, Gentile P (2008) Bone anchored implant in cosmetic finger reconstruction. *Annales de chirurgie plastique esthetique* 53: 365–367
- Wilson RL, Carter-Wilson MS (1983) Rehabilitation after amputations in the hand. *Orthop Clin N Am* 14:851–872
- Pilley MJ, Quinton DN (1999) Digital prosthesis for single finger amputation. *J Hand Surg Br* 24(5):539–541
- Ware LC (1998) Digital amputation and ray resection. In: Clark GL et al (eds) *Hand rehabilitation: a practical guide*, 2nd edn. Churchill Livingstone, Inc, New York
- Erin S (2006) Prosthetics in developing countries. <http://www.oandp.org/publications/resident/pdf/DevelopingCountries.pdf>
- Venkataswamy R (2010) Aesthetic prosthesis in hand injuries surgery of the injured hand. McGraw-Hill, New York
- Bamugartner R (1981) Active and carrier-tool prosthesis for upper limb amputations. *Orthop Clin N Am* 12:953–959
- Beasley RW (1987) Hand and finger prosthesis. *J Hand Surg Am* 12:144–147
- Fryer CM, Michael JW (1992) Upper limb prosthetics. In: Bowker JH, Michael JW (eds) *Atlas of limb prosthetics: surgical, prosthetic and rehabilitation principles*. Mosby Year Book, St. Louis, pp 107–131
- Lamb DW, Law HT (1987) Upper-limb deficiencies in children: prosthetic, orthotic and surgical management. Little Brown and Company, Boston
- Michael JW, Buckner H (1994) Options for finger prosthesis. *J Prosthet Orthot* 6(1):10–19
- Livingstone DP (1988) The D-Z stump protector. *Am J Occup Ther* 42:185–187
- Ohmori S (1988) Effectiveness of silastic sheet coverage in the treatment of scar kebid. *Plast Surg* 12:95–99
- Quinn KJ (1987) Silicone gel in scar treatment. *Burns* 13: 533–540
- Wessling N, Ehleben CM, Chapman V et al (1985) Evidence that use of a silicone sheet increases range-of-motion over burn wound contractures. *J Burn Care Rehab* 6:503–505
- Burkhardt A, Weitz J (1990) Oncologic applications for silicone gel sheets in soft-tissue contractures. *Am J Occup Ther* 45(5): 460–462
- Herring HW, Romerdale EH (1983) Prosthetic finger retention: a new approach. *Orthot Prosthet* 37(2):28–30