

Prosthetic Rehabilitation of Ocular Defect Using Digital Photography: A Case Report

Sidharth Jain · Sumit Makkar · Sharad Gupta ·
Akshay Bhargava

Received: 15 June 2010 / Accepted: 3 August 2010 / Published online: 15 December 2010
© Indian Prosthodontic Society 2010

Abstract The fundamental objective in restoring a congenital as well as acquired defect of eye with an ocular prosthesis is to enable the patient to cope better with the difficult process of rehabilitation after an enucleation or evisceration. A cosmetically acceptable prosthesis is that reproduces the color, form and orientation of iris and allows the patient to return to accustomed lifestyle. A sequence of steps for construction of custom-made ocular prostheses is outlined in this case report using the advantages of digital imaging technique.

Keywords Custom-made ocular prosthesis ·
Photographic iris · Digital imaging

Introduction

The disfigurement associated with the loss of an eye can cause significant physical and emotional problems. Most patients experience significant stress, primarily adjusting to the functional disability caused by the lost eye and to societal reactions. Thus, replacement of the lost eye is necessary to promote physical and psychological healing for the patient and to improve social acceptance [1].

The need for an artificial eye can sometimes be fulfilled by stock prosthesis that comes in standard sizes, shapes, and colors. Stock ocular eye requires no special skills or

materials for fabrication. They are relatively inexpensive and the entire process is also less time consuming. However, in majority of cases of enucleation custom ocular prosthesis is advantageous as there is improved adaptation to underlying tissues, increased mobility of the prosthesis, and acceptable esthetics due to better match of the size and color of the iris and sclera. Nevertheless, a custom prosthesis is more expensive than a stock prosthesis, and several steps are required for its fabrication [2].

The eye is an even organ and so its reproductions is challenging. The ocular prosthesis must be as similar as possible to the natural eye, mainly regarding the iris, which determines the color of the eyes.

The reproduction of the prosthetic iris is a critical step during the construction of ocular prosthesis. It has been accomplished with all technical and artistic resources available [3].

Several studies in literature proposed prosthetic reproduction of iris, using several materials like paints, pigments and papers, such as white cardboard with watercolor paint [4] or black cardboard [5] and acrylic [6] and oil paint. But most of these techniques depend upon the artistic skills and color science of the operator and are also time consuming.

The main objective of maxillofacial rehabilitation is to mimic nature. This article attempts to simplify the fabrication of ocular prosthesis by means of digital photography to bring in natural esthetics.

Case Report

An 18-year old male patient was referred to Department of Prosthodontics, I.T.S.-CDSR Dental College, Muradnagar, Ghaziabad (India). The patient complained of facial disfigurement due to the loss of right eye. Examination and

The paper was presented in IPS 37th conference held in Thrissur, Kerala and had got 2nd best paper award in session.

S. Jain (✉) · S. Makkar · S. Gupta · A. Bhargava
Department of Prosthodontics including Crown and Bridge and
Implantology, I.T.S. Centre for Dental Studies and Research,
Delhi-Meerut Road, Ghaziabad, India
e-mail: drsidharthjain@yahoo.co.in

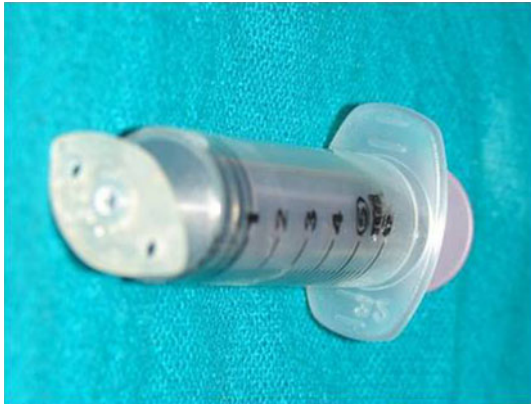

Fig. 1 Custom made impression tray

history revealed that the patient had suffered from chickenpox (Herpes Zoster Ophthalmicus) about 12–14 years back, resulting in pain and swelling of right eye for which took traditional medicaments. Consequently to this, the eye had shrunken.

Ocular examination revealed a healthy intraocular tissue bed and adequate depth between the upper and lower fornices. The conjunctiva covering the posterior wall of the ocular defect showed synchronous movements.

A custom made acrylic resin ocular prosthesis was planned, and the treatment procedure explained to the patient.

Prosthesis Fabrication

- (1) An impression of the ocular defect was made with an ocular shaped acrylic impression tray attached to a 5 ml modified disposable syringe (Dispo van) according to the Miller technique [2]. Light viscosity polyvinylsiloxane (Reprosil, Dentsply Pvt. Ltd, India) was injected into the socket through the modified tray syringe assembly (Figs. 1, 2). The

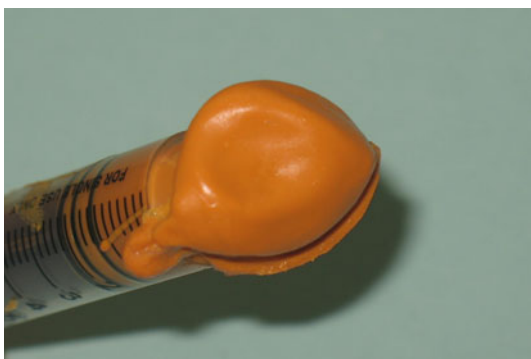

Fig. 2 Ocular impression

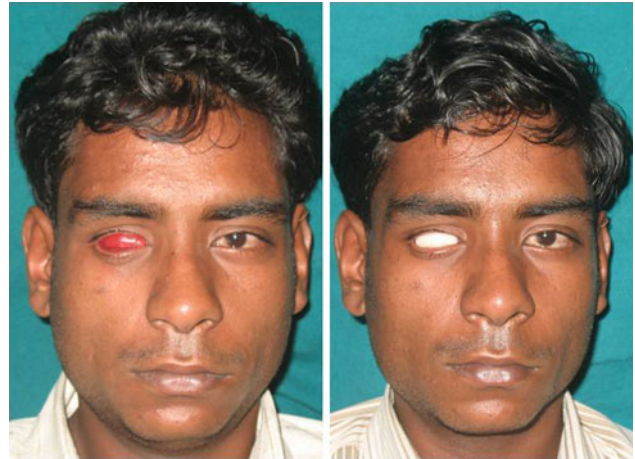

Fig. 3 Try-in of wax pattern and scler blank

patient was instructed to perform eye movements while the impression material set.

- (2) The impression was removed from the socket and initially poured till the height of contour with the type IV dental stone (Kalastone, Kalabhai Pvt Ltd, Mumbai, India). After the stone had set, keyholes were made and boxed. Then a second layer was poured, to obtain a two piece cast. For the orientation of ocular prosthesis.
- (3) The wax pattern was fabricated using modeling wax (Y-Dent, MDM Corporation New Delhi). The fit of the wax pattern was evaluated by observing the extension into the fornices. The height of convexity of the wax pattern should be centered over the pupil and palpebral opening should be same as that of natural eye (Fig. 3).
- (4) A digital photograph of the patient's iris using a digital camera (Nikon COOLPIX P90, New York, U.S.A., 12.1 Megapixel, 24× optical zoom) was made (Fig. 4). The photograph was compared with the patient's natural iris. Adjustment of the color, brightness, contrast, hue, of the image was done by




Fig. 4 Photograph of iris

using graphics software (Photoshop 7.0; Adobe system Inc, San Jose, California). Further color modifications were done by using professional quality color pencils. The final image was printed on good quality photo-paper in different sizes and shades to match the patient natural iris [1].

- (5) Wax pattern was flaked and processed using heat-polymerizing acrylic resin (DPI-Heat cure, Dental Products of India Ltd). The scleral blank was tried in, with the patient sitting erect and viewing an object kept at least 3 feet in front and at eye level of natural eye (Fig. 3). The supraorbital folds, margins of the lower eyelids and iris plane were evaluated, all of which resembled the natural eye.
- (6) During the scleral blank trial, a vertical midline was marked passing through the forehead crease, glabella, tip of nose and chin. The distance from the midline to the medial periphery of the natural iris of the left eye was measured (Fig. 5). Following this, the photographic iris (that best matched the patient iris) was cut from the digital photograph of the patient and transferred on the sclera blank on the right side at the same distance as on the left side.
- (7) An Acrylic resin of 1 mm was removed from the anterior scleral curvature, for better adaptation of photographic iris on to the scleral blank. The Photographic iris was finally attached to scleral blank using cyanoacrylate adhesive. The position of

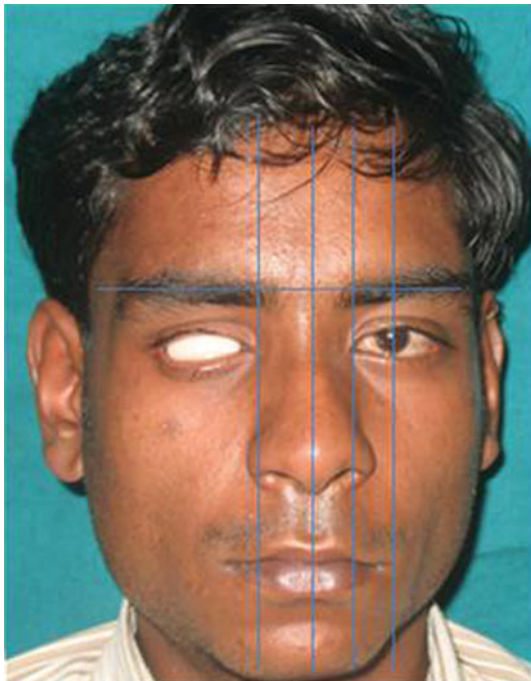


Fig. 5 Orientation of iris

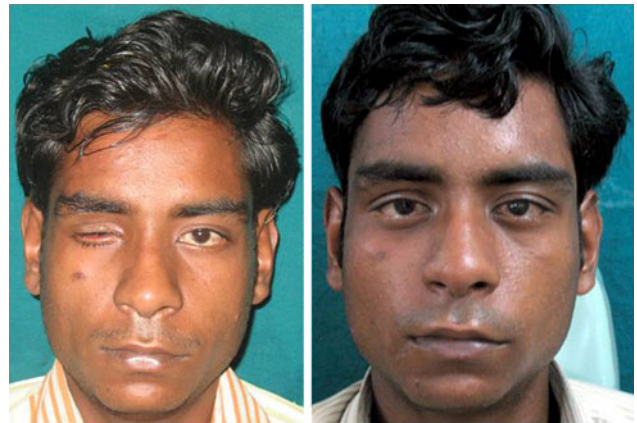

Fig. 6 Preoperative and postoperative facial view

iris was again rechecked by asking the patient to fix his gaze on a predetermined object.

- (8) Characterization of the prosthesis was done by using red silk fibers as veins and stains were added in the sclera part with the help of permanent colors.
- (9) Self cured clear acrylic resin was added over the anterior scleral curvature to recontour the prosthesis. Finishing and polishing of the prosthesis was done.
- (10) The custom ocular prosthesis was then inserted (Fig. 6). The patient was instructed on insertion and removal of the prosthesis. Follow up was done after 1, 3 days and 1 week.

Discussion

The esthetic and psychological benefits of an ocular prosthesis have motivated a constant research in improvement of its prosthetic technique. The general consensus among authors is that close matching the natural eye is the key to mask the loss and achieve an esthetic outcome for patients with ocular defect [3].

The literature has suggested many techniques for the fabrication of ocular prosthesis. Stock eye prosthesis was advocated by Laney [7]. Many clinicians have concluded that iris color of prosthetic eye is most important consideration for the esthetic acceptance of the prosthesis. The main disadvantage of prefabricated eyes is the inability to match iris color [8]. The common techniques for the fabrication of custom made prosthesis are paper iris disk and black iris disk technique. However, painting the iris disk involves both artistic skills and science of color [9].

Using digital imaging in the fabrication of the ocular prostheses presents several advantages as compared to the conventional iris painting technique. The digital image provides acceptable esthetic results as it closely replicates the patient's iris with minimal color adjustments and

modifications. The method is simple, less time consuming, and requires minimal artistic skills, which are necessary in the iris painting technique. Nevertheless, special digital photography equipment and settings, as well as computer software are required for image adjustments [1].

Summary and Conclusion

An accurate iris reproduction in the fabrication of ocular prosthesis is a key factor to achieve an esthetic outcome for patients with ocular defect. A simplistic procedure for fabricating the ocular prosthesis has been suggested here. The method uses a digital photograph of the patient's natural iris for the rehabilitation. The technique has provided good results from patient esthetics, acceptance and satisfaction point of view. Modification of the above technique may include the digital photograph of sclera and iris as a further step toward personalized esthetics.

References.

1. Artopoulou LI, Montgomery CP, Wesley JP (2006) Digital imaging in the fabrication of ocular prostheses. *J Prosthet Dent* 95:327–330
2. Mathew FM, Smith MR, Suttion JA et al (2000) The ocular impression: a review of the literature and presentation of an alternate technique. *J Prosthodont* 9:210–216
3. Reis CR, Dias BR, Carvalho MCJ (2008) Evaluation of iris color stability in ocular prosthesis. *Braz Dent J* 19(4):370–374
4. Murphey PJ, Pitton RD, Schlossberg L, Harris LW (1945) The development of acrylic eye prosthesis at The National Naval Medical Center. *J Am Dent Assoc* 32:1227–1244
5. Raizada K, Rani D (2007) Ocular prosthesis. *Contact Lens Anter Eye* 30:152–162
6. Brown KE (1970) Fabrication of an ocular prosthesis. *J Prosthet Dent* 24:223–225
7. Laney WR (1979) Maxillofacial prosthetics, pp 279–306
8. Taicher S, Steinberg MH, Tubiana I (1985) Modified stock-eye ocular prosthesis. *J Prosthet Dent* 54:95–97
9. Taylor DT (2000) *Clinical maxillofacial prosthetics*, 1st edn. Quintessence Publishing Co., Inc, Chicago, IL, pp 270–276