

Presurgical Nasoalveolar Moulding for a Unilateral Midfacial Cleft: A Case Report

Soumil P. Sarin, Rambhau D. Parkhedkar, Sae S. Deshpande, Pravinkumar G. Patil, Sudhanshu Kothe

© Indian Prosthodontic Society

Although surgical correction remains the mainstay of treating unilateral/bilateral cleft lip and/or palate deformities, some inadequacies still remain like scarring of the nasolabial complex, multiple interventions to achieve desired results, etc. Presurgical nasoalveolar moulding consists of selective repositioning by active moulding of the alveolar segments as well as the surrounding soft tissue. Clinical case of unilateral mid-facial cleft treated by the same, showed significant reduction in the defect size and improved contour of the columella-philtrum region for superior postsurgical esthetics.

Keywords: Nasoalveolar molding, Unilateral midfacial cleft, Presurgical orthopedics

Introduction

The facial cleft deformity or cleft lip, alveolus and palate cannot be treated successfully by only one discipline or speciality. The interaction and consultation between various disciplines enhances their understanding and limitations to devise a comprehensive treatment strategy.

Grayson et al. [1] described presurgical nasolaveolar moulding (PNAM) which involved active moulding and repositioning of the deformed nasal cartilages and alveolar processes as well as the lengthening of the deficient columella.

A basic treatment objective for the cleft lip, alveolus and palate patient is to restore normal anatomy. This includes the nasal components as well. Because of the major hard and soft tissue abnormalities observed in these patients it is highly desirable to restore the correct skeletal, cartilaginous and soft tissue relationships presurgically. In the case of bilateral deformity, it is particularly advantageous to lengthen the

deficient columella prior to the primary surgical repair of the lip and nose [2].

Case history

2-day-old baby boy having a midfacial cleft was brought to our department, with the primary need of a feeder plate. On examination a unilateral cleft lip and palate extending onto the soft palate was seen (Fig. 1).

Treatment procedure

The treatment goals, the procedure and the role of the parents were explained to the patient parents. An impression in low fusing impression compound (Green Tracing sticks, MAARC, Mumbai, MH, India) was made when the patient was a week old.

The size of the cleft was measured on the cast using a vernier caliper (Digital Vernier Calliper 200 mm, Sealy Power Products, Bury St. Edmunds, Suffolk, UK). The distance from the base of the alveolus on one side to the other was found to be approximately 9 mm.

The cleft region of the palate and alveolus was blocked out and normal anatomic contours were built with base plate wax (Fig. 2).

S. P. Sarin¹ ✉ • R. D. Parkhedkar¹ • S. S. Deshpande¹ • P. G. Patil¹ • S. Kothe²

¹Department of Prosthodontics, Government Dental College and Hospital, Nagpur

²Plastic Surgery Consultant, Government Dental College, Nagpur

e-mail: soumilsarin@yahoo.com

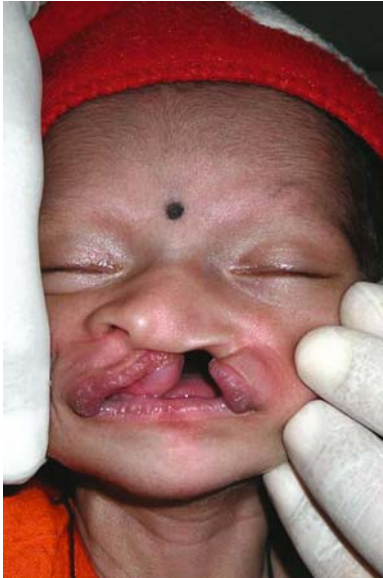

Fig. 1 Pretreatment status (age - 2 days)



Fig. 2 Blockout and development of normal contours in wax

The cast was then duplicated in irreversible hydrocolloid (Neocolloid, Zhermach, Rovigo, Italy) to obtain a working cast on which 2 layers of base plate wax (Y-dents No. 2 Modelling wax, MDM Corp, Delhi, India) was adapted and acrylised in clear heat cure acrylic (Trevalon Clear denture material, Dentsply India, Gurgaon, India).

After the plate was tried in the patient's mouth, a retentive button of self-cured clear acrylic (Rapid Repair, Dentsply India, Gurgaon, India) was attached to the labial flange, at an angle of 45° to the occlusal plane (Fig. 3).

The intaglio surface of the plate was then modified to allow selective pressure on the two segments of the arch so as to correctly align them. One to 1.5 mm thick layer of permanent soft liner [Permasoft, Dentsply Austenal, New York PA] was applied onto the outer surface in the region of the greater segment and the inner surface was relieved to the same extent. One to 1.5 mm of the soft liner was then applied on the inner surface in the region of the lesser segment and the outer region was relieved by 1.5 mm. This caused a force that was directed inward on the greater segment and outward on the lesser segment (Fig. 4).

Two thicknesses of adhesive tapes were required for retentive taping (Fig. 5). The thicker adhesive tapes (0.5 x 2 inches) were secured onto the cheeks of the patients, superior and lateral to the commissures. The thinner tape was looped around a red orthodontic elastic (Tru-Force Latex Elastic System, TP Orthodontics Inc, La Porte, Indiana, USA) (Fig. 6).

The loops were secured onto the larger base tapes with additional adhesive tapes. The direction of the force exerted by the loops was ensured to be laterally and superiorly. (Fig.7)

The patient is then recalled weekly. The parents were taught the procedure for retentive taping and were advised to change the tapes everyday or whenever the tapes peeled off.

When the size of the cleft was reduced to <6 mm, the stage of active nasal moulding was begun.

A nasal stent was constructed of 19 gauge round stainless steel wire (Smith SS wire, KC Smith, Monmouth NPS,

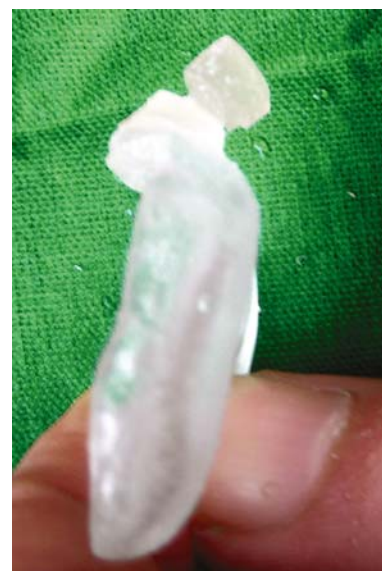

Fig. 3 The retentive button is placed on the clear acrylic plate at an approximate angle of 45° to the occlusal plane

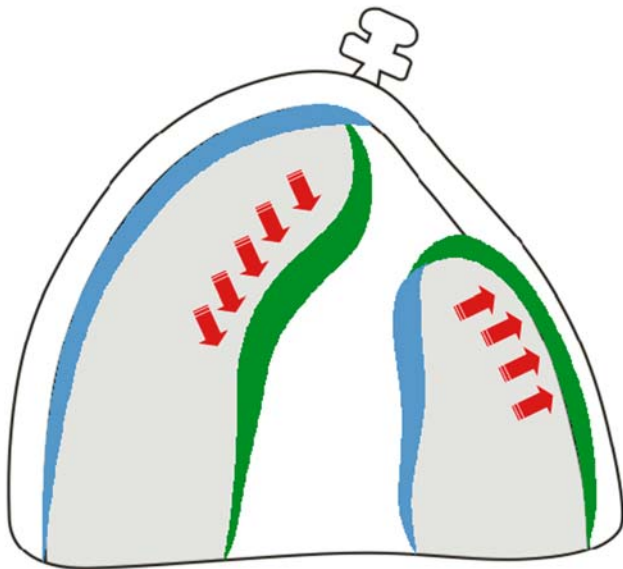


Fig. 4 Schematic diagram of plate: The blue regions indicate the areas where the soft liner was applied and the green areas indicate areas of relief. Red arrows indicate direction of force

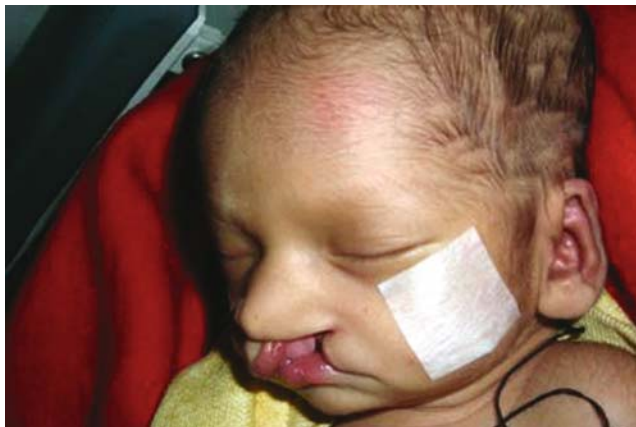

Fig. 5 Base tapes are secured onto the cheeks




Fig. 6 Thinner tapes are used to make loops around orthodontic elastics

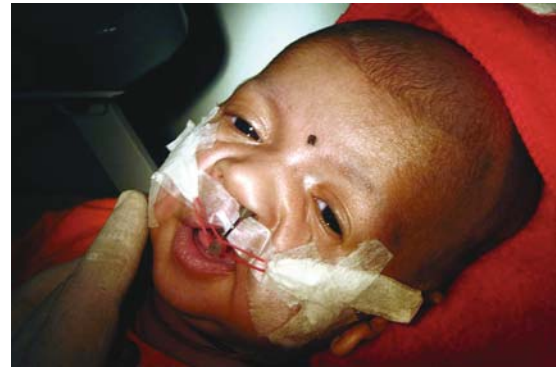

Fig. 7 The tapes should be secured in such a way that the plate has a slight upward and backward pull

UK) and was attached to the retentive button. (Fig. 8) The superior loop was adjusted to fit passively in the nostril. The nasal part of the wire was then covered with self cured clear acrylic and then by a layer of the soft liner to support the nostril to the desired extent (Fig. 9)

At the age of 14 weeks the desired nasal cartilage and alveolar shape was achieved. This can be seen from patient's preoperative (Fig. 10) and postoperative cast (Fig. 11). Figure 12 shows intraoral view of complete approximation of alveolar segments.

The patient scheduled for surgery thereafter.

Discussion

A high degree of plasticity is seen in the cartilages of infants in the first few months after birth. Matuso et al. [3] postulated that a high amount of maternal estrogen caused an increased amount of hyaluronic acid in the fetal cartilage, rendering it

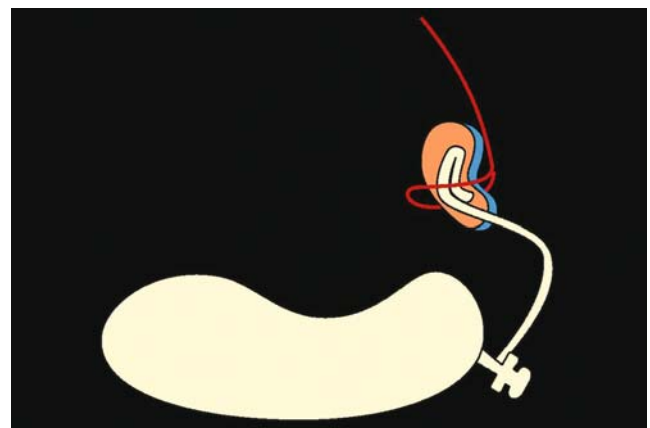


Fig. 8 Schematic diagram of nasal stent: SS wire loop arising from the plate has an acrylic button. Blue area indicates areas where the soft liner was applied

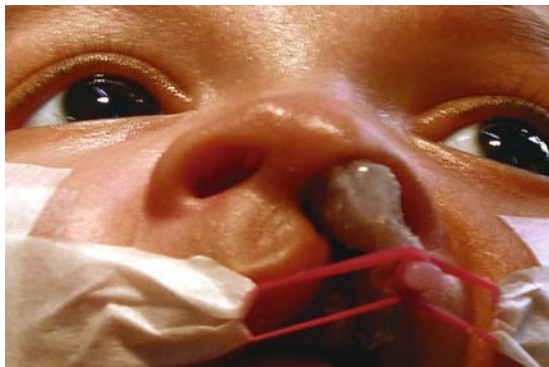

Fig. 9 Extra oral view of plate with nasal stent: The nasal stent should push rim of the nostril outward

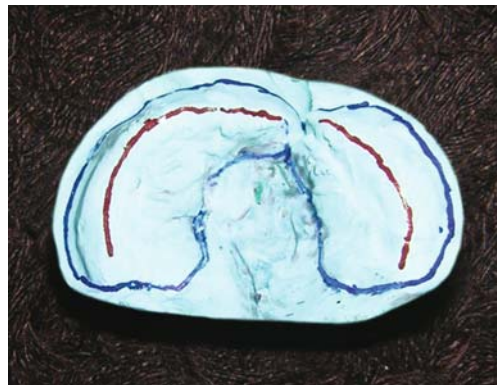


Fig. 11 Post-treatment view of the cast

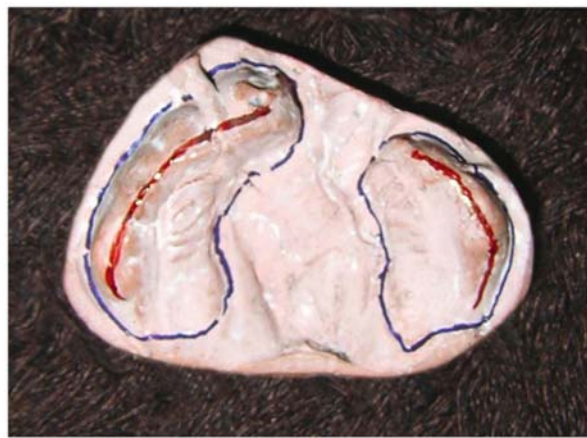


Fig. 10 Pretreatment view of the cast

plastic. Hence active soft tissue and cartilage moulding is most successful during the first 3–4 months after birth.

While PNAM has been proved to be a beneficial approach, especially when used with columella elongation for bilateral cleft deformities, its success depends upon a modified surgical procedure for repair. The surgical procedure advised is the modified gingivoperiosteoplasty (GPP) described by Millard and Latham (1990) [4]. It is usually performed within 12–16 weeks of age but can be postponed if additional weeks of PNAM therapy is deemed necessary. The procedure involves a first stage primary lip-nose repair with GPP to close the alveolar defect. This should be followed by a one stage palatal repair at 11–13 months of age when phoneme speech development is evident [5].

Conclusion

PNAM allows an overall improvement in the aesthetics of the nasolabial complex in both the unilateral and bilateral cleft conditions while minimizing the extent of the surgery and the overall number of surgical procedures.

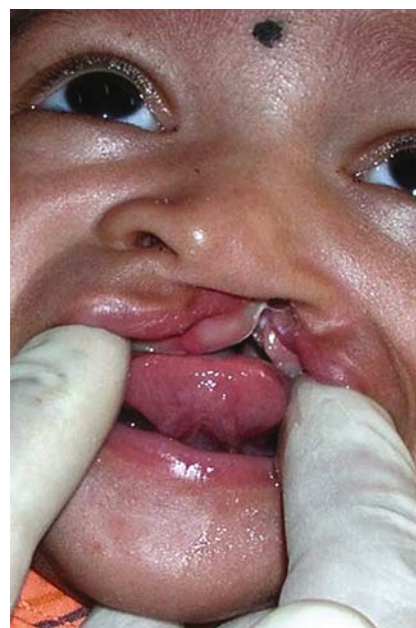

Fig. 12 Post-treatment status (age - 8 weeks)

References

1. Grayson BH, Cutting CB, Santiago PE, Brecht LE (1999) Presurgical nasoalveolar moulding in infants with cleft lip and palate. *Cleft Palate Craniofac J* 36:486–498
2. Taylor TD (Ed.) *Clinical Maxillofacial Prosthetics*. 1st edition, (2000) Quintessence Pub., Illinois pp 68–83
3. Matuso K, Hirose T (1991) Preoperative nonsurgical over-correction of cleft lip nasal deformity. *B J Plast Surg* 44:5–11
4. Millard DR, Latham RA (1990) Improved primary surgical and dental treatment of clefts. *Plast Reconstr Surg* 86: 856–871
5. Grayson BH, Wood RJ, Cutting CB (1997) Gingivoperiosteoplasty and midfacial growth. *Cleft Palate Craniofac J* 34:17–20