

Failure of extracoronar direct retainers: Causes and preventions

Review Article

Meena A. Aras, Prabhakar B. Angadi

ABSTRACT

Failure of removable partial denture may be attributed to several factors, one of which is failure of extra coronal direct retainer. Direct retainers can serve for a long time if designed and fabricated properly by the dentist and maintained well by the patient. This article is the review of causes of failure of extra coronal direct retainers and prevention of the same.

KEY WORDS: Direct retainer, design, failure

DOI: 10.4103/0972-4052.55249

The management of partial tooth loss involves replacement with removable partial denture that is a conservative and economic treatment option. Failure of removable partial denture during service is due to various reasons. The most common cause is failure of extra coronal direct retainer. The term failure includes either breakage or distortion of the clasp arm. An analysis of the possible causes of failure is essential before the repair is begun, so that contributing factors can be eliminated.

This article reviews the causes of failure of extra coronal direct retainer and prevention of the same during different stages of denture designing and fabrication.

CLINICAL STAGE

1. Inadequate diagnosis and treatment planning. The teeth to be used as abutments for the partial dentures should be evaluated clinically and radiographically. The amount of undercut on each abutment should be determined and measured which is accomplished by proper use of surveyor. Analysis and accomplishment of tooth contour modification is required for optimum retention of prosthesis. Based on the amount and location of undercut, direct retainer is selected. Any negligence

at this initial stage will lead to failure of the direct retainer.

2. Design considerations: Faulty designing of clasp may result in breakage of the retentive arm that is due to repeated flexure into and out of tooth undercut. Proper location of clasp arm in an acceptable retentive undercut area can prevent this type of breakage. Breakage may occur as a result of structural failure of the clasp arm itself. A cast retentive arm that is not appropriately tapered or uniform bulk is not provided to cast reciprocal arm will eventually break^[1] [Figure 1].

Wrought wire clasp arm may fail because of repeated flexure at the region where it exits from the denture base. An effective way to prevent this is to solder the clasp to the metal base of the saddle and then cover the solder joint with acrylic resin.

If cast cobalt chromium circumferential retentive clasp arm engages more than 0.25 25 mm of undercut, its proportional limit will be exceeded during placement and removal of the denture. The clasp thus may become permanently deformed and therefore non-retentive. It should be made sure that the retentive clasp arm is approximately 15 mm in length for the clasp to flex 0.25 0.25 mm without permanent deformation.^[2]

Department of Prosthodontics, Goa Dental College and Hospital, Bambolim-403202, Goa, India

Address for correspondence: Dr. Prabhakar B Angadi, Department of Prosthodontics, Goa Dental College and Hospital, Bambolim-403 202, Goa, India. E-mail: drprabhakar_angadi@yahoo.co.in

A wrought wire clasp can engage 0.5–0.5 mm of undercut as it has higher proportional limit than a cast clasp but it should be at least 7 mm in length to engage the undercut without deforming permanently.^[2]

A retentive arm tip must always be provided with a diametrically opposite reciprocal arm. If there is no reciprocation, the clasp will be able to escape from the undercut without flexing and retentiveness of the clasp will be reduced^[2] [Figure 2].

3. During adjustment phase:

Fracture of chrome cobalt alloy clasps during adjustment is usually due to sudden quick bends or an excessive manipulation at any one time. Clasps should be adjusted a small amount at a time in same direction.

A wrought wire clasp arm can normally be adjusted several times over a period of years without failure. It is only when the number of adjustments is excessive that breakage is likely to occur.^[3]

LABORATORY PROCEDURES

Wax pattern selection

A clasp pattern should be of adequate diameter. Insufficient diameter produces a weak clasp and subsequent fracture, while a bulky clasp pattern results in an excessive buccolingual dimension of the posterior occlusal table.^[4]

Occlusal relationships should ensure adequate clearance between clasps and opposing cusps.

Distortion of the clasp pattern

Clasp patterns should be refrigerated and lifted from the card with a quick snap.^[3] This technique minimizes distortion of the clasp pattern and prevents a weakened clasp.

Excessive stretching and thinning of the clasp pattern in the buccal surface area of maxillary molar which is extremely bulbous and has an unfavorably high survey line should be avoided to prevent a weakened clasp readily subject to breakage^[4] [Figure 3].

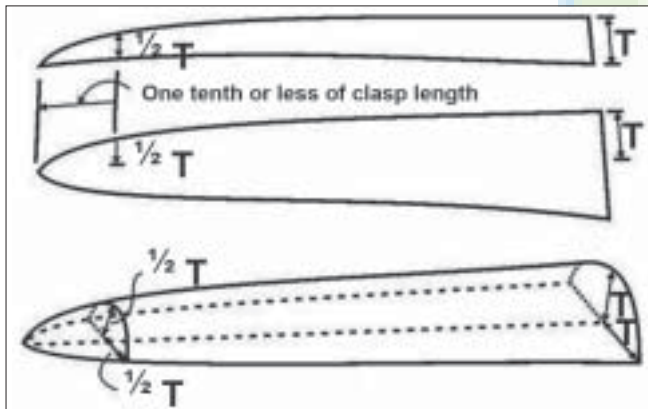


Figure 1: Appropriate taper of retentive arm

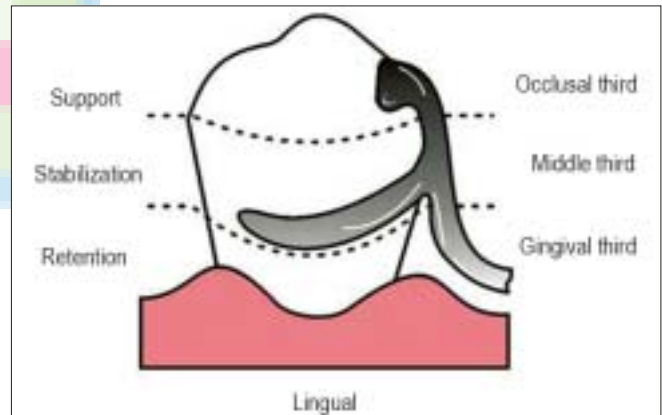


Figure 2: Reciprocal arm

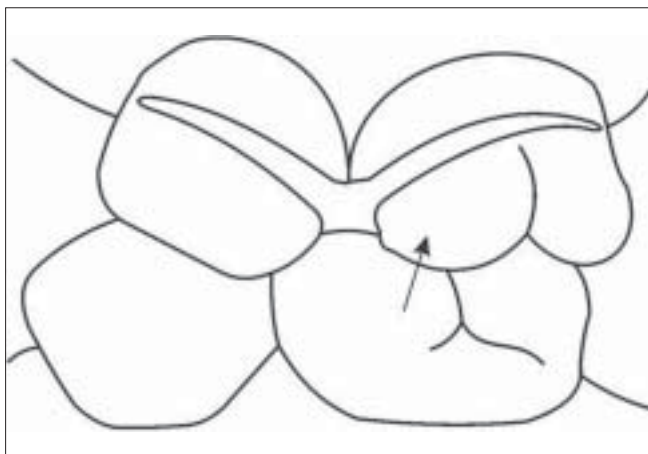


Figure 3: Distortion of clasp pattern

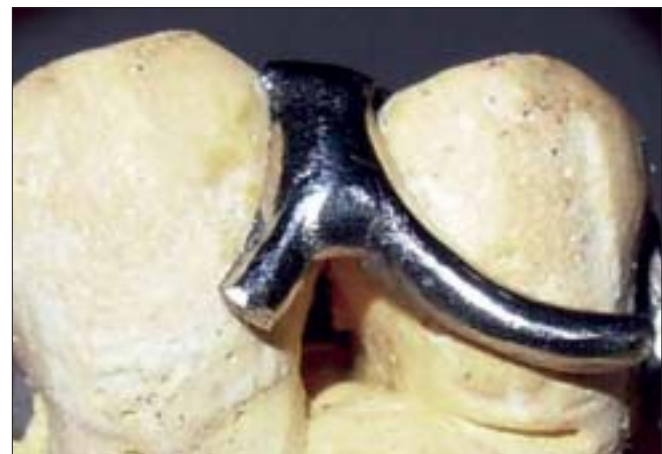

Figure 4: Breakage of clasp arm during use

Clasp pattern positioning

There should be adequate occlusal clearance while the wax clasp arm is positioned which is often possible with simple hand articulation. The position of clasp arm must be in harmony with the opposing occlusion especially on the buccal surface of the mandibular posterior teeth.^[4]

Waxing contours

The junctions of clasp arms to other components of the partial denture framework should be smooth and rounded.^[4]

During casting

Wrought wire clasp arm may break at the point of origin because of recrystallization of the metal. This can be prevented by proper selection of wrought wire, avoiding burn out temperatures exceeding 1300°F and excessive casting temperatures when a cast-to method is used. When using soldering technique, soldering may be done electrically to prevent overheating of wrought wire which may lead to breakage of the clasp arm.^[1]

Finishing and polishing

Over polishing and finishing of the clasp assembly which promotes weakening and fracture should be avoided.^[4]

DURING USE

The role of dental professional is not just limited to the treatment of the oral condition presented by the patient, his responsibility further extends to identify any kind of complication or failure that may occur or has occurred either during the course of treatment or post treatment.^[1]

Breakage of clasp [Figure 4] arm may occur because of careless handling by the patient commonly caused by accidental dropping of removable partial denture.

Patient education in placement and removal of the denture is essential. The simple way to remove a denture with cast circumferential clasp is to slip a fingernail under a buccal clasp arm on each side of the arch and to push the clasp occlusally. However, for a denture with wrought wire clasp, the patient should grasp the saddle area on each side of the arch, if present, between the thumb and forefinger and remove the denture. For a denture with bar clasp, the patient should engage the non-retentive tip of the T clasp and apply occlusal pressure to disengage the clasp.^[3]

REFERENCES

1. Carr AB, McGivney GP, Brown DT. McCracken's removable partial prosthodontics. 11th ed. 1987. p. 384.
2. Davenport JC, Basker RM, Heath JR, Ralph JP, Glantz PO, Hammond P. Clasp design. Br Dent J 2001;190:71-81.
3. Stewart KL, Rudd KD, Kuebker WA. Clinical removable partial prosthodontics. 2nd ed. 497,504.
4. Gonten AS, Nelson DR. Laboratory pitfalls that contribute to embrasure clasp failure. J Prosthet Dent 1985;53:136-8.

Source of Support: Nil, Conflict of Interest: None declared.

Dispatch and return notification by E-mail

The journal now sends email notification to its members on dispatch of a print issue. The notification is sent to those members who have provided their email address to the association/journal office. The email alerts you about an outdated address and return of issue due to incomplete/incorrect address.

If you wish to receive such email notification, please send your email along with the membership number and full mailing address to the editorial office by email.