

# Prosthetic management of a case of advanced periodontitis with telescopic dentures

Vernie Ann Fernandes, Vidya Chitre, Meena Aras

Department of Prosthodontics, Goa Dental College and Hospital, Bambolim-403 202, Goa, India

## For correspondence

Dr. Vernie Ann Fernandes, Department of Prosthodontics, Goa Dental College and Hospital, Bambolim-403 202, Goa, India.  
E-mail: vernie\_fdes@yahoo.co.in

The crown and sleeve coping denture is a removable prosthesis that is supported by both selectively retained teeth and the residual ridge or mucosa. It is a versatile and successful means of achieving the long-term restoration of the partially edentulous jaw. Insertion and removal of the denture and routine oral hygiene are easy to perform. The beneficial results of this form of treatment can be considered for a whole variety of clinical applications for the severely advanced periodontitis case. This paper presents a case report on the prosthetic rehabilitation of a partially edentulous patient with a combined fixed-removable denture for the maxilla and a flexible denture for the mandible.

**Key words:** Crown and sleeve coping, double crown, telescopic

**DOI:** 10.4103/0972-4052.49186

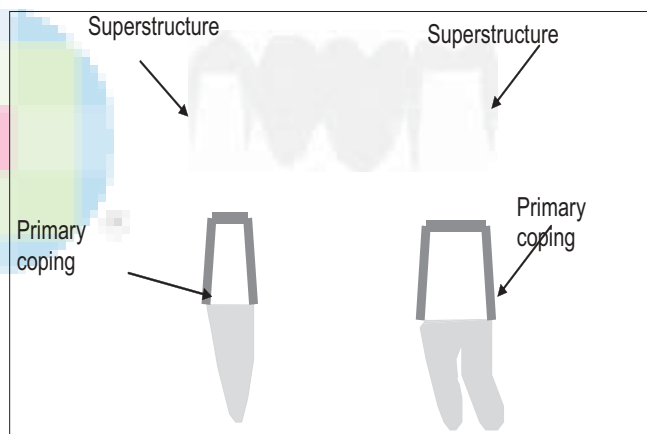
## INTRODUCTION

Although first described by Starr in 1886, telescopic copings were initially introduced as retainers for removable partial dentures at the beginning of the 20th century.<sup>[1]</sup> Because of its resemblance to the collapsible optical telescope, this system of double crowns, which can be fitted one into the other, became known as the telescopic denture.<sup>[2]</sup> Telescoping refers to the use of a primary full coverage casting (coping/male telescopic portion) luted to the prepared tooth with a secondary casting (superstructure/secondary crown / female telescopic portion) which is part of the denture framework and is connected by means of interfacial surface tension over the primary casting.<sup>[3,4]</sup> Alternate descriptive terms are *double crown*, *crown and sleeve coping*, or *Konuskrone*, which is a German term for a cone-shaped design.<sup>[1]</sup>

They act by transferring forces along the direction of the long axis of the abutment teeth and provide guidance, support, and protection from movements that might dislodge the removable partial dentures.<sup>[5]</sup>

Telescopic crowns can also be used as indirect retainers to prevent dislodgement of the distal extension base away from the edentulous ridge.<sup>[4]</sup>

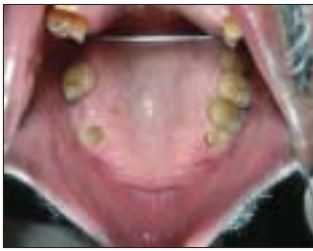Telescopic copings have been used for many years in the oral rehabilitation of patients with advanced periodontal disease. Patients with periodontal disease undergoing prosthetic reconstruction often present with teeth with minimal supportive tissue and increased tooth mobility. Therefore, it is extremely important for the prosthesis not to cause periodontal destruction



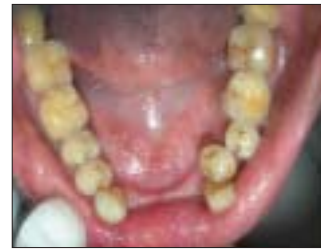or worsen an existing periodontal condition.<sup>[3,6]</sup>

Three different types of double crown systems are used to retain RPDs. They are distinguished from each other by their retention mechanisms:<sup>[2,5]</sup>

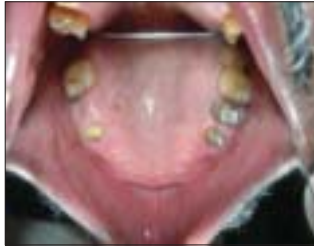1. Cylindrical crowns which exhibit retention through friction fit of parallel milled surfaces
2. Conical crowns or tapered telescopic crowns which exhibit friction only when completely seated using a “wedging effect”. The magnitude of the wedging effect is mainly determined by the convergence angle of the inner crown; the smaller the convergence angle, the greater the retentive force.
3. Double crown with clearance fit (hybrid telescope or hybrid double crown) exhibits no friction or wedging during insertion or removal. Retention is achieved by using additional attachments or functional molded denture borders.



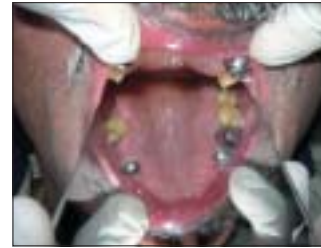**Figure 1:** Maxillary arch after extraction of periodontally involved teeth



**Figure 2:** Mandibular arch showing lingually inclined teeth




**Figure 3:** Tooth preparation done for primary copingsteeth



**Figure 4:** Primary copings evaluated for fit



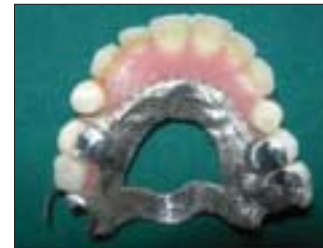**Figure 5:** Elastomeric pick up impression



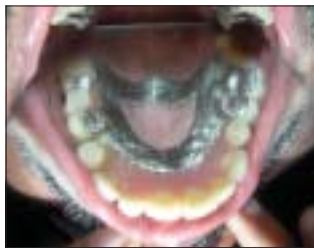**Figure 6:** Milling of primary copings on second master model



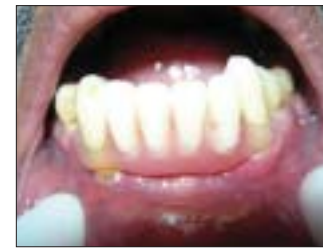**Figure 7:** Final prosthesis evaluated intra orally



**Figure 8:** View of the telescopic prosthesis



**Figure 9:** A flexible denture replacing mandibular anterior teeth



**Figure 10:** Evaluation of flexible denture intra orally



**Figure 11:** Delivery of final prostheses

## CASE REPORT

A 65-year-old male reported to the Department of Prosthodontics, Goa Dental College and Hospital, with a chief complaint of loose dentures and soreness of the mouth.

Patient gave a medical history of diabetes mellitus since 15 years and hypertension since 23 years.

He was currently on oral hypoglycemics and anti-hypertensives. He gave a dental history of wearing the same maxillary and mandibular RPDs since 10 years, which gradually became loose. The patient also gave a history of undergoing periodontal surgeries around 8 months back.

A preliminary examination revealed that the patient had missing 11, 12, 14, 16, 21, 22, 24, 31, 32, 41, and 42. The maxillary canines were grade III mobile while 15, 25 and 26 were grade II mobile. There was generalized grade I mobility of the remaining teeth. Also there was grade II furcation involvement of 46, 36 and grade I furcation involvement of 26. A generalized pocket depth of 4-6 mm was noted. Oral hygiene was fair.

Diagnostic impressions were made using irreversible hydrocolloid impression and an inter-occlusal bite registration was taken. The impressions were poured and the diagnostic models were mounted on a mean value articulator. A diagnostic surveying of the models was done.

A complete radiographic survey was carried out to correlate with the clinical findings.

The OPG revealed generalized horizontal bone loss up to the middle 1/3<sup>rd</sup> of the roots, and bone loss up to apical 1/3<sup>rd</sup> was seen in 13, 23. Also, furcation involvement was seen in 26, 36 and 46, thus indicating severe periodontitis.

It was decided to extract both the maxillary canines due to advanced periodontitis followed by a thorough oral prophylaxis and a flap surgery in 15, 26 region to decrease the pocket depth. The periodontal status was reviewed after 6 weeks. After ascertaining the decrease in tooth mobility and pocket depth, prosthetic rehabilitation was carried out.

During the definitive intra-oral examination the potential abutments were evaluated clinically to determine their periodontal condition, pockets, mobility, caries, old restorations, vitality, abrasions, and supra-eruption [Figures 1 & 2].

The diagnostic findings were as follows:

1. A discrepancy in the occlusal plane was noted due to supra-eruption of 25, 26.
2. The potential abutments had varying paths of insertion.
3. The mandibular teeth were lingually inclined.
4. The abutments had a large crown:root ratio.

### Treatment plan

It was decided to prosthetically rehabilitate this patient with a telescopic denture for the maxillary arch and a flexible denture for the mandibular arch

15, 25, 26 were used as telescopic retainers. A conventional circumferential clasp with a mesial occlusal rest was planned on 17. Intentional RCTs

were performed on 25, 26.

Tooth preparation was done by preparing a chamfer finish line of 0.7 mm and axial wall heights of 4 mm in 15 and 6 mm in 25, 26 with a taper of approximately 8-10°. A proximal guide plane and a mesial occlusal rest seat were prepared on 17 [Figure 3].

After the mouth preparation in the maxillary arch, gingival retraction was done and a final impression was made with addition silicone using the putty wash technique. The first master model was prepared from the impression for fabrication of the primary copings. This was followed by making an interocclusal record using putty and a facebow transfer.

In the laboratory, the wax patterns were prepared for the primary copings on 15, 25 and 26. The patterns were milled to obtain a frictional surface for retention and then cast in nickel chrome alloy (high chrome soft). Once the primary copings were evaluated for fit [Figure 4], the copings were luted with temporary cement (zinc oxide eugenol) and an over impression was made using the medium viscosity addition silicone impression material and the second master model was made [Figure 5]. This model would be used for fabrication of the cast partial superstructure. Bite registration was repeated and the models with the copings were mounted on a semi-adjustable articulator using the same facebow record.

In the laboratory, the copings on the second master model were milled with a parallelometer to obtain a milled surface of minimum 4 mm for friction [Figure 6]. The second master model together with the primary copings was duplicated and the refractory model was prepared. The cast partial framework was waxed up which was then cast using a base metal alloy (cobalt-chrome).

After evaluating the fit of the framework in the mouth [Figure 7], it was used as a carrier for cementing the primary copings in place. The primary copings were luted with glass ionomer luting cement (Type I; GC Fuji). A wax rim was prepared on the framework and acrylic teeth were set. After verification of esthetics, function and phonetics the maxillary denture was processed [Figure 8].

The mandibular denture was processed using a flexible denture material (Valplast) because of the lingually inclined mandibular teeth [Figure 9]. The lingually tilted mandibular teeth (with severe crowding) resulted in severe undercuts on the lingual aspect, thus restricting the use of a lingual bar/ linguoplate. Another option would be the labial bar/ swing lock connector, which was not chosen because of its bulky design, shallow labial vestibular depth and patient objection. Also, as the teeth to be replaced included only the mandibular incisors and the periodontal support of the remaining teeth was adequate, a flexible denture was opted for as it improved the esthetics

as well as function and comfort for the patient [Figure 10]. The completed prostheses were evaluated for function, esthetics and phonetics [Figure 11].

## DISCUSSION

A telescopic RPD was chosen for this patient because of its good retentive and stabilizing properties, rigid splinting action and better distribution of stresses.

Other treatment options included extraction of 15, 25, 26 followed by a conventional cast partial denture. This was not opted for because extraction would decrease the available support and proprioception provided by the teeth and their periodontal ligaments. Reduction of 15, 25 and 26 as overdenture abutments followed by a cast partial overdenture was another option. However, a telescopic denture would provide better retention for the prosthesis as compared to a conventional tooth supported overdenture. Implant supported prosthesis was not opted for as the patient was medically compromised and because of the cost involved in the procedure.

Clinical longevity of a removable partial denture is essentially influenced by the applied restorative concept of connecting the removable denture with the remaining teeth. With regard to number, alignment and periodontal status of the remaining teeth, the clinician needs to select the appropriate retainer for a long-term successful restoration. Telescopic or double crowns have proven an effective means of retaining RPDS.

In this situation, a total of 4 abutments (3 telescopic copings on 15, 25, 26 and a mesial occlusal rest on 17) were used to support the RPD thus creating a quadrilateral configuration. It has been reported that at least two abutment teeth should be splinted when attachment prostheses are used in order to make the stress patterns more favorable.<sup>[7]</sup> The advantage of opting for this treatment plan was to distribute the load among the remaining periodontally weakened teeth, thus acting as a rigid splint. This option was thought to have a better prognosis for the remaining teeth as well as have a more retentive prosthesis.

The recommended alloys for fabrication of copings are the high noble (ADA Type IV). Ag-Au-Pd alloys have better precision, better retention but are technique sensitive and costly. Base metal alloys (Cr-Co) can also be used because they have low thermal conductivity, thus patient does not experience unpleasant thermal sensation caused by excessive tooth preparation. They are easy to fabricate and more economical.<sup>[8]</sup>

The advantages and disadvantages of telescopic overdentures are summarized as follows:

### Advantages<sup>[4,9,10]</sup>

- Creation of a common path of insertion

- Routine oral hygiene is easy to perform
- Rigid splinting action
- Distribution of stresses to the abutment teeth
- Provides suitable abutments for RPDs even when the remaining teeth are periodontally compromised
- Insertion and removal is much easier for the patient
- Accommodates future changes in the treatment plan
- Psychologically well tolerated by patients

### Disadvantages<sup>[4,9,11]</sup>

- Increased cost
- Complex laboratory procedures
- Extensive tooth reduction required
- Increased number of dental appointments
- Difficulty in achieving esthetics
- Retention diminishes after repeated insertion/separation cycles
- Readjustment of retentive forces is difficult

## CONCLUSION


Although fixed restoration provides favorable conditions for preservation of oral function, telescopic RPDs may be considered as another option, combining good retentive and stabilizing properties with a splinting action. The telescopic system may therefore be seen as providing suitable abutments for RPDs even when the remaining teeth are compromised. For other prostheses, excellent oral hygiene maintenance is essential for an optimal prognosis. With telescopic construction, apart from the splinting of the abutment teeth with the telescopic system, the gingival tissues are easily accessible around the entire marginal circumference of the abutment, thus permitting easy home care and oral hygiene. However, correctly implemented plaque control is fundamental in the prevention of recurrence of gingivitis.

## REFERENCES

1. Gungör MA, Artunç C, Sonugelen M. Parameters affecting retentive force of conus crowns. *J Oral Rehabil* 2004;31:271-7.
2. Wenz HJ, Lehmann KM. A telescopic crown concept for the restoration of the partially edentulous arch: The Marburg double crown system. *Int J Prosthodont* 1998;11:541-50.
3. Weaver JD. Telescopic copings in restorative dentistry. *J Prosthet Dent* 1989;61:429-33.
4. Langer A. Telescopic retainers for removable partial dentures. *J Prosthet Dent* 1981;45:37-43.
5. Wenz HJ, Hertrampf K, Lehmann KM. Clinical longevity of removable partial dentures retained by telescopic crowns: Outcome of the double crown with clearance fit. *Int J Prosthodont* 2001;14:207-13.
6. Polansky R, Haas M, Lorenzoni M, Wimmer G, Pertl C.

- The effect of three different periodontal pre-treatment procedures on the success of telescopic removable partial dentures. *J Oral Rehab* 2003;30:353-63.
7. Saito M, Miura Y, Notani K, Kawasaki T. Stress distribution of abutments and base displacement with precision attachment- and telescopic crown-retained removable partial dentures. *J Oral Rehabil* 2003;30:482-7.
  8. Weber H, Frank G. Spark erosion procedure: A method for extensive combined fixed and removable prosthodontic care. *J Prosthet Dent* 1993;69:222-7.
  9. Langer A. Tooth supported telescopic restorations. *J Prosthet Dent* 1981;45:515-20.
  10. Issacson GO. Telescopic crown retainers for removable partial dentures. *J Prosthet Dent* 1969; 22:436-48.
  11. Minagi S, Natsuaki N, Nishigawa G, Sato T. New telescopic crown design for removable partial dentures. *J Prosthet Dent* 1999;81:684-8.

**Source of Support:** Nil, **Conflict of Interest:** None declared.



### Staying in touch with the journal

- 1) **Table of Contents (TOC) email alert**  
Receive an email alert containing the TOC when a new complete issue of the journal is made available online. To register for TOC alerts go to [www.jprosthodont.com/signup.asp](http://www.jprosthodont.com/signup.asp).
- 2) **RSS feeds**  
Really Simple Syndication (RSS) helps you to get alerts on new publication right on your desktop without going to the journal's website. You need a software (e.g. RSSReader, Feed Demon, FeedReader, My Yahoo!, NewsGator and NewzCrawler) to get advantage of this tool. RSS feeds can also be read through Firefox or Microsoft Outlook 2007. Once any of these small (and mostly free) software is installed, add [www.jprosthodont.com/rssfeed.asp](http://www.jprosthodont.com/rssfeed.asp) as one of the feeds.