

# Esthetic considerations for the interdental papilla: Eliminating black triangles around restorations: A literature review

Iyer Satishkumar Krishnan, Mohit G. Kheur

Department of Prosthodontics, M. A. Rangoonwala College of Dental Sciences and Research Centre, Pune - 411 001, India

## For correspondence

Dr. Iyer Satishkumar Krishnan, C/o M. A. Rangoonwala College of Dental Sciences and Research Centre, 2390 B.K.B. Hidayatullah Road, Azam Campus Camp, Pune - 411 001, India. E-mail: [dr.satishiyer@gmail.com](mailto:dr.satishiyer@gmail.com)

Several reasons contribute to the loss or absence of interdental papillae and establishment of 'black triangles' following the placement of bridges/individual crowns or restoration of implants, mainly in the anterior region. The most common reason for the absence in the adult population is loss of periodontal support because of plaque-associated lesions. The other causes include abnormal tooth shape, improper contour of prosthetic restorations and traumatic oral hygiene procedures. These Black Triangles appear extremely unesthetic and are unacceptable to the patients who deserve more than 'these will fill up in a few week's time' from the dentist. It is evident that something as seemingly insignificant as the interdental papilla can shatter the esthetic results of the best fabricated crowns. Several surgical and non-surgical procedures have been proposed to treat the soft tissue deformities in the interproximal areas. The non-surgical approaches modify the interproximal space whereas the surgical approaches aim to recontour, preserve or reconstruct the soft tissue between the teeth and implants. This review deals with an in-depth discussion of the interdental papilla, reasons for its absence around dental restorations and various documented methods of preserving and regenerating it so as to deliver the best overall prosthetic results. This review discusses the interdental papilla in detail and categorizes the various approaches to restore the same.

**Key words:** Black triangles, interdental papilla regeneration

'Black triangles,' seen after the placement of crowns/bridges in anterior teeth are a point of esthetic concern. Over the years, many people have carried out various studies, and attempted to preserve, recontour, and reconstruct the interdental papilla, thereby improving the overall look of the patient. This paper provides an insight into the etiology for the occurrence of black triangles around the cervical portions of the teeth and the various treatment modalities to eliminate them.

## REVIEW OF LITERATURE

In 1985, Shapiro<sup>[1]</sup> studied the possibility of regeneration of interdental papillae using periodic curettage. He stated that repeated scaling, root planning, and curettage of the papillary tissue every 15 days for 3 months may induce a proliferative hyperplastic inflammatory reaction of the papilla and may be used to reconstruct papillae destroyed by acute necrotizing ulcerative gingivitis.

In 1985, Takei *et al.*<sup>[2]</sup> described the papilla preservation technique for periodontal surgeries. According to the authors, if the papilla was preserved in any surgical

procedure, the probability of having the papilla post treatment is significantly enhanced.

In 1989, Audigo *et al.*<sup>[3]</sup> gave esthetic modifications in periodontal therapy with an emphasis on preserving interdental papilla to enhance the esthetic outcome.

In 1992, Tarnow *et al.*<sup>[4]</sup> studied the effect of the distance from the contact point to the crest of the bone on the presence or absence of the interproximal dental papilla. The authors concluded that papilla was present in almost all of the cases where this distance was less than 5 mm.

In 1995 and 1999, Cortellini described a modification to the conventional papilla preservation flap. This was the modified and simplified papilla preservation technique.<sup>[5,6]</sup> According to the authors, modified papilla preservation technique is best applied in anterior teeth where the interdental space is greater than 2 mm and simplified papilla preservation technique is best applied in areas where the interdental space is less than 2 mm.

In 1996, Kokich<sup>[7]</sup> described the orthodontic and periodontic connection. According to the author, a contact point should be established by bodily movement of adjacent teeth that should be less than 5 mm from

the crest of the alveolar bone. This resulted in the formation of interdental papilla following space closure where there was none before.

In 1998, Tarnow and Nordland<sup>[8]</sup> proposed a classification system for loss of papillary height. This was one of the first approaches to classify papillary loss and is still popularly used even today. The system used interdental contact point, facial apical extent of apical cemento-enamel junction (CEJ) and the interproximal coronal extent of the CEJ to classify papillary loss. Accordingly four categories were identified.

In 1999, Blatz *et al.*<sup>[9]</sup> gave a detailed description on the reconstruction of the lost interproximal papilla. The paper presented various surgical and non-surgical approaches to restore the same.

In 2000, Han and Takei<sup>[10]</sup> reported on the progress in gingival papilla reconstruction. They stated that apical lengthening of the contact point would enable the soft tissue to fill up the entire interdental space.

In 2001, Cortellini<sup>[11]</sup> revolutionized periodontal surgery by using a microsurgical approach to periodontal regeneration. The use of microsurgical instruments optimized clinical results in terms of success rate as well as esthetics since surgical access to the interdental tissues is greatly improved and the procedure is associated with a very high ability to predictably obtain and maintain a primary closure of interdental tissues over barrier membranes.

## INTERDENTAL SPACE AND INTERDENTAL PAPILLA

Interdental space is the physiologic space between two adjacent teeth. It is composed of four pyramidal embrasures, viz. cervical, occlusal/incisal, buccal, and lingual/palatal.<sup>[12]</sup> The apex of each pyramid ends at the contact point between two teeth.

The space is occupied by the interdental papilla. It is composed of dense connective tissue. Its shape is defined by (a) the contact relationship between teeth, (b) the width of proximal tooth surfaces, and (c) the course of the CEJ's.<sup>[13]</sup> Thus in anterior regions of the dentition, the interdental papilla assumes a pyramidal or conical shape. In the premolar/molar region, the apex of the papilla is separated by a concavity known as the 'col'. It is the only non-keratinized portion of the gingival and is most susceptible to trauma.

### The effect of distance from the contact point to the crest of the bone on the presence or absence of the interproximal papilla

Tarnow *et al.*<sup>[4,14]</sup> examined 288 interproximal sites in about 30 patients who underwent scaling and root planning 2-8 weeks prior to the examination. The presence or absence of the papilla was determined

visually prior to probing. At the time of surgery, patient was anesthetized and the probe was inserted vertically on the facial aspect of the contact point until the crest of the bone was sounded. Following were the results:

They concluded that when the distance from the base of the contact point to the crest of the bone was 3, 4, or 5 mm: papilla was almost present; when it was 6 mm: Papilla was present a little more than half of the time and when the distance was 7, 8, 9, or 10 mm: papilla was missing most of the times.

### Classification for loss of interdental papilla

Nordland and Tarnow proposed a system of

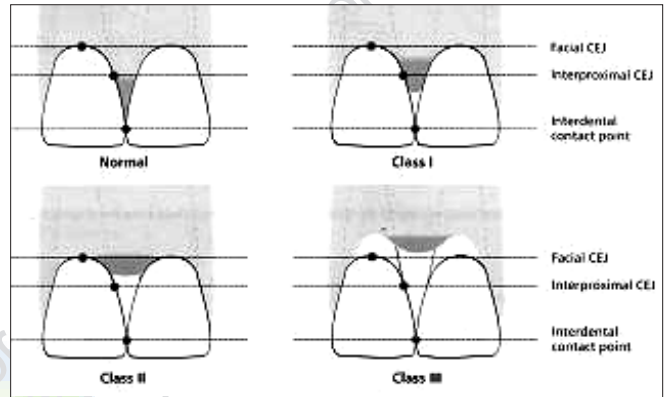


Figure 1: Schematic drawing illustrating the classification system for the loss of interdental papilla

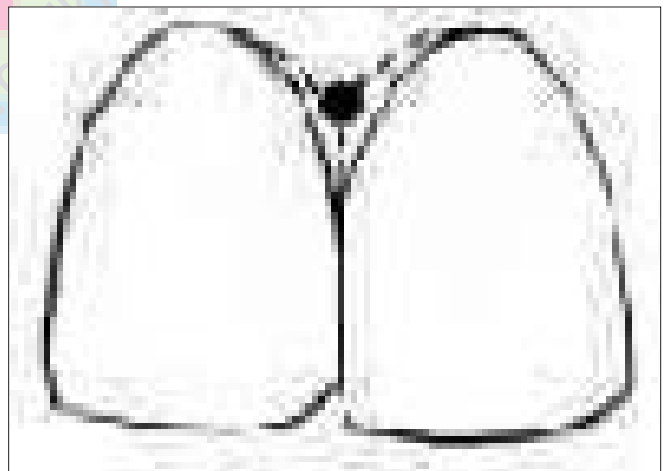


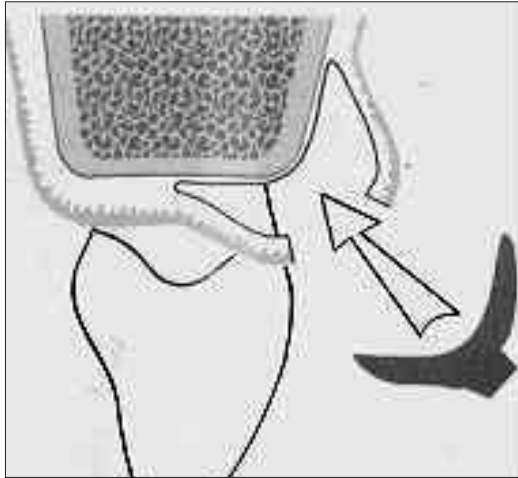
Figure 2: Schematic drawing illustrating the relationship between the contact point and the interdental space

Table 1: The effect of distance from the contact point to the crest of the bone on the presence or absence of the interproximal papilla

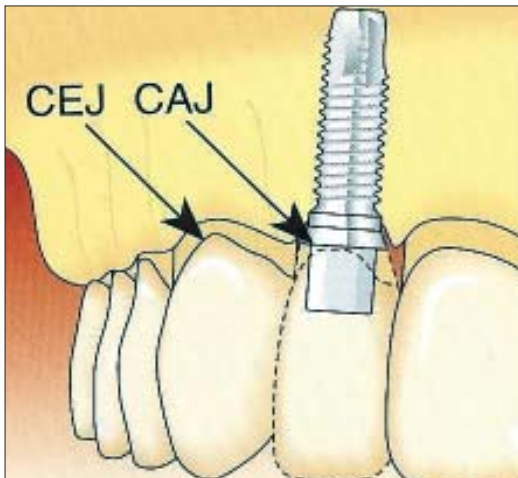
	Distance in mm from contact point to crest of bone							
	3	4	5	6	7	8	9	10
Papilla present	(2)	(11)	(73)	(112)	(63)	(21)	(4)	(2)
Papilla not present	2	11	72	63	12	2	1	0
% present	100	100	98	56	27	10	25	0
% not present	0	0	02	44	73	90	75	100

classification for the loss of interdental papilla.<sup>[8]</sup> It utilizes the following identifiable anatomic landmarks:

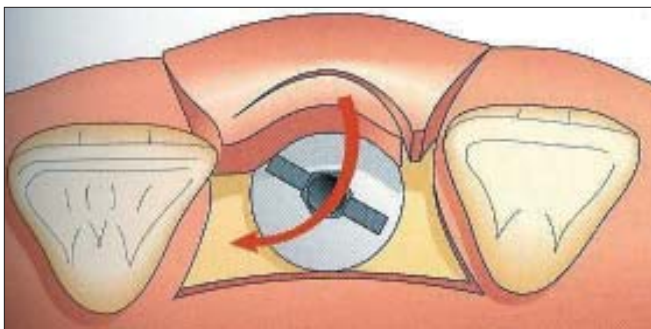
1. Interdental contact point.
2. The facial apical extent of the CEJ.



**Figure 3:** Schematic drawing illustrating a connective tissue graft placed under the flaps in the interdental area



**Figure 4:** Schematic drawing illustrating ideal implant positioning where neighbouring teeth exhibit normal periodontal support. The cemento-enamel junction of the adjacent teeth should more or less coincide with the crown-abutment junction of the implant



**Figure 5:** Schematic drawing illustrating the first semilunar bevel incision made from distal to mesial and the 90 degree rotation of the flap to occupy the interdental space

3. The interproximal coronal extent of the CEJ.

Four categories were identified [Figure 1]:

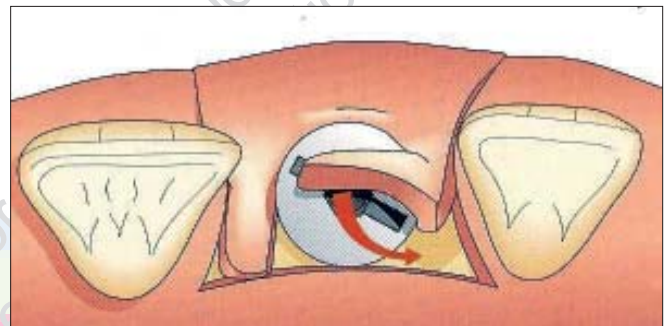**Normal:** Interdental papilla fills embrasure space to the apical extent of the interdental contact point/area.

**Class I:** The tip of the interdental papilla lies between the interdental contact point and the most coronal extent of the CEJ. (Space present but CEJ not visible).

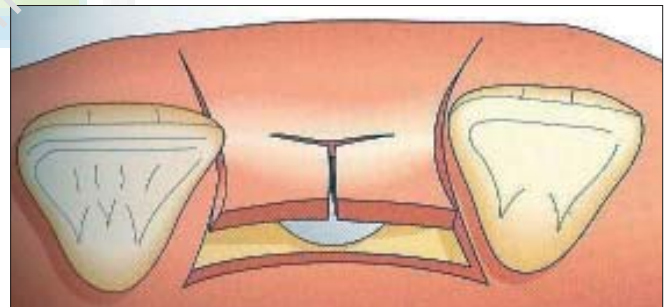
**Class II:** The tip of the interdental papilla lies at/or the apical to the interproximal CEJ but coronal to the apical extent of facial CEJ [Figure 2]. (Interproximal CEJ visible)

**Class III:** The tip of the interdental papilla lies level with or apical to the facial CEJ.

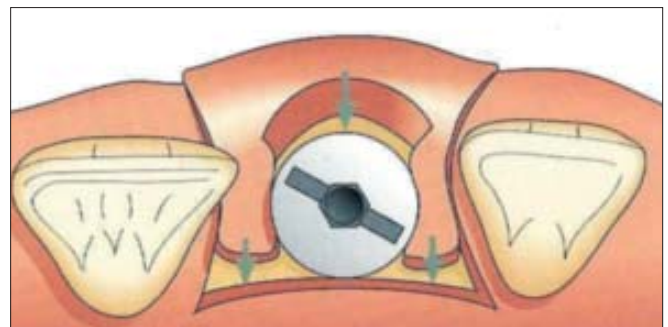
In addition to the use of this basic classification, additional descriptions could be linked and used as supplements. For example, if there is a 2 mm height of




**Figure 6:** Schematic drawing illustrating the second semilunar bevel incision made from mesial to distal and the 90° rotation of the flap to occupy the interdental space



**Figure 7:** Schematic drawing illustrating a T-shaped incision made to expose the abutment screw



**Figure 8:** Schematic drawing illustrating the flaps made to slide laterally after the T-shaped incision in order to occupy the interdental space



**Figure 9:** Schematic drawing illustrating the relationship of ovate pontic and interdental papilla

black triangle beneath the contact point, the situation could be described as Class I-II.

Bone levels and interdental space width can be measured radiographically and to the basic system.

### Loss of interdental papilla

The absence or loss of interdental papillae can be due to several reasons, viz.

- Plaque associated lesions
- Traumatic oral hygiene procedures
- Abnormal tooth shape
- Improper contours of the restoration
- Spacing between teeth
- Loss of teeth, etc.

### Treatment modalities

It is said that 'Soft tissue always follows the hard tissue.' This is undoubtedly evident in active periodontal disease where bone loss leads to loss/absence of the interdental papilla. In such cases, complete reconstruction is generally not achieved. However, if the damage is mainly due to soft tissue alone reconstructive techniques may be useful in restoring the papilla completely.

Interdental papilla may be restored either by Non-Surgical approach or surgical approach.

### Non-surgical approach

#### Correction of oral hygiene

Poor oral hygiene is one of the leading causes for periodontal disease. Maintenance of proper oral hygiene (use of interdental cleaning aids, chemical plaque control along with tooth brushing) may help prevent the apical migration of the interdental papilla. However, traumatic oral hygiene procedures must be identified, temporarily discontinued, and eventually modified as they may cause damage to the interdental tissue especially in the posterior region. Re-epitheliasation

of the traumatic lesion can restore the papilla completely.<sup>[3]</sup>

#### Restorative/prosthetic restorations

In cases of incisors with an incisal edge much wider than its cervical third, the contact point is located coronally. In such a situation, the cervical pyramid of the interdental space is increased and the papilla does not fill the space completely. The same happens with improper contours of restoration. Improper restorations may also cause trauma and damage to the papilla. By restorative/prosthetic therapy, the contact point can be lengthened and located more apically; the embrasure is reduced, allowing coronal displacement of the interdental gingival.<sup>[7,9,10]</sup>

#### Orthodontic approach

It is indicated in diastemas or spacing due to loss of teeth. In such cases the contact point is missing. Also the gingiva is firmly bound over the underlying bone.<sup>[15]</sup> The aim of the treatment is to create a contact point by bodily movement of teeth. Tipping again will lead to mesiodistal divergence of the roots and coronal location of the contact point. If a diastema is due to periodontal disease orthodontic closure should be performed after the resolution of the inflammation.<sup>[7]</sup>

#### Repeated curettage of the papilla<sup>[1]</sup>

Repeated scaling/ root planning and curettage of the papillary tissue every 15 days for 3 months may induce a proliferative hyperplastic inflammatory reaction of the papilla. This technique was used to reconstruct papillae destroyed by necrotizing gingivitis. The response to such treatment is unpredictable.

### Surgical approach

Surgical techniques may be used to recontour, preserve or reconstruct the interdental papilla.

#### Recontouring of the papilla

Recontouring the papilla may be required in cases of gingival enlargement or in cases of localized gingival lesions, viz. peripheral giant cell granuloma. In such cases, excess soft tissue is eliminated by gingivectomy associated with a free gingival graft in order to remodel the soft tissue architecture.

#### Papilla preservation

Periodontal defects may be corrected by various flap procedures. In order to preserve the interdental soft tissues for maximum soft tissue coverage following surgical intervention in the treatment of proximal osseous defects, Takei *et al.* in 1985 proposed a new flap technique called the papilla preservation technique.<sup>[2,16]</sup> According to the description, the technique is initiated by an intrasulcular incision at the facial and proximal aspects of the teeth without making an incision through the interdental papillae. Subsequently, an intrasulcular incision is made along the lingual/palatal aspect of the teeth with a semi lunar incision across each of the papilla.

The semi lunar incision should dip apically at least 5 mm from the line angles of the teeth, which will allow the interdental tissue to be dissected from the lingual/palatal aspect so that it can be elevated intact with the facial flap. In situations where an osseous defect has a wide extension into the lingual/palatal area, the semilunar incision may be placed on the facial aspect to have the papilla included with the lingual/palatal flap.

After the bone defect has been corrected, the flap including the palatal/lingual aspect of the papilla is repositioned and is sutured using a cross mattress suture or direct sutures over the semilunar incision.

To optimize clinical results in terms of attachment/bone gains and soft tissue preservation, Cortellini *et al* published a modification of Takei's technique termed as the modified papilla preservation technique<sup>[5]</sup> and simplified papilla preservation technique.<sup>[6]</sup>

Modified papilla preservation technique is used in wider interdental spaces (>2 mm) especially in the anterior region. A horizontal incision is performed at the base of the papilla and a full thickness palatal flap is raised. Vertical releasing incisions or periosteal incisions may be given to relieve the tension of the flap. A barrier membrane is positioned to cover the defect. A horizontal internal mattress suture,<sup>[17]</sup> which relieves all the tension of the flap, is placed beneath the mucoperiosteal flap and a second vertical internal mattress suture is placed between the buccal aspect of the interproximal papilla and the most coronal portion of the buccal flap to ensure primary closure. 75% success was achieved using this technique.

Cortellini and Tonetti further improved the results by using a microsurgical approach.<sup>[11]</sup> Surgeries were performed with the aid of an operating microscope at a magnification of 4-16 $\times$ . Microsurgical instruments and blades were utilized for the procedure. 5-0 ePTFE sutures were placed to release the tension of the flaps while 6-0 or 7-0 ePTFE sutures were placed to obtain primary closure. The advantages include improved illumination, access, and magnification of the surgical field. Dissection is extremely accurate; defect debridement is perfected, superb control over membrane positioning and stabilization is achieved and primary closure is best obtained.

#### *Reconstruction of the Interdental papilla*

Before attempts are made to surgically reconstruct the papilla, it is important to assess both the vertical distance between the crest of the bone and the apical point of contact between the crowns; and the soft tissue height of the interdental area. If the distance between the crest of the bone and contact point is  $\leq 5$  mm and the papilla is less than 4 mm, surgical intervention for increasing the volume of the papilla could be justified in order to solve the problem of an interdental black triangle. However, if the contact point is located at a

distance >5 mm from the crest of the bone because of loss of periodontal support and/or inappropriate interdental contact relationship between the crowns, means to apically lengthen the contact area should be selected rather than a surgical attempt to improve the topography of the papilla. Till date, various procedures have been described to reconstruct the papilla. Beagle, in 1992, described pedicle graft utilizing the soft tissues palatal to the interdental papilla.<sup>[15]</sup> Han and Takei, in 1996, proposed the 'semilunar coronally positioned papilla'<sup>[14]</sup> based on the use of free connective tissue graft. The most commonly and widely used technique is the one proposed by Azzi *et al.*<sup>[18]</sup> in 1998. It also involved the use of a connective tissue graft.

An Intrasulcular incision is made on the tooth surfaces facing the interdental area to be reconstructed. Subsequently an incision is placed across the facial aspect of the interdental area and an envelope type of split thickness flap is elevated into the proximal site as well as apically to a level beyond the mucogingival line. A connective tissue graft is harvested from the tuberosity area, trimmed to the adequate size and shape, and placed under the flaps in the interdental papilla area [Figure 3]. The flaps are brought together and sutured with the connective tissue graft underneath the connective tissue and the coronal displacement of the flap allows for simultaneous treatment of both recession and missing papilla.

## **REGENERATING INTERDENTAL PAPILLA AROUND MISSING TEETH**

### **ROLE OF IMPLANTS**

Recreating the scalloped architecture of the papilla is a very challenging task in implantology. A sound knowledge of correct implant positioning and various regenerative procedures is required for a successful esthetic outcome. Following factors should be kept in mind:

#### **Implant positioning<sup>[13]</sup>**

The crown abutment junction (CAJ) of the implant-supported restoration should more or less coincide with the apical extension of the CEJ of the neighboring teeth [Figure 4]. In cases where neighboring teeth exhibit reduced periodontal support, the CAJ of the implant-supported restoration should be more deeply placed, i.e., approximately 3 mm from the CEJ. In terms of mesiodistal positioning of the same, the distance between the centers of the neighboring teeth and the implant should be around 7-8 mm. Optimal positioning in the mesiodistal direction facilitates the establishment of a proper contact point. In terms of buccolingual positioning, the implant should be placed 1 mm within the buccal bone to obtain the normal architecture of

the interdental soft tissues.

### Considerations during stage ii surgery<sup>[13]</sup>

Papilla regeneration procedures are performed at the second stage surgery. Firstly, the cover screws are identified using a probe tip. Following this, a horizontal incision is made at the palatal aspect of the cover screws and the vertical releasing incisions made in the buccal direction. A semilunar bevel incision is made from distal to mesial and the pedicle so raised is rotated 90° [Figure 5]. Once the first pedicle is in place, the second semilunar incision is made from mesial to distal. The pedicle is then rotated 90° to fill the space between the abutment and the distal tooth [Figure 6]. In some situations, a T-shaped incision can be made and both sides of the flap can slide laterally to fill up the spaces between the abutment and the adjacent teeth [Figures 7 and 8]. Healing abutments or Gingiva formers are placed the flap is sutured. The first suture is placed labially at the level of releasing incision and then a mattress suture is made starting buccally and running to the palatal aspect and back. One can expect an optimal result 4-6 months later in terms of form texture and color. The apparent simplicity of this technique, however, should not mask its sensitivity; for this technique requires expertise as it is prone to failure because of tension and ischemy. Narrower healing abutments may improve the success rate.<sup>[13,17-19]</sup>

### Role of ovate pontics<sup>[20]</sup>

In cases of crowns and bridges in anterior teeth, recreating the scalloped architecture of the interdental soft tissues is again challenging. It can be done by surgical recontouring of the firmly bound gingiva followed by placement of ovate pontics with the support of adjacent teeth. This support may be in the form of a three-unit bridge of a partial coverage crown for the abutment teeth. When an ovate pontic is used the distance between the crest of the ridge and the contact point can be about 7 mm. The ovate pontic also provides an excellent emergence profile and also aids in the regeneration of the interdental papilla.<sup>[20]</sup>

### CONCLUSION

Black triangles, at the cervical end of crowns and bridges often result in reduced patient acceptance of the restoration that fit and function well. Although various treatment modalities have been proposed to restore the absent interdental papilla, the predictability and long-term stability of these procedures have not been documented. The clinician should not overlook the esthetic importance of the interdental papilla and proper measures should be initiated with respect to the same in order to optimize clinical results.

### REFERENCES

1. Shapiro A. Regeneration of interdental papilla using periodic curettage. *Int J Periodontics Restorative Dent* 1985;5:27-33.
2. Takei HH, Han TJ, Carranza FA Jr, Kenney EB, Lekovic V. Flap technique for periodontal bone implants. Papilla preservation technique. *J Periodontol* 1985;56:204-10.
3. Audigo G, Pini Prato GP, Nevins M, Cortellini P, Ono Y. Aesthetic modifications in periodontal therapy. *Int J Periodontics Restorative Dent* 1989;9:288-99.
4. Tarnow DP, Magner AW, Fletcher P. The effect of the distance from the contact point to the crest of bone on the presence or absence of the interproximal papilla. *J Periodontol* 1992;63:995-6.
5. Cortellini P, Prato GP, Tonetti MS. The modified papilla preservation technique. A new surgical approach for interproximal regeneration procedures. *J Periodontol* 1995;66:261-6.
6. Cortellini P, Prato GP, Tonetti MS. The simplified papilla preservation Flap. A novel surgical approach for the management of soft tissues in regenerative procedures. *Int J Periodontics Restorative Dent* 1999;19:589-99.
7. Kokich VG. Esthetics: The orthodontic-periodontic restorative connection. *Semin Orthod* 1996;2:21-30.
8. Nordland WP, Tarnow DP. A classification system for loss of papillary height. *J Periodontol* 1998;69:1124-6.
9. Blatz MB, Hurzeler MB, Strub JR. Reconstruction of the lost interproximal papilla-Presentation of Surgical and non-surgical approaches. *Int J Periodontics Restorative Dent* 1999;19:395-406.
10. Han TJ, Takei HH. Progress in gingival papilla reconstruction. *Periodontol* 1996;11:65-8.
11. Cortellini P, Tonetti MS. Microsurgical approach to periodontal regeneration. Initial evaluation in a case cohort. *J Periodontol* 2001;72:559-69.
12. Bresson G, Romerowski J. Pleading for too often neglected discipline. Dental anatomy, various interesting aspects in current practice. *Rev Odontostomatol* 1978;7:47-56.
13. Esthetic Implant Dentistry-Soft and Hard Tissue Management: Patrick Palacci, Ingvar Ericsson.
14. Jan Lindhe-Clinical Periodontology and Implant Dentistry.
15. Beagle JR. Surgical reconstruction of the interdental papilla: Case report. *Int J Periodontics Restorative Dent* 1992;12:144-51.
16. Carranza's Textbook on Clinical Periodontology.
17. Tinti C, Parma Benfenati S. A new suturing technique combined with a surgical approach to obtain papillae between implants in the bucca area. *Int J Periodontics Restorative Dent* 2002;22:63-9.
18. Palacci P. Peri-implant soft tissue management. Papilla regeneration technique. *In: Palacci P, Ericsson I, Engstrand P, Rangert P, editors. Optimal Implant positioning and soft tissue management for the Brånemark system. Quintessence: Chicago; 1995. p. 59-70.*
19. Jemt T. Regeneration of gingival papillae after single implant treatment. *Int J Periodontics Restorative Dent* 1997;17:326-33.
20. Contemporary Fixed Prosthodontics: Rosensteil, Land and Fujimoto.

Source of Support: Nil, Conflict of Interest: None declared.