

Case Report

A close-up on obturators using magnets: Part II

Vinaya Bhat

Department of Maxillofacial Prosthodontics, Sree Balaji Dental College and Hospital (Deemed University), Chennai

For correspondence

Vinaya Bhat, Department of Maxillofacial Prosthodontics, Sree Balaji Dental College and Hospital (Deemed University), Narayanapuram, Pallikaranai, Chennai - 601 302, Tamil Nadu, India. E-mail:vinayabhat@hotmail.com

Part I of this article presented an exhaustive collection of data about magnets used in Dentistry. Large maxillectomy defects have been restored with multiple segment prostheses retained with the help of magnets. When prosthesis comprises of several components, it is easy to incorporate other features, which would increase the success rate of the treatment. This clinical case report deals with rehabilitation of a patient with an extensive maxillary defect using a 2-segment obturator retained with magnets. The additional features being that, the bulb is fabricated as a closed, single piece structure processed with heat-polymerized acrylic resin unlike most other obturators.

Key words: 2-component obturator, closed, heat-polymerized, hollow bulb, magnet, single piece

INTRODUCTION

Part I of the series described in detail, the uses of magnets in dentistry, their classification, history, advantages, disadvantages and their biological effects on tissues. Present article explains a method of rehabilitating a patient with large maxillary defect using a two-component obturator retained with the help of magnets. The other special features of this prosthesis are that, the bulb occupying the defect has the combined advantages of a single-piece closed hollow structure that has been fabricated with heat polymerized acrylic resin.

CASE REPORT

History

A Male patient aged 45 years reported with chief complaints of inability to eat due to nasal reflux of food. He also complained of hyper nasal speech. He gave a history of surgery carried out on the left half of his face for a tumor around 3 months ago. He indicated that he was on radiation therapy once every week after surgery for nearly 7 weeks.

Examination

On extraoral examination, the left cheek area was found to be depressed and the left half of the upper lip collapsed. A surgical scar was observed in the midline

of the upper lip, which extended along the lateral border of the nose till the outer canthus of the left eye.

During temporomandibular joint examination, the left condyle moved very little when the patient opened the mouth. The inter-incisal mouth opening was measured to be only 19 mm.

Intraoral examination revealed presence of all the teeth in the mouth and teeth from right lateral incisor to second molar on the unresected side of the maxilla. The surgical defect appeared extensive. As the patient had trismus, it was found to be difficult to examine the defect. Considering this situation, the patient was immediately placed on an exercise regimen using a stack of soft wood sticks. Several sticks were placed between the occlusal surfaces as posteriorly as possible on the non-defect side. The number was steadily increased to maximum tolerable limit. Later, a mouth gag (Bite Opener) was given with instructions to use it as frequently as possible.

Once the access was established, the ghastly extent of the defect was apparent.

Superiorly, it extended almost to the floor of the orbit, mesially to the nasal septum and laterally, the entire buccal aspect. Posteriorly the distal one-third of the soft palate was found to be intact on the defect side [Figure 1].

Treatment procedures

Treatment was carried out in four phases as follows:

Phase I: Impressions

As explained earlier, this phase involves the exercise regimen to obtain sufficient mouth opening for clinical

Presented at the 33rd Indian Prosthodontic Society Conference, Aurangabad, 2005

procedures and later, the insertion of the prosthesis. It usually is an ongoing process throughout the treatment or even further.

When satisfactory amount of mouth opening was achieved, preliminary and secondary impressions were made with the help of irreversible hydrocolloid. Extreme care was taken to prevent ingestion of the material by the patient during the procedures. Secondary impression was beaded, boxed and poured in die stone [Figure 2]. Further, it was duplicated to obtain a working cast [Figure 3].

Phase II

Sculpting the *Bulb portion* of the two-component prosthesis. This was done in two steps. First, a thin SHIM was fabricated. It was later encapsulated in heat-polymerized acrylic resin to complete the bulb. The minor undercuts in the defect were blocked out using modeling wax. Next, the entire defect area was lined with a layer of wax. A mixture of 50% pumice and 50% dental stone was prepared and poured onto the well in the center of the defect almost to the level of the remaining palate. It was contoured to the shape of the palate on the non-defect side. Mixture was allowed to set [Figure 4]. Later it was concealed by adapting another layer of modeling wax to the level of the palate. Wax adjacent to the midline was carved to create an undercut, which will be engaged by resin of the palatal portion for added retention.

The entire assembly was flaked and dewaxed, simultaneously eliminating the pumice: stone mix to create a mold. This mold was lined with a layer of base-plate wax both on the counter portion and the base of the flask. Three stops deep enough to reach the underlying stone were carved on the wax overlying the defect and two on the base of the flask. These stops will stabilize the shim while processing the bulb during its completion. All the stops were filled with autopolymerizing acrylic resin polymer and monomer using sprinkle-on method [Figure 5]. Then more resin was mixed and the dough was adapted over the wax, both in the counter portion and the base of the flask. Flask was closed and resin was allowed to polymerize for 30 minutes. Then, the flask was opened. Dewaxing was done. This leaves the shim on its stops with a uniform layer of space all around. The shim was retrieved from the defect, excess resin trimmed and it was placed in the defect [Figure 6].

Now, heat-polymerized acrylic resin was mixed and a small amount of dough was pressed onto the bottom of the defect. The finished shim was replaced with the stops accurately positioned. More acrylic was placed on the base of the flask and it was closed. Here, clear acrylic resin has been used to distinguish between the shim and the outer layer of the bulb. The heat-cure acrylic was polymerized in the prescribed technique.

After polymerization, the flask was opened to retrieve the bulb. It was trimmed and polished to smoothen the surface [Figure 7].

After the satisfactory try-in of the completed bulb in the defect, its tissue surface was loaded with soft liner. With the bulb in position in the defect, the patient's head was flexed and neck rotations were performed to record the movements of the residual musculature of the pharynx [Figure 8].

A rare earth magnet system was selected and the ferromagnetic keeper of the system was embedded on the surface of the bulb facing the oral cavity [Figure 9].

Phase III

Fabrication of the *palatal portion* of the two-component prosthesis. With the completed bulb in position, another impression of the maxilla was made with irreversible hydrocolloid [Figure 10]. Cast was poured and jaw relations were recorded. Esthetic try-in was performed. It was then processed in heat-polymerized acrylic resin [Figure 11].

This portion houses the teeth for esthetics and it extends posteriorly to the residual velopharyngeal musculature to achieve closure during speech and deglutition. The retention for this portion is by the wrought wire clasps engaging the buccal undercuts of the remaining teeth on the maxilla.

Next, in the area corresponding to the keeper in the bulb, the magnet was embedded on the tissue side of the palatal portion [Figure 12]. It was then placed in the oral cavity with retentive elements in position and the magnetic system accurately juxtaposed to each other on the defect side.

Patient was extremely happy with the masticatory efficiency and the improved quality of speech instantaneously. Necessary instructions were given on technique of placement, removal and maintenance of the prosthesis [Figure 13].

Phase IV

Review visits were arranged for finer adjustments of the prosthesis. As the tissues of the defect undergo rapid changes, the patient would be recalled on a fortnightly basis for evaluation and necessary adjustments in the bulb portion.

DISCUSSION

Surgical resection of the maxillae results in a communication between the oral and nasal cavities that causes difficulty in swallowing, nasal reflux, unintelligible speech and unesthetic appearance. Along with these difficulties, it can also be psychologically debilitating to a patient. In addition, when the defect is large and associated with trismus, the complications of treatment procedure are exaggerated.

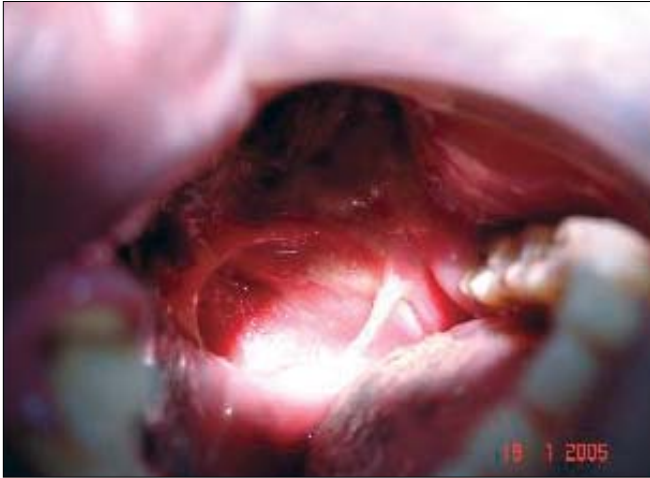

Figure 1: Maxillary defect

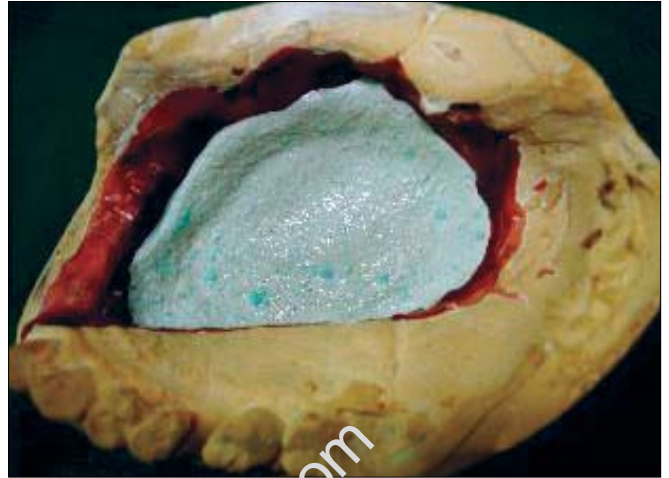


Figure 4: Pumice and stone mix

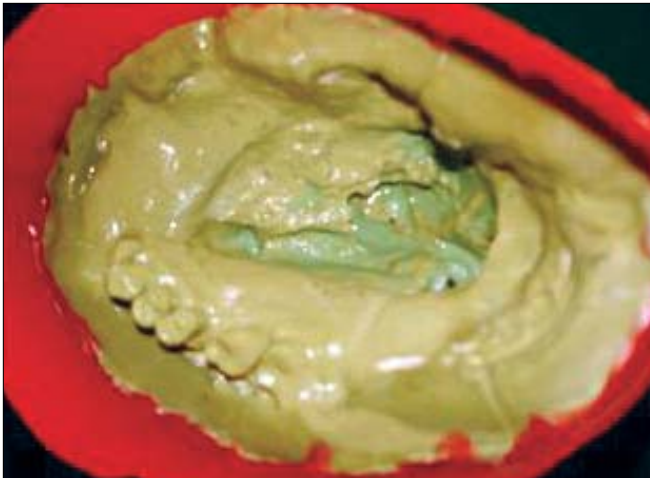

Figure 2: Master cast ready for duplication

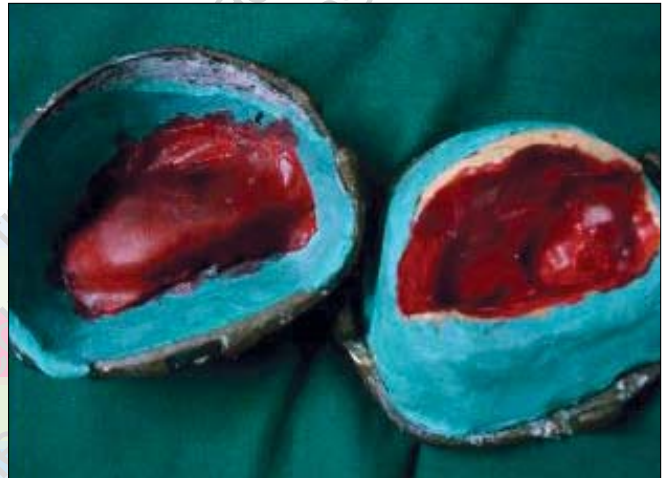

Figure 5: Lined cast with stops filled



Figure 3: Duplication

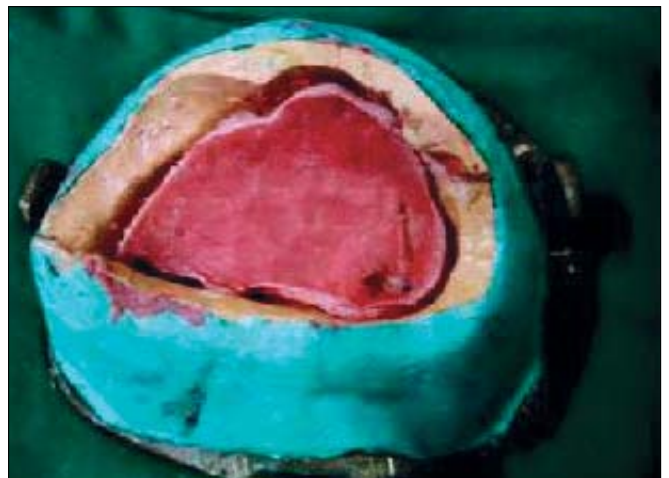

Figure 6: SHIM replaced

It is the responsibility of a Prosthodontist to restore the lost esthetics, function and speech to normal or very near normal. While we strive to achieve the above,

it has to be borne in mind that the proposed prosthesis should be simple to handle, easy to maintain, be light in weight and be convenient for future adjustments.

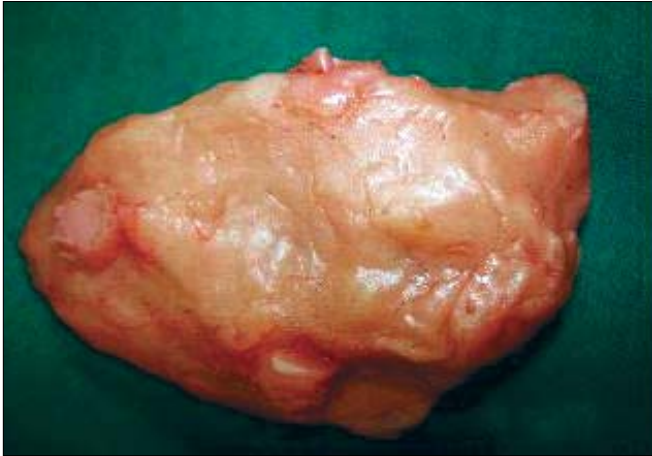

Figure 7: Completed SHIM

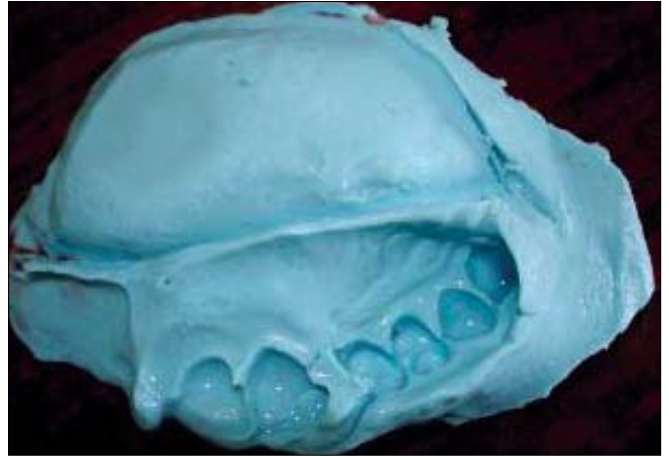


Figure 10: Impression for palatal segment

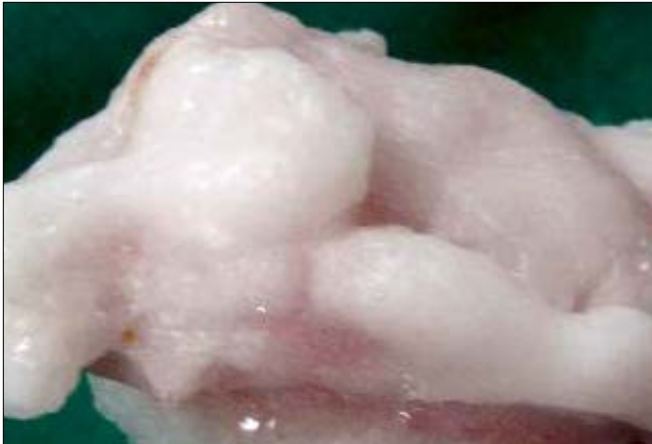


Figure 8: Molded soft liner

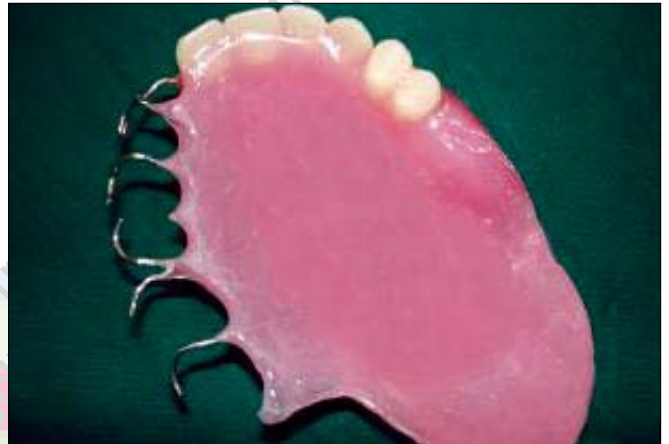

Figure 11: Cameo surface-palatal segment

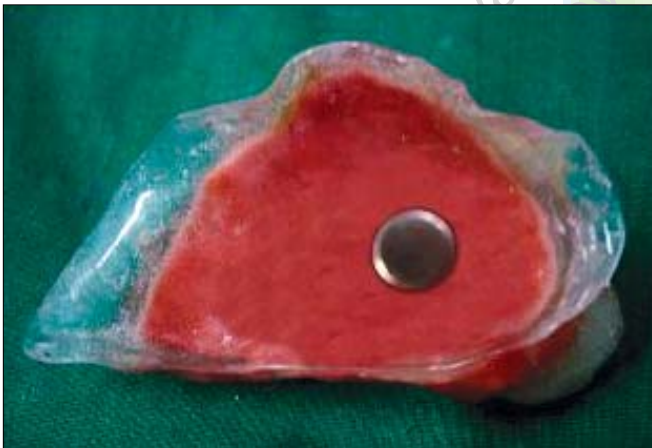

Figure 9: Completed bulb with magnetic keeper

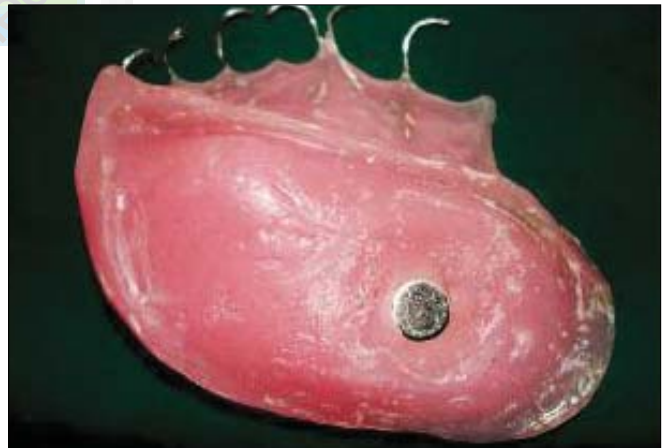

Figure 12: Intaglio surface-with magnet

Trismus is almost always present when the patients are irradiated for tumors extending to the pharyngeal region making execution of the procedures extremely cumbersome. And for the patient, manipulation of the prosthesis into and out of the mouth becomes a Herculean task, as it requires multiple paths of insertion and removal. Hence, an atypical mode of rehabilitating such patients is warranted.

Multiple-component prostheses have been advised



Figure 13: Patient, before and after

to rehabilitate patients with severe trismus. A two-component prosthesis retained by magnets facilitates its easy placement and removal, in two separate actions. Manipulation of the prosthesis is made simpler by breaking down the compound paths of insertion and removal.

The prosthesis being located in the maxilla, its retention is affected by naturally existing gravitational forces acting on it. Constant pull applied on the prosthesis by the gravity also has been found to have ill effect on the remaining natural teeth, which support the prosthesis. A lightweight prosthesis will not only combat this problem but it also will enhance the resonance of speech.

In 1983, Lauciello *et al.*^[1] suggested fabrication of flexible obturator for patients with severely limited mouth opening using either silicone or even a flexible vinyl resin mouth guard material. However, they also cautioned that these materials are far from ideal and in an average maxillectomy case it would be inadequate. In 1990, Boris Schwartzman *et al.*^[2] conducted a photoelastic study of various retainer designs for definitive obturators and their effect on natural teeth during gravitational forces on the prosthesis. They concluded that since the force of gravity is always active on a maxillary prosthesis, the design of an obturator should minimize its weight. Or else, it would induce detrimental effects on the remaining teeth, which are engaged by retentive parts of the obturator.

In the past, a hollow bulb obturator has been suggested by many a researchers to reduce the weight of the prosthesis. In the year 2000, Taylor^[3] insisted that obturator for a large defect should be routinely made hollow to reduce the weight. But leaving it open at the top may create difficulty for the patient in its maintenance. He advises placing a lid on the superior surface. Any weight created by the lid is offset by the hollow space of the obturator. He fabricated the lid with Triad acrylic resin as a separate laboratory procedure.

Various laboratory techniques that minimize weight by creating a hollow obturator have been reported so far. Tanaka *et al.*^[4] in 1977 simplified the fabrication process for a lightweight obturator. They felt that using polyurethane foam as core to reduce the weight of the obturator would be efficient and economical. They observed that it reduced the weight by ten-fold as compared to a solid acrylic resin core. It was found that use of polyurethane core also increased the strength and facilitated repair as compared with a hollow obturator.

Parel and LaFuente^[5] in 1978 formed a hollow prosthesis in a single visit. First, a resilient liner material was adapted to the defect on all surfaces except at the palatal side. This was then filled with sugar to the level of the palate. Autopolymerizing resin was used

to form the lid for the palatal side. Sugar was drained later through a small bur hole on the lid, which was sealed with more autopolymerizing resin.

Beder and Todo^[6] in 1978 explained yet another rapid technique for constructing a hollow bulb. They used hollow plastic forms of different shapes and sizes, which were modified according to the requirements. They were enclosed in autopolymerized resin to form the walls of the defect.

In the year 1985, Phankosol and Martin^[7] developed a technique of constructing a hollow obturator with a removable lid combining the benefit of both closed and open hollow obturators. They suggested that a closed obturator is needed to prevent collection of nasal secretion and food. Where as an open-top would reduce the weight of the obturator and it will be easy for the patient to maintain the hygiene of the obturator. Their technique used a vacuum-formed mouth guard material to form the lid. It can be removed and cleaned by the patient as well without assistance.

In 1969 Mahdy^[8] described a method of processing a hollow obturator using two identical flasks with interchangeable parts. According to the author, the main advantage of this technique was that the thickness of the base and the weight of the prosthesis could be controlled. Maintenance of accuracy and easy technique are the other advantages.

Light weight has also been considered for maxillary resection prosthesis, by Chalian and Barnett.^[9,10] In the year 1972, they explained a simple technique of fabricating a single-piece, hollow obturator prosthesis. It consisted of fabricating a cold-cured acrylic resin, which was entirely encapsulated in heat-polymerized resin in the second step of processing the obturator. This also helps in eliminating lines of demarcation, which will otherwise discolor the prosthesis. It is accurate and easy to carryout requiring only little more time than the conventional technique. Since the undercuts are blocked in the defect, these areas in the prosthesis become thicker which can be utilized for future adjustments if and when required.

In multiple segment prosthesis, since the fabrication is done in separate steps, incorporating other methods to increase efficiency could be thought of. For example, making the bulb hollow, would add on to enhancement of resonance of speech. It also has the advantage of making the prosthesis lighter thereby reducing the pull of gravity. This would enhance retention of this large maxillary prosthesis.

Also, the bulb could be fabricated as a single-piece closed structure unlike most of the obturators, which are open at the top or if closed, consisted of two parts. The lid, which is fabricated as a separate laboratory procedure, is usually sealed to the body of the bulb with autopolymerized resin. This leads to the presence of a line of demarcation, which could allow ingress of

fluids into the bulb causing its discoloration and making it unhygienic.

Being a small structure, the bulb could be fabricated entirely with heat-polymerized acrylic resin. Eventhough the surface that contacts the raw tissues is covered with soft liner, it is adviseable to make the bulb with a more biocompatible material than auto-polymerized resin. The unreacted monomer being less in heat-polymerized resin, risk of its leaching is also reduced.

The two components were retained with the help of rare earth magnets. Rare earth magnets have been used in dentistry as early as 1960s. In 1971, Javid^[11] used a coin-shaped magnet system to retain a facial prosthesis combined with complete dentures. Federick^[12] in the year 1976 presented a technique for the fabrication of a sectional interim maxillary obturator with retention augmented by a magnet. It has been estimated that dental magnets can provide about 300 g of standard magnetic retentive forces. Also, these forces are constant and they do not decrease with time and use.^[13]

SUMMARY

A case of hemi maxillectomy with large defect associated with trismus was successfully rehabilitated with the help of a hollow, two-component obturator that had a single piece closed bulb. The two components were retained with the help of magnets and the entire outer surface of the prosthesis was made of heat-polymerized acrylic resin.

Acquired diseases like carcinomas can cause tremendous effects on human beings like Psychological, functional and surgical. Restoring function, speech and esthetics is a challenging task when the defect presented is large. Treatment becomes even more difficult when the problem is associated with restricted mouth opening caused by radiation therapy.

Magnets have been in use in the field of Prosthodontics for long. Their use in such cases to fabricate a multi-component prosthesis is sure to hit the bull's eye in the success of rehabilitating the patient. Coated magnets have been found to withstand the corrosiveness of saliva and thus no ill effects on the oral tissues. Magnetism has been found to be constant during the

entire life of the magnet in use. Hence, a coated magnet may not require replacement as frequently as it is estimated, making it an important tool in treating such patients. Thus they can be used intraorally without the fear of causing toxicity. However, regular recalls and reviews will have to be arranged to ensure patency of the coated material. Chairside replacement of the damaged magnets down the line is easy and convenient, if required.

REFERENCES

1. Lauciello FR, Casey DM, Crowther DS. Flexible temporary obturators for patients with severely limited jaw opening. *J Prosthet Dent* 1983;49:523-6.
2. Schwartzman B, Caputo AA, Beumer J. Gravity-induced stresses by an obturator prosthesis. *JPD* 1990;64:466-8.
3. Taylor TD. *Clinical maxillofacial prosthetics*. Quintessence Publishing Co Inc: 2000. p. 100,18.
4. Tanaka Y, Gold HO, Pruzansky S. A simplified technique for fabricating a light weight obturator. *J Prosthet Dent* 1977;38:638-42.
5. Parel SM, LaFuente H. Single-visit hollow obturators for edentulous patients. *J Prosthet Dent* 1978;40:426-9.
6. Beder OE, Todo J. Rapid technique for constructing a hollow-bulb provisional obturator. *J Prosthet Dent* 1978;29:237-9.
7. Phankosol P, Martin JW. Hollow obturator with removable lid. *J Prosthet Dent* 1985;54:98-100.
8. el Mahdy AS. Processing a hollow Obturator. *J Prosthet Dent* 1969;22:682-6.
9. Chalian VA, Barnett MO. A new technique for constructing a one-piece hollow obturator after partial maxillectomy. *J Prosthet Dent* 1972;28:448-53.
10. Chalian VA, Drane JB, Standish M. *Maxillofacial Prosthetics: Multidisciplinary Practice*. The Williams and Wilkins Co: 1971. p. 133-48.
11. Javid N. The use of magnets in a maxillofacial prosthesis. *J Prosthet Dent* 1971;25:334-41.
12. Federick DR. A magnetically retained interim maxillary obturator. *J Prosthet Dent* 1976;36:671-5.
13. Bhat V. A close-up on obturators using magnets: Part I - magnets in dentistry. *J Indian Prosthodont Soc* 2005;5:114-8.

Source of Support: Self, **Conflict of Interest:** None declared.

Author Help: Choosing an appropriate category of article for faster publication

The manuscript system (www.journalonweb.com) allows the authors to check a likely publication date for a newly submitted article. Based on number of articles in review, number of accepted articles and acceptance rate, the system estimates the likely publication date for an article submitted on a given date.

If there are too many articles in a category e.g., case report, a newly submitted case report if accepted may have to wait for a long period before publication. Hence, the author can check other categories e.g. letter to editor or images, for such paper and submit to another category of articles.