

Case Report

Complete denture with hollow pharyngeal bulb prosthesis for rehabilitation of an edentulous cleft palate patient

Sandeep Kumar

Department of Prosthodontics and Maxillofacial Prosthetics, Manipal college of Dental Sciences, Manipal - 576 104, Karnataka, India

For correspondence

Sandeep Kumar, Department of Prosthodontics and Maxillofacial Prosthetics, Manipal college of Dental Sciences, Manipal - 576 104, Karnataka, India. E-mail: mdssandy@yahoo.co.uk

Velopharyngeal incompetence is the functional inability of the soft palate to effect complete seal with the posterior and/or lateral pharyngeal walls. Rehabilitation of velopharyngeal incompetence in cleft palate patients is challenging for both surgical and prosthetic fields. A prosthodontist can best contribute to the total care of the patient with cleft palate by participating all the phases of treatment from birth to the completion of growth. Here, a case report has been presented in which complete denture with a hollow pharyngeal bulb prosthesis has been used for rehabilitation of an edentulous patient having cleft of soft palate.

Key words: Cleft palate, hollow pharyngeal bulb prosthesis, palatal lift appliance, palatopharyngeal port, speech obturator, velopharyngeal incompetence

INTRODUCTION

The vicissitudes of morphogenesis expresses never so cruelly as in case of oro-facial clefts. Patients with cleft palate have many problems like, impaired articulation, problem in deglutition and seepage of nasal secretions into oral cavity. The complexity of these problems requires numerous health care professionals co-operating to provide the specialized knowledge and skill necessary for comprehensive care.

Interested, well-informed and resourceful dentists have made remarkable contributions toward fulfilling the communicative needs of cleft palate individuals. This has been accomplished by the construction and placement of prosthetic appliance. Basically, these prosthetic 'aids to speech' serve to obturate any opening or cleft of the palate and frequently carry an extension into the pharynx designed to improve or supplement velopharyngeal valving.

An understanding of normal velopharyngeal function and an appreciation of the consequences of abnormal function seem to be prerequisite to any meaningful discussion of data relating to cleft palate prosthesis.

In normal palatopharyngeal function, at rest the soft palate drapes from the posterior border of the hard palate, leaving an opening from the back of the oral cavity. During normal nasal breathing and humming with the mouth closed, the respiratory airflow and

vocalized sound are directed through this passage way. However, complete closure of the palatopharyngeal port is required for mouth breathing, for the production of normal oral (non-nasal) speech sounds or for other oral activities such as swallowing, blowing, sucking and whistling.^[1]

When impairment of the palatopharyngeal port is present, speech is typically characterized by excessive nasal resonance (hypernasality), inappropriate audible nasal air emission and a decrease in intraoral air pressure during the production of oral speech sounds.

Causes of velopharyngeal incompetence^[2]

- Cleft palate
- Traumatic injuries to neuromotor system and/or the peripheral efferent cranial nerves
- Cerebrovascular accidents
- Brain stem tumours and
- Neuromuscular diseases such as multiple sclerosis and cerebral palsy.

Treatment options

Treatment of velopharyngeal incompetence in patients with cleft palate includes surgical and prosthetic treatment. Surgical treatment is considered as permanent solution and should be preferred if conditions permit. Prosthetic treatment is considered as last resort and its use must be clearly indicated by oral conditions.^[3]

In 1958 Gibbon and Bloomer^[4] were the first to advocate

the use of palatal lift appliance (PLA) to treat paralytic dysarthria involving insufficient rhinopharyngeal closure. In cleft palate this PLA will not serve any purpose. In this case pharyngeal extension on the speech obturator can be used.

In this case report complete denture with hollow pharyngeal bulb prosthesis has been used for rehabilitation of an edentulous patient having cleft of soft palate.

CASE REPORT

A 58-year-old female patient came to the department of prosthodontics and maxillofacial prosthetics, Manipal College of Dental Sciences, Manipal with complaint of

messing teeth. Teeth were lost 28 years back due to periodontitis. No significant past medical history recorded and history of previous denture wears.

Intra-oral examination revealed completely edentulous upper and lower arches, cleft of soft palate (Veau's classification^[5] - group I) with velopharyngeal incompetence [Figure 1]. Nasal regurgitation and nasal in twang was observed.

Treatment planning

Surgical treatment option was eliminated considering age, systemic health and economic status of the patient. Prosthodontic treatment was decided with complete denture with hollow pharyngeal bulb prosthesis.

Procedure

Upper and lower perforated stock trays were selected. Upper tray was modified with wax extension into the defect to record the defect. Then upper and lower preliminary impressions were made with irreversible

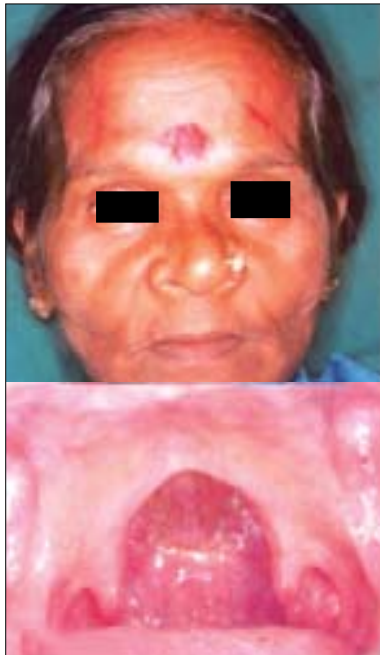

Figure 1: (Top) pre-operative frontal view, (bottom) intraoral view showing cleft of soft palate

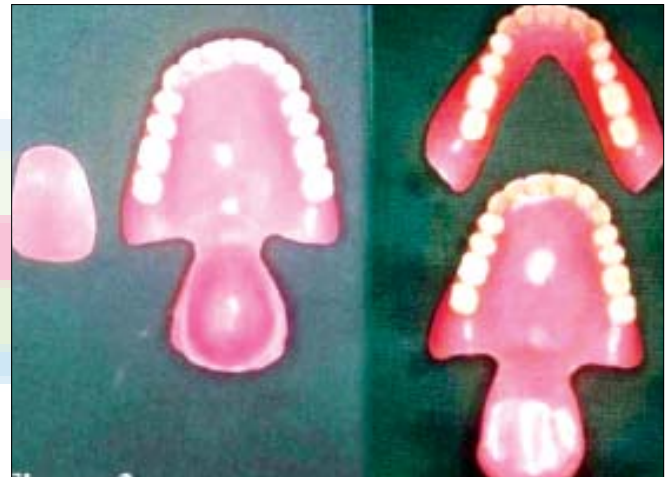

Figure 3: (Left) upper denture with hollow pharyngeal bulb and lid, (right) upper and lower finished dentures

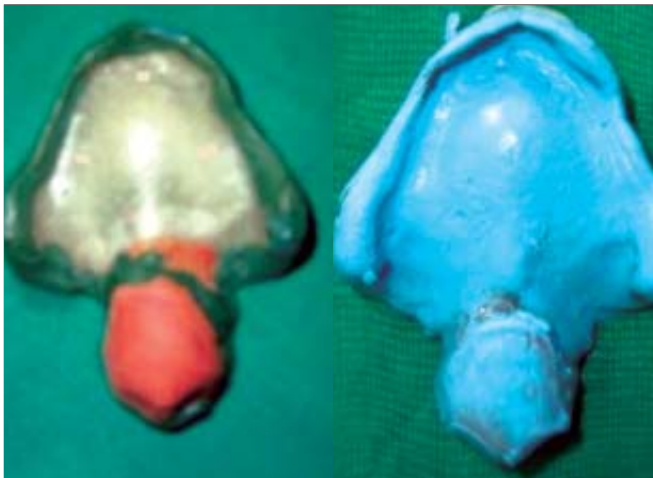


Figure 2: (Left) border molding, (right) final impression with medium body polyvinyl siloxane

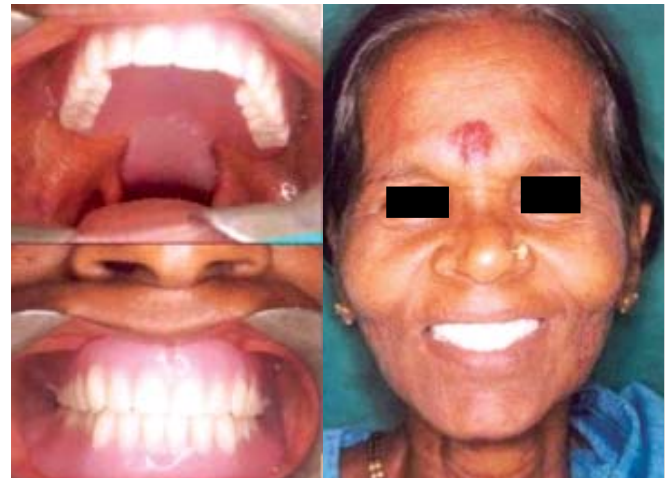

Figure 4: (Top left) intraoral view with prosthesis covering the defect, (bottom left) upper and lower dentures in occlusion, (right) postoperative frontal view

hydrocolloid. The upper impression also records the defect. Impressions were poured with dental stone to make diagnostic casts. Next step is the fabrication of special tray for border molding. Lower special tray is fabricated in conventional manner using autopolymerising acrylic resin. But during the fabrication of upper tray following factors were kept in mind.

Based on the fluoroscopic and nasoendoscopic studies.^[1]

- 1) There should be a 5 mm gap between the bulb and posterior pharyngeal wall.
- 2) Angle of the bulb should be approximately 20° relative to the palatal plane.
- 3) McKerns and Bzoch^[6] showed that in men the typical relation of the soft palate to the posterior pharyngeal wall is at a point above the palatal plane. For women contact is found to occur at or below the palatal plane.
- 4) Many dentists have attempted to approximate pharyngeal tissue overlying the anterior tubercle of the first cervical vertebra on the basis that this area was that of maximum constriction.

Keeping in mind all these criteria upper special tray was fabricated with autopolymerising acrylic resin having pharyngeal extension.

Border molding was accomplished by recording all the functional movements of the soft palate, i.e., by asking the patient to tilt her head side-to-side and front-back when sitting upright. Impression of the defect area was made with impression compound. Lower Border molding was done in conventional manner. Upper final impression was made with medium body polyvinyl siloxane [Figure 2] and lower with ZnOE. Beading and boxing was done and impressions were poured with die stone to fabricate master casts.

Autopolymerising acrylic resin record bases were made. In case of upper record base did not include the pharyngeal extension. Occlusal rims were made. Jaw relations and try in was done in accordance with conventional complete denture fabrication procedures.

After try in was over, all the undercuts of the defect area were blocked with wax. Flasking and dewaxing was done. Then dentures were processed with heat cure acrylic resin. Lid for the bulb was processed

separately with heat curing acrylic resin [Figure 3] and was attached to the completed denture with autopolymerising acrylic resin.

Upper and lower dentures were finished and polished. Patient was instructed in the use of the denture [Figures 3 and 4].

Patient found drastic improvement in speech and nasal regurgitation was reduced. Patient was advised to continue her referral to speech therapist.

CONCLUSION

The prosthetic correction of the cleft palate defects involves mixed emotions. A great tragedy occurs in the life of parents when a child with cleft palate born to them.

Unlike some of the discipline involved in the treatment of cleft palate patient, the prosthodontist have an application from birth to death. Prosthodontic care never ends. Once surgical care and speech therapy have been completed, the need for follow-up care is needed unless specific problems manifest. Preventive care is imperative if long-term preservation of the supporting structures is desired.

BIBLIOGRAPHY

1. Turner GE, Williams WN. Fluoroscopy and nasoendoscopy in designing palatal lift prostheses. *J Prosthet Dent* 1991;66:63-71.
2. Spratley MH, Chenerey HJ, Murdoch BE. A different design of palatal lift appliance: Review and case reports. *Aust Dent J* 1998;33:491-5.
3. Mazaheri M. Prosthetics in cleft palate treatment and research. *J Prosthet Dent* 1964;14:1146-58.
4. Gibbons P, Bloomer H. A supportive type prosthetic speech aid. *J Prosthet Dent* 1958;8:362-9.
5. Chalian VA, Drane JB, Standish SM. Maxillofacial prosthesis, Multidisciplinary practice. The Williams and Wilkins Company: 1972. p. 358-9.
6. McKerns D, Bzoch KR. Variations in velopharyngeal valving: The factors of sex. *Cleft Palate J* 1969;7:652-62.

Source of Support: Nil, **Conflict of Interest:** None declared.