

Case Report

Emergence profile customization technique during implant transfer

Paulo Henrique dos Santos, Thaís Yumi Umeda Suzuki¹, Ana Paula Martini, Bruna de Oliveira Reis², Wirley Gonçalves Assunção, Eduardo Passos Rocha

Departments of Dental Materials and Prosthodontics and ²Restorative Dentistry, Araçatuba School of Dentistry, Universidade Estadual Paulista - São Paulo State University, Araçatuba, São Paulo, ¹Department of Restorative Dentistry, Federal University of Minas Gerais, Belo Horizonte, Minas Gerais, Brazil

Abstract

This case report aimed to describe the clinical considerations in oral rehabilitation with prostheses on implants in the anterior region, using emergence profile customization technique during implant transfer. A patient presented with a missing left upper central incisor and with not satisfactory esthetic in the other upper incisors. After diagnosis, a treatment plan was elaborated: implant placement in this region; ceramic laminates for teeth 11 and 22, and full crown for tooth 12. During the impression procedure, the implant transfer was customized by copying the gingival profile. The prostheses were made using IPS e.max ceramic system and luted with resin cement. The patient was submitted to annual follow-up examinations that did not show any irregularity or deficiency in the prostheses. The technique performed is a viable alternative that can be used in oral rehabilitation with implants involving anterior teeth because it allows a predictable level of adaptation.

Keywords: Emergence profile, fixed prostheses, oral rehabilitation

Address for correspondence: Prof. Paulo Henrique dos Santos, Department of Dental Materials and Prosthodontics, UNESP - São Paulo State University, Araçatuba School of Dentistry, 1193 José Bonifácio St. Zip Code: 16015-050, Araçatuba, São Paulo, Brazil.
E-mail: paulosantos@foa.unesp.br

Received: 28th January, 2019, **Accepted:** 07th March, 2019

INTRODUCTION


Metal-free-fixed prostheses are increasing because of its esthetic superiority and satisfactory mechanical behavior that ensures longevity.^[1] Moreover, rehabilitations with dental implants require special care in areas with peculiar esthetic significance, as in single implants located in the anterior maxilla, where the surrounding soft tissue plays a prominent role in the restoration of esthetics.^[2]

Therefore, combination of fixed prostheses on implants and teeth in the anterior region still remains a challenge.^[3,4]

This case report describes a technique for copying the gingival profile of the patient in oral rehabilitation with prostheses on implants and fixed prostheses involving anterior region.

CASE REPORT

A 53-year-old female patient presented with a missing upper left central incisor. A 10.5 × 4.1 mm dental implant (S.I.N. Implant System, São Paulo, SP, Brazil) was installed, and a temporary crown, made of acrylic resin (Duralay-Polidental,

Access this article online	
Quick Response Code:	Website: www.j-ips.org
	DOI: 10.4103/jips.jips_35_19

This is an open access journal, and articles are distributed under the terms of the Creative Commons Attribution-NonCommercial-ShareAlike 4.0 License, which allows others to remix, tweak, and build upon the work non-commercially, as long as appropriate credit is given and the new creations are licensed under the identical terms.

For reprints contact: reprints@medknow.com

How to cite this article: dos Santos PH, Suzuki TY, Martini AP, Oliveira Reis B, Assunção WG, Rocha EP. Emergence profile customization technique during implant transfer. *J Indian Prosthodont Soc* 2019;19:197-200.

Cotia, SP, Brazil), was positioned on the implant. The patient waited 4 months before to complete the treatment. After this period, a clinical examination revealed a purple outline of the gingival margin surrounding the upper right lateral incisor, indicating that the patient had inappropriate boundaries. There was also asymmetry of the incisal edges of these teeth, which created disharmony of the lip contour, evident during a smile [Figure 1].

The upper right central and upper left lateral incisors were prepared to receive ceramic laminates, while the upper right lateral incisor was prepared to receive a full crown. The partial teeth preparations were carried out using guides of about 0.8 mm on the buccal surface, respecting the inclinations of the middle, cervical, and incisal shares of the crown. The incisal reduction was 1.5 mm.

The gingival contour site of the upper left central incisor was properly conditioned by the temporary crown [Figure 2]. During the impression procedure, the implant transfer was customized by copying the gingival profile. The customization was done by connecting the attached temporary crown to the implant analog in a portion of the condensation silicone (Zetaplus, Zhermack, Badia Polesine, RO, Italy) that was properly handled and stored in a glass Dappen dish. Thus, a copy of the profile of the gingival prosthetic crown was obtained [Figure 3]. The transferor of the implant replaced the temporary crown, and the space was filled with red acrylic resin added by the brush technique [Figure 4]. After curing of the acrylic resin, the customized transferor was removed from the Dappen dish, and the marginal contour could be compared with the provisional crown [Figure 5]. The customized transferor then was connected to the implant.

The impression was made using a double-mixing with a double-cord technique (#00 and #0 cord, Ultrapak–Ultradent, S. Jordan, UT, USA). A previously manufactured coping was connected to the implant. An additional silicone (Flexitime, Heraeus Kulzer, Hanau, HE, Germany) impression material was used for impression, including the transfer impression. Light-body material was inserted while the second cord was being removed. The corresponding putty body material was immediately manipulated according to the manufacturer's instructions and inserted in a stock tray that had been previously selected. After setting the material, the tray was removed from the mouth of the patient [Figure 6]. The temporary crowns were luted with temporary cement (RelyX Temp, 3M ESPE, St. Paul, MN, USA).

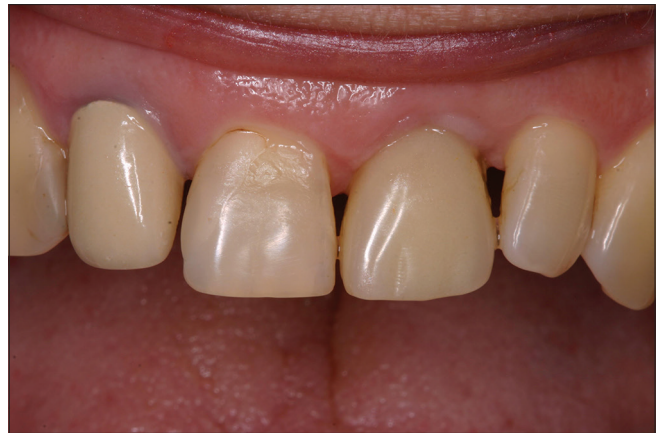

Figure 1: Initial view of upper anterior teeth

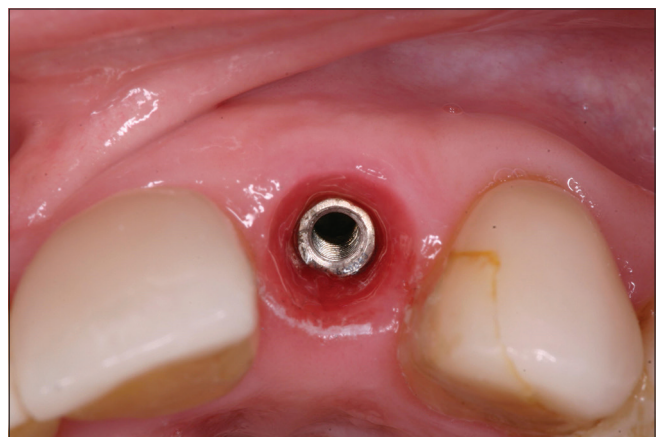


Figure 2: Profile of the gingiva preconditioned by the temporary crown




Figure 3: Customization and transferring of acrylic resin: An impression of the coronary profile with condensation silicone

The upper left central incisor received a customized abutment [Figure 7], which replaced the temporary crown originally installed. The crown was manufactured with Lava zirconia ceramic system (3M ESPE, St. Paul, MN, USA). The other prostheses were made with IPS e.max Press ceramic system (Ivoclar Vivadent, Barueri, SP, Brazil)

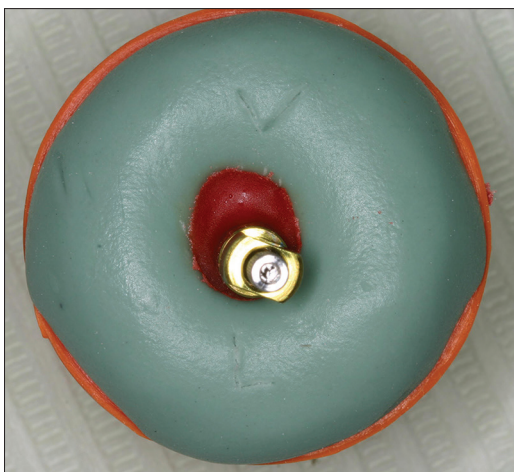

Figure 4: Customization of the transferor with acrylic resin: Filling the subgingival portion occupied by the crown with red acrylic resin

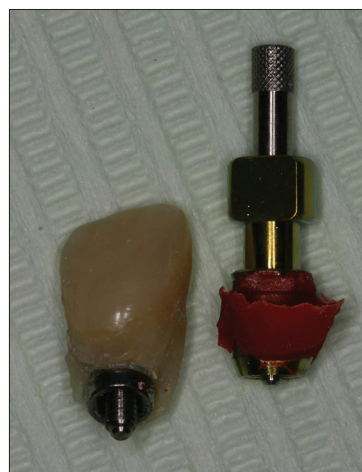

Figure 5: Customization of the transferor with acrylic resin: Result after the setting of the acrylic resin

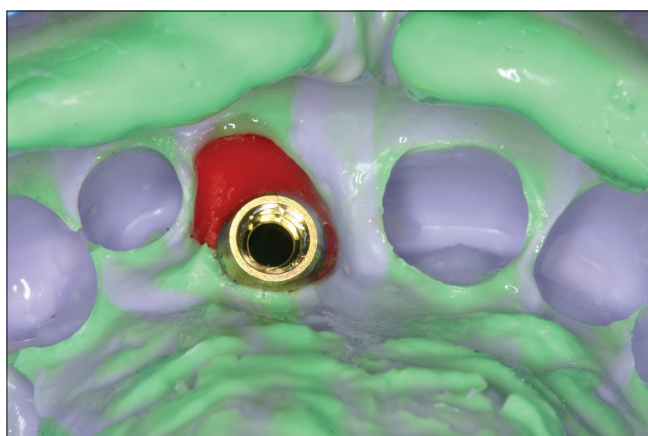


Figure 6: Transfer molding

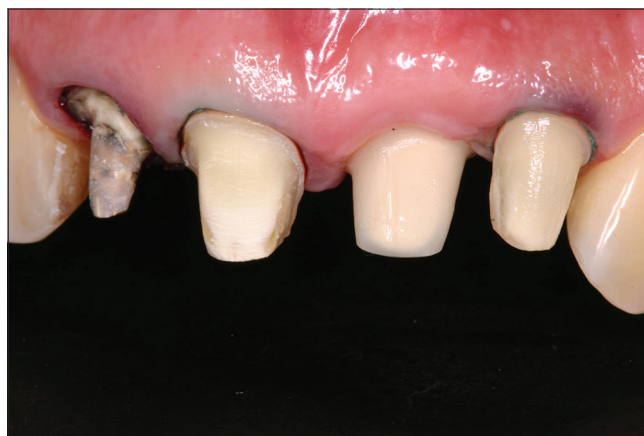

Figure 7: Teeth prepared and abutment positioned

and cemented with the resin cement RelyX U100 (3M ESPE, St. Paul, MN, USA) [Figure 8]. The installation of the prostheses on the implant occurred in the same session of the rehabilitation of other elements. Follow-up examinations were made annually and did not present irregularities or deficiencies in the prostheses.

DISCUSSION

The use of metal-free dental prostheses still generates some doubts in some clinicians in relation to mechanical properties; however, well-argued literature has reported its success in rehabilitation.^[5] Clinical studies have been published and further research is carried out constantly to improve the materials providing more satisfactory final results.^[6]

The installation of well-positioned temporary crowns by following the procedures established by David^[7] can facilitate the installation of permanent crowns because it ensures the appropriate conditioning of the gingiva.

It also promotes good esthetic outcomes. This is especially important when the use of provisional crowns is required by the impossibility of immediate loading of the implant.^[8]

It is important to note that two different ceramic systems were used in this case, not affecting the esthetic outcome.^[9] The Lava zirconia ceramic, used on the prostheses on implants and which uses solid-sintered zirconia, has several significant advantages: increased strength and toughness, decreased elastic modulus, and the remarkable property of transformation toughening.^[9] The IPS e.max Press consists of precolored ceramic pellets or ingots of different shades that offer high biocompatibility, natural appearance, and dental plaque resistance.^[9]

The customization of the implant transfer reported in this clinical case is similar to that proposed by den Hartog *et al.*^[4] It increases the predictability of treatments where esthetics is the key to success. The conventional implant

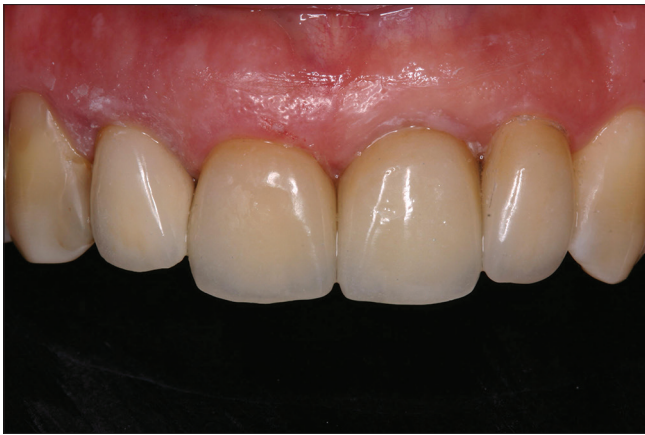

Figure 8: Final appearance of anterior teeth immediately after cementation

impression using prefabricated components does not necessarily reproduce the anatomical structure; hence, the emergence profile created is not ideal.^[9]

In this clinical report, acrylic resin was used for the customization of the impression post. Other materials, such as low-viscosity composite resins, can also be used intraorally. In this case, it was important to polymerize the intraoral materials without delay to avoid the collapse of the gingival tissue.^[10] Otherwise, the use of acrylic resin extraorally prevents the direct contact of the monomers with the gingiva and it working in a dry environment.^[10]

Therefore, the use of this simple and fast procedure permits obtaining an exact copy of the gingival profile allowing the prostheses to be more integrated into the oral environment, including the surrounding soft tissues what is crucial in rehabilitations involving anterior teeth.

Declaration of patient consent

The authors certify that they have obtained all appropriate patient consent forms. In the form the patient(s) has/have given his/her/their consent for his/her/their images and other clinical information to be reported in the journal. The patients understand that their names and initials will not be published and due efforts will be made to conceal their identity, but anonymity cannot be guaranteed.

Financial support and sponsorship

Nil.

Conflicts of interest

There are no conflicts of interest.

REFERENCES

1. Poggio CE, Ercoli C, Rispoli L, Maiorana C, Esposito M. Metal-free materials for fixed prosthodontic restorations. *Cochrane Database Syst Rev* 2017;12:CD009606.
2. Suphanantachai S, Thovanich K, Nisapakultorn K. The influence of peri-implant mucosal level on the satisfaction with anterior maxillary implants. *Clin Oral Implants Res* 2012;23:1075-81.
3. den Hartog L, Raghoobar GM, Stellingsma K, Meijer HJ. Immediate loading and customized restoration of a single implant in the maxillary esthetic zone: A clinical report. *J Prosthet Dent* 2009;102:211-5.
4. Shah R, Lavery DP. The use of all-ceramic resin-bonded bridges in the anterior aesthetic zone. *Dent Update* 2017;44:230-2, 235-8.
5. Della Bona A, Kelly JR. The clinical success of all-ceramic restorations. *J Am Dent Assoc* 2008;139:8S-13S.
6. Aydin C, Yilmaz H, Ata SO. Single-tooth zirconia implant located in anterior maxilla. A clinical report. *N Y State Dent J* 2010;76:30-3.
7. David R. Provisional restoration for an osseointegrated single maxillary anterior implant. *J Can Dent Assoc* 2008;74:609-12.
8. Henry PJ, Liddelow GJ. Immediate loading of dental implants. *Aust Dent J* 2008;53 Suppl 1:S69-81.
9. Ntounis A, Petropoulou A. A technique for managing and accurate registration of periimplant soft tissues. *J Prosthet Dent* 2010;104:276-9.
10. Papadopoulos I, Pozidi G, Goussias H, Kourtis S. Transferring the emergence profile from the provisional to the final restoration. *J Esthet Restor Dent* 2014;26:154-61.