

## Case Report

# Rehabilitation of a partial glossectomy patient: Palatal augmentation prosthesis

Payal Rajender Kumar, Anurag Hasti, H. G. Jagadeesh, Bishwachandra Thoudam

Department of Prosthodontics and Crown and Bridge, School of Dental Sciences, Sharda University, Greater Noida, Uttar Pradesh, India

**Abstract** Tongue-palate contact is necessary for the production of normal speech, and the proper location of the tongue on the palate during certain sounds is important. Partial glossectomy leads to difficulty in tongue-palate articulation during speech, and it becomes difficult for a patient to reach the palate with the tongue to form certain sounds. In-depth knowledge of the production of different sounds can be used as a diagnostic aid in determining the thickness of the palatal augmentation prosthesis fabricated to rehabilitate such patients. A functional wax technique is used to make a functional impression of tongue-palate contact during the speech.

**Keywords:** Palatal augmentation prosthesis, partial glossectomy, speech, speech therapy, squamous cell carcinoma

**Address for correspondence:** Dr. Payal Rajender Kumar, Department of Prosthodontics and Crown and Bridge, School of Dental Sciences, Sharda University, Greater Noida, Uttar Pradesh, India.  
E-mail: [drpayal24@gmail.com](mailto:drpayal24@gmail.com)

**Received:** 18<sup>th</sup> September, 2018, **Accepted:** 07<sup>th</sup> March, 2019

## INTRODUCTION

The posterior lateral border of the tongue is one of the most common sites for oral carcinomas. The treatment of choice for such lesions is surgical therapy in combination with radiotherapy and chemotherapy.<sup>[1]</sup> Posttreatment, patients are left with different levels of impairment of mastication, deglutition, and speech depending on the extent of surgical resection and partial or complete glossectomy with or without mandibulectomy. Tumor location in the anterior tongue has the biggest impact on articulation quality, whereas tumor in the tongue base has the biggest impact on swallowing.<sup>[2]</sup> It is a very challenging situation for a maxillofacial prosthodontist to rehabilitate such patients. Palatal augmentation prosthesis (PAP) has

been used successfully to allow reshaping the hard and/or soft palate to improve tongue/palate contact during speech and swallowing.<sup>[3]</sup> This could be a removable partial denture or complete denture prosthesis.

The thickness of the PAP will have a substantial effect on the phonetics and swallowing pattern of the patient. In-depth knowledge of production of different sounds can be used as a diagnostic aid in understanding the compensatory articulation used by glossectomy patients and in determining the thickness of the PAP.

## CASE REPORT

A 61-year-old male reported to the Department of Prosthodontics with chief complaints of difficulty in

Access this article online	
Quick Response Code:	Website: <a href="http://www.j-ips.org">www.j-ips.org</a>
	DOI: 10.4103/jips.jips_304_18

This is an open access journal, and articles are distributed under the terms of the Creative Commons Attribution-NonCommercial-ShareAlike 4.0 License, which allows others to remix, tweak, and build upon the work non-commercially, as long as appropriate credit is given and the new creations are licensed under the identical terms.

**For reprints contact:** [reprints@medknow.com](mailto:reprints@medknow.com)

**How to cite this article:** Kumar PR, Hasti A, Jagadeesh HG, Thoudam B. Rehabilitation of a partial glossectomy patient: Palatal augmentation prosthesis. *J Indian Prosthodont Soc* 2019;19:190-6.

swallowing and impaired speech due to partial resection of the tongue. Three years back, the patient was diagnosed with squamous cell carcinoma involving the right lateral border of the tongue and just crossing midline in the anterior two-third of the tongue. The patient underwent anterior two-third glossectomy and neck dissection.

The patient had diabetes for the last 5 years and was under medication. Extraoral examination indicated that there was little collapse of soft tissue on the right cheek and the right side of the neck. The patient had adequate mouth opening (50 mm) as seen in Figure 1. Intraoral examination depicted that the lingual sulcus was completely obliterated on the resected side. The patient was dentulous in both the jaws with few teeth missing [Figures 2 and 3]. The right-sided floor of the mouth is concave and essentially without function [Figure 4]. The floor of the mouth was reconstructed using a split-thickness skin flap from his thigh. The patient was wearing PAP for the last 1½ years which had a broken clasp. The prosthesis had helped the patient in speech and swallowing to some extent. The prosthesis did not have the required stability and retention.

It was flat on the oral surface as seen in Figure 5 and it lacked the contours required for phonetics.

The floor of the mouth had altered posture and restricted movements. Whenever there is residual function in the remaining floor of the mouth, PAP is considered.<sup>[3]</sup> The treatment plan thus included fabrication of PAP with oral surface being contoured by functional palatal impression technique using functional wax on the oral surface and reproducing the same in the final prosthesis.<sup>[4]</sup>

Primary impressions were made in addition silicone material in a stock tray, and primary casts were made. A self-cure hollow prosthesis was fabricated to work as a base on which molten Korecta wax would be applied to make functional records [Figure 6]. The clasps' design was also changed to make it more retentive and stiffer as compared with the previous prosthesis in which there was a long clasp arm, which resulted in increased flexibility making it prone to fracture. This prosthesis

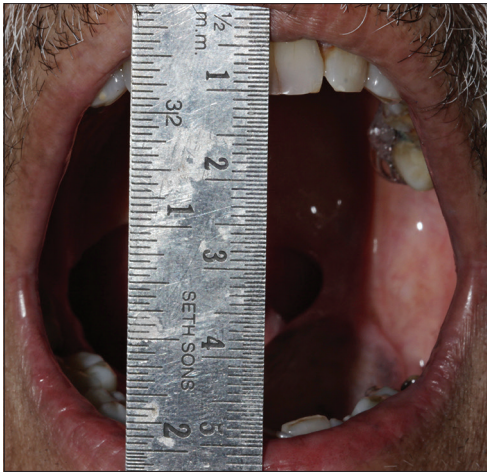


Figure 1: Maximum mouth opening

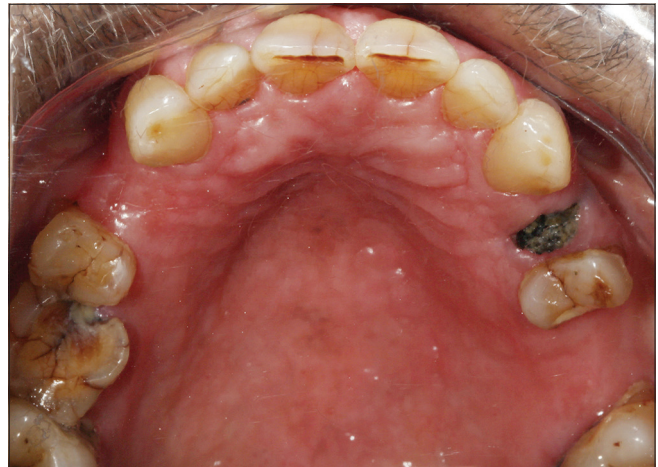

Figure 2: Maxillary arch

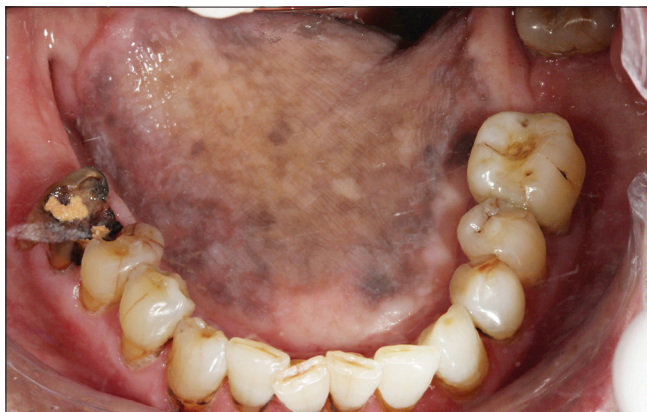

Figure 3: Mandibular arch

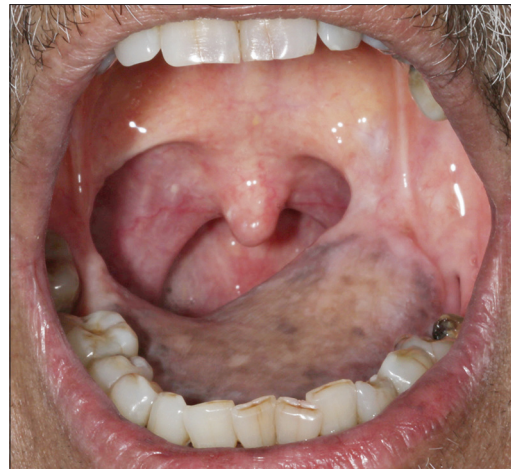

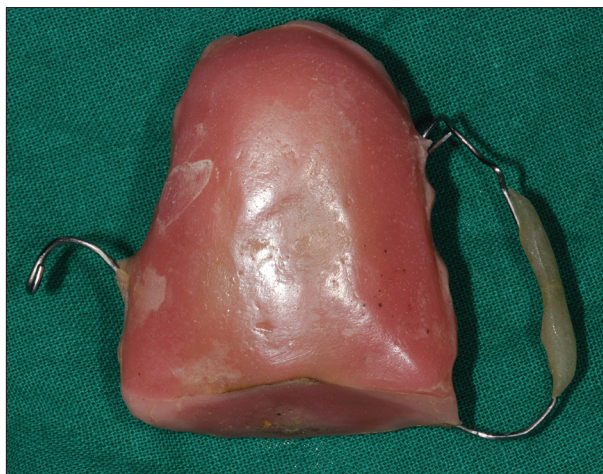Figure 4: Right side deficiency

was checked for comfort and retention before the records were made. The tongue-palate contacts were evaluated according to the clarity of speech during specific sounds.

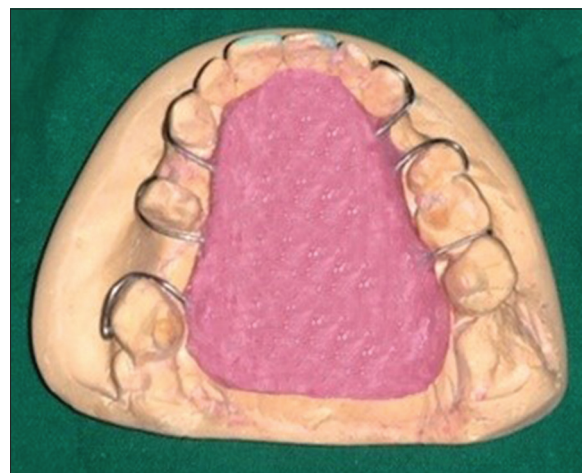
The wax was painted using a brush on the oral side of the hollow prosthesis, and the patient was instructed to functionally manipulate the wax by the floor of the mouth by repeating the linguoalveolar sounds /k/, /kh/, /g/, and /gh/ for the posterior palatal tracing. For the anterior palatal tracing, the linguoalveolar sounds /t/ and /d/ were used. These sounds enabled the tongue to articulate with the different positions on the palate. Additional wax was added to the anterior palatal region resulted in a significant improvement for the fricative and affricative (hard) linguopalatal sounds /s/, /sh/, /z/, /zh/, /ch/, and /jh/ as shown in Figure 7.<sup>[4,5]</sup> For tracing the swallowing patterns, the patient was asked to swallow saliva multiple times. Phonetics was checked again, and finally, a proper balance was achieved between speech and swallowing tracings.<sup>[6]</sup> It should be checked that both functions are performed without any restriction. The

prosthesis was finally processed with the heat cure acrylic resin. Laboratory putty index was made before flasking to make sure that the patterns recorded were not distorted by any heat or pressure generated [Figures 8-10]. A smooth palate without rugae was preferred by the patient for easier removal of food during eating [Figure 11].<sup>[4]</sup> The rainbow passage especially designed for Indian population was used to assess the speech intelligibility without the prosthesis,<sup>[7]</sup> with the previous prosthesis and with the new prosthesis.

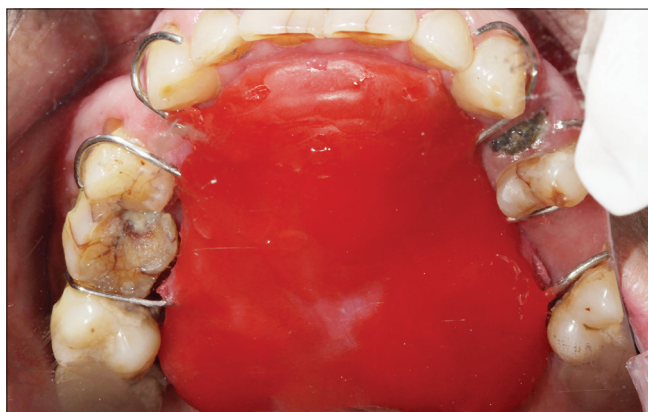The prosthesis was delivered to the patient and follow-ups were done after 24 h and 1 week. After 1 week, speech therapy and oral exercises were initiated to improve the efficiency of the prosthesis. The patient was asked to suck the saliva forcibly inside the pharynx to improve the swallowing abilities. He was also asked to do exercises involving muscles of cheeks, lips, and floor of mouth such as blowing and sucking exercises to improve articulation during speech.<sup>[8]</sup>



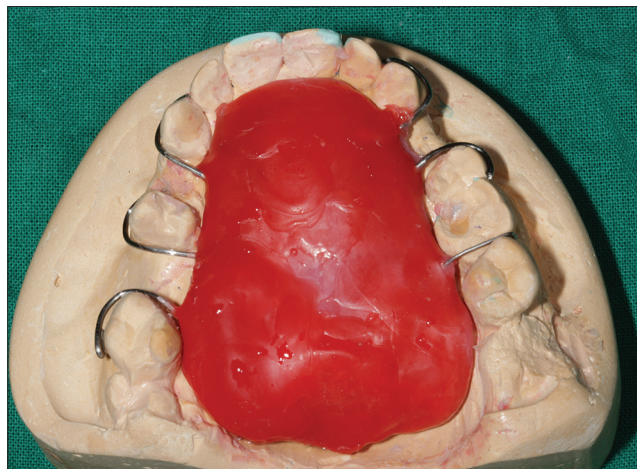
**Figure 5:** Old prosthesis with a flat oral surface



**Figure 6:** Hollow self-cure prosthesis



**Figure 7:** Intraoral functional wax recording



**Figure 8:** Seating the records on the cast

## DISCUSSION

Tongue coordinates with cheeks to keep the food on occlusal surface of the teeth. It also plays an important role in bolus formation and bolus propulsion into the pharynx. Increased space between the palate and the floor of the mouth in addition to limited or no movement of tongue can also lead to adherence of food to palate and inability to clean the food particles from the palatal vault. This also results in altered speech due to lack of contact of the tongue with the teeth (linguodental), the alveolar ridge (linguoalveolar), the hard palate (linguopalatal), and the soft palate (linguovelar).

Tongue is the principle articulator for speech and learning its position for a given sound is the key to speech learning [Figure 12]. The source of production of sound is the air in the lungs which passes through the vibrators (vocal folds in the larynx) and as it en routes to the exterior, i.e., larynx, pharynx, nasal cavity, and oral cavity, the sound is modified by various structures which act as resonators to reinforce

the original sound wave. Furthermore, it involves precise coordination between different articulators that refines the final sound. The articulators move toward each other to create an obstruction that shapes the air in a particular fashion.

Vocal folds, velum and pharynx, velum and tongue, tongue and palate, lips and teeth, and lips themselves are prime articulators. The point of maximum obstruction is called the place of articulation and the way the obstruction forms and releases is the manner of articulation, e.g., stops (plosive) and fricatives. This involves six valves; bilabial, labiodental, linguodental, linguoalveolar [Figure 13], linguopalatal [Figure 14], and linguovelar [Figure 15] as shown in Tables 1 and 2.<sup>[8]</sup>

Nonetheless, glossectomy definitely hampers the production of linguodental, linguoalveolar, linguopalatal, and linguovelar sounds [Figure 16]. This basic knowledge was applied to do the functional wax technique. Since the patient had right side defect, the PAP required

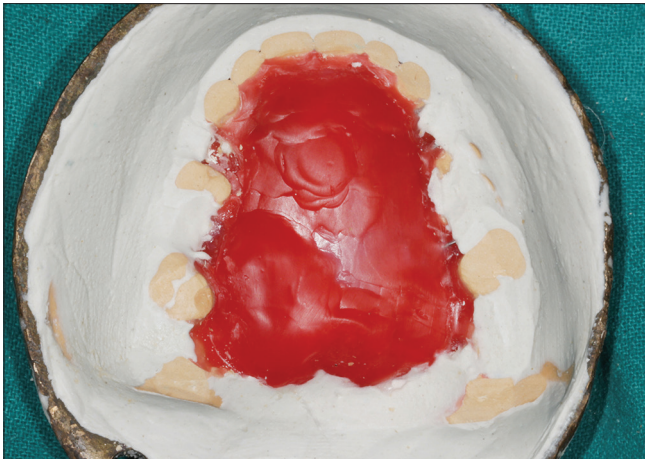

Figure 9: Flasking for acrylization



Figure 10: Protection of the records with putty index

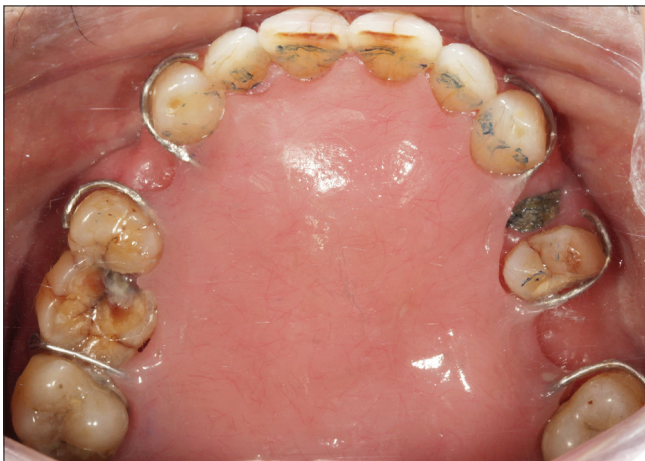

Figure 11: Final prosthesis intraorally

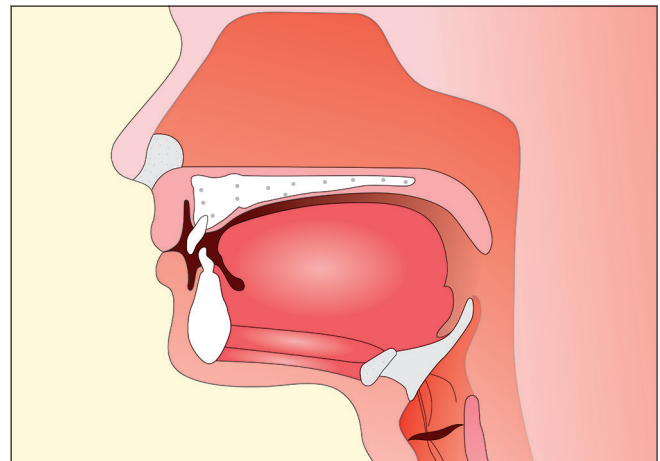
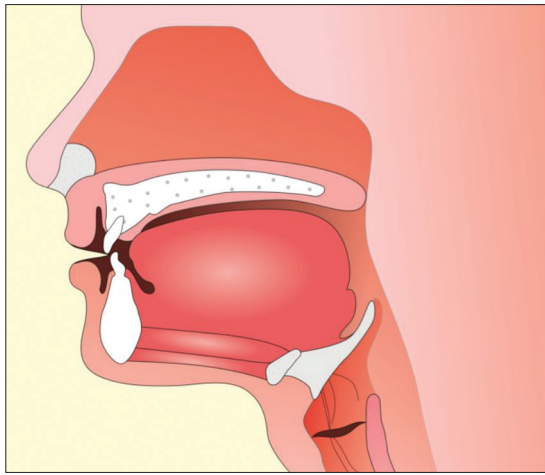
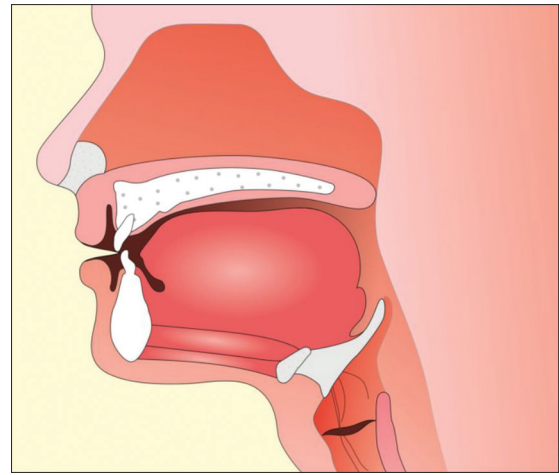


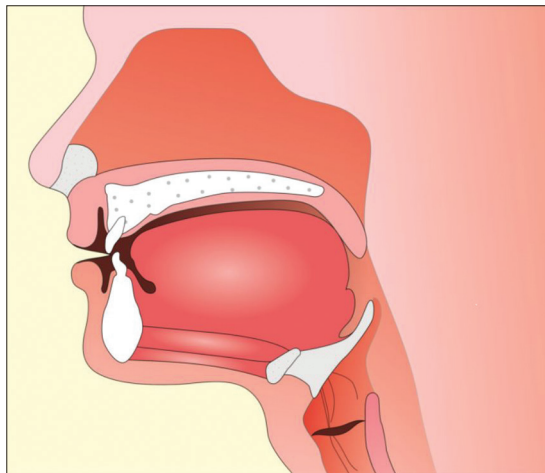
Figure 12: Normal position of tongue



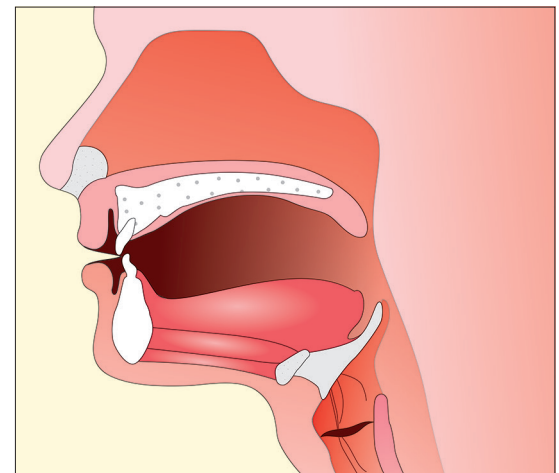
**Figure 13:** Position of tongue in linguoalveolar sounds



**Figure 14:** Position of tongue in linguopalatal sounds



**Figure 15:** Position of tongue in linguovelar sounds



**Figure 16:** After glossectomy

**Table 1: Manner of production - Hindi consonants<sup>[8]</sup>**

Place	Manner of production			
	Plosives	Fricatives	Affricative	Nasal
Bilabial	प ब भ			म
Labiodental		फ व		
Linguodental	त थ द ध			न
Linguoalveolar	ट ठ ड ढ	स ल		ण
Linguopalatal		श ष र	च छ ज झ क्ष	
Linguovelar	क ख ग घ	य		

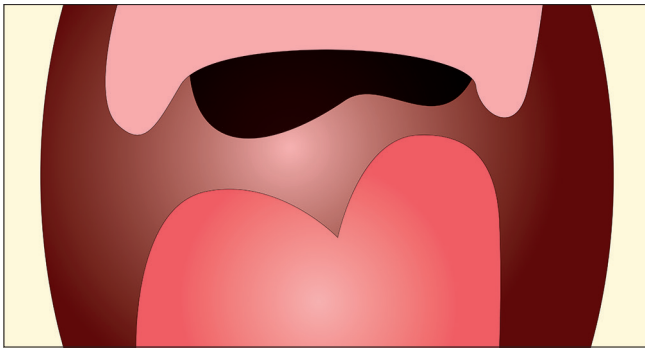
more addition of wax on that side [Figure 17]. Molten wax was painted in segments to record one group at a time. Linguoalveolar [Figure 18] sounds were used first, linguopalatal [Figure 19] sounds the next, and linguovelar at the end [Figure 20].

The prosthodontic management of glossectomy patients depends on the size of the defect. The patients with partial tongue resection often include PAP to lower the palatal vault, while the management of total glossectomy

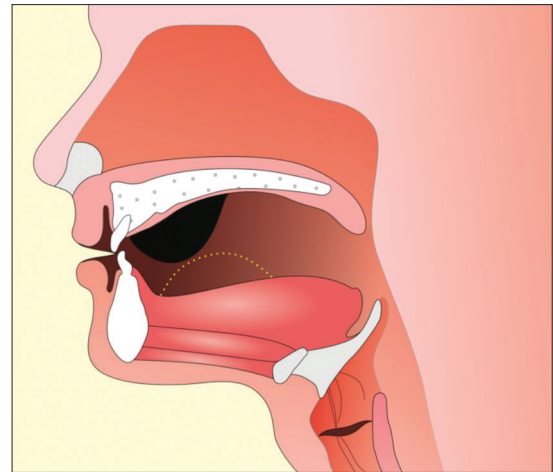
usually requires a mandibular tongue prosthesis.<sup>[9]</sup> The purpose of the prosthodontic rehabilitation in such cases is to reduce the size of the oral cavity for better speech and directing food into the esophagus for efficient swallowing. Undoubtedly, the rehabilitation in such cases is a challenging process for both the prosthodontist and the patient. The functional utility of a static prosthesis is limited as it cannot replace the mobile tongue, which is capable of infinite movements in swallowing and speech.

**SUMMARY**

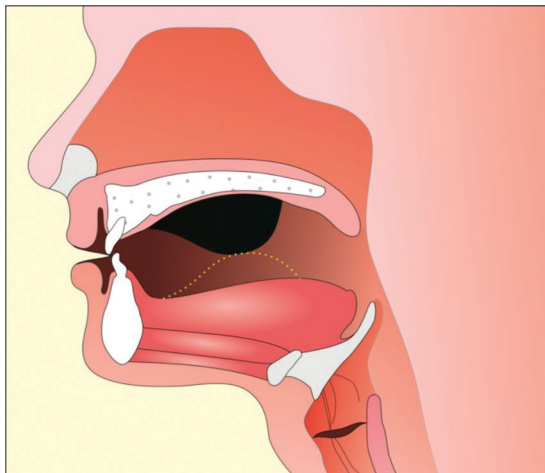
Surgeries in cases of oral carcinoma involving the tongue and the floor of the mouth often result in the reduced mobility of the tongue during speech and deglutition. Partial glossectomy patients require prosthetic augmentation with a prosthesis that lowers the palatal vault to restore tongue-palate contact. Phonetics can be used to diagnose the regions deficient in tongue-palate contact and to reevaluate speech after prosthetic rehabilitation.<sup>[10]</sup> A functional



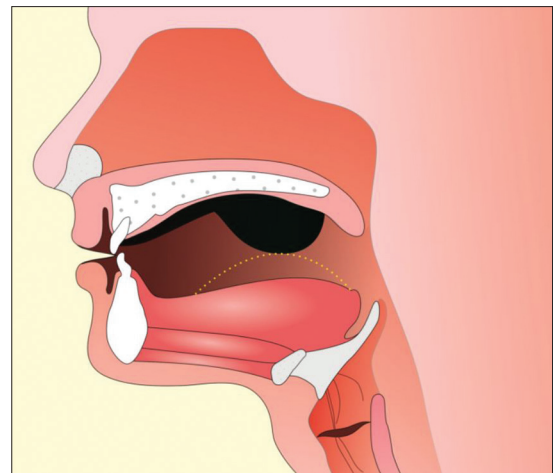
**Figure 17:** Cross-section image to show palatal augmentation prosthesis



**Figure 18:** Addition of wax for linguoalveolar sounds



**Figure 19:** Addition of wax for linguopalatal sounds



**Figure 20:** Addition of wax for linguovelar sounds

**Table 2: Manner of production - English consonants<sup>[8]</sup>**

Place	Plosives	Manner of production			
		Fricatives	Affricative	Semi vowel	Nasal
Bilabial	P (pole) B (bowl)			W (watt)	M (sum)
Labial dental	F (fat) v (vat)				
Linguodental	T (thigh) h (thy)				
Linguoalveolar [Figure 14]	T (toll) d (dole)	S (seal) z (zeal)		L (lot)	N (sun)
Linguopalatal [Figure 15]		Z (azure)	Ch (choke) j (joke)		
Linguovelar [Figure 16]	K (koal) g (goat)				Ng (sing)

impression is important in the fabrication and proper placement of PAP. Teamwork with a speech pathologist can be helpful during diagnosis and management in such cases.<sup>[11]</sup> Speech therapy is also necessary for significant rehabilitation of speech. This will result in improved lifestyle and socialization in these patients.

**Declaration of patient consent**

The authors certify that they have obtained all appropriate patient consent forms. In the form, the patient has given

his consent for his images and other clinical information to be reported in the journal. The patient understands that name and initials will not be published and due efforts will be made to conceal identity, but anonymity cannot be guaranteed.

**Financial support and sponsorship**

Nil.

**Conflicts of interest**

There are no conflicts of interest.

**REFERENCES**

- McKinstry RE, Aramany MA, Beery QC, Sansone F. Speech considerations in prosthodontic rehabilitation of the glossectomy patient. *J Prosthet Dent* 1985;53:384-7.
- Logemann JA, Pauloski BR, Rademaker AW, McConnel FM, Heiser MA, Cardinale S, *et al.* Speech and swallow function after tonsil/base of tongue resection with primary closure. *J Speech Hear Res* 1993;36:918-26.
- Aramany MA, Downs JA, Beery QC, Aslan Y. Prosthodontic rehabilitation for glossectomy patients. *J Prosthet Dent* 1982;48:78-81.

Kumar, *et al.*: Palatal augmentation prosthesis

4. Knowles JC, Chalian VA, Shanks JC. A functional speech impression used to fabricate a maxillary speech prosthesis for a partial glossectomy patient. *J Prosthet Dent* 1984;51:232-7.
5. Lauciello FR, Vergo T, Schaaf NG, Zimmerman R. Prosthodontic and speech rehabilitation after partial and complete glossectomy. *J Prosthet Dent* 1980;43:204-11.
6. Garg A. Prosthodontic rehabilitation of completely edentulous patient with partial glossectomy. *J Indian Prosthodont Soc* 2016;16:204-7.
7. Bachher GK, Dholam K, Pai PS. Effective rehabilitation after partial glossectomy. *Indian J Otolaryngol Head Neck Surg* 2002;54:39-43.
8. Jain AR, Venkat Prasad MK, Ariga P. Palatogram revisited. *Contemp Clin Dent* 2014;5:138-41.
9. Cöttert HS, Aras E. Mastication, deglutition and speech considerations in prosthodontic rehabilitation of a total glossectomy patient. *J Oral Rehabil* 1999;26:75-9.
10. Dilip D, Janani M, Arun G. Rehabilitation of a patient with partial glossectomy. *J Indian Prosthodont Soc* 2008;8:119-21.
11. Lehman WL, Hulicka IM, Mehringer EJ. Prosthetic treatment following complete glossectomy. *J Prosthet Dent* 1966;16:344-50.