

Case Report

Rehabilitation of missing digit using customized attachment supported prosthesis

Siddharth Mehta, Rasalika Agrawal¹, Shashank Chitikeshi¹, D. B. Nandeeshwar

Department of Prosthodontics and Crown and Bridge, Bapuji Dental College and Hospital, Davangere, ¹Affiliated to Rajiv Gandhi University of Health Sciences, Bangalore, Karnataka, India

Abstract

Traumatic amputation of a finger leads to psychological instability, functional loss, and poor esthetics. When surgical reconstruction in patients is not possible, prosthesis provides psychological, functional, rehabilitative, and esthetic restoration. Despite the availability of advanced skills, the best of materials and laboratory support, sometimes the anatomy of the defect, may be a hindrance in furnishing a better prosthesis. In the present case report, a defect with complete loss of stump was restored using customized ring-stump assembly, which helped to enhance the fit and retention of the prosthesis along with fulfilling the functional demands of the patient.

Keywords: Customized ring-stump assembly, fingers, maxillofacial prosthesis, silicone elastomers

Address for correspondence: Dr. Siddharth Mehta, Department of Prosthodontics and Crown and Bridge, Bapuji Dental College And Hospital, Davangere, Karnataka, India.

E-mail: drsiddharthmehta24@gmail.com

Received: 24th November, 2018, **Accepted:** 05th June, 2019

INTRODUCTION

Man's need for artificial replacement of missing body parts undoubtedly dates back to as far as humanity itself. Trauma leading to finger amputation causes functional disability, disfigurement, and psychological issues. Studies have reported that 86.9% of the upper limbs and 52.9% of the lower limbs are amputated due to traumatic injuries.^[1] Rehabilitation of such defects is challenging to the maxillofacial prosthodontist. Saving traumatically severed fingers by plastic surgery, autoplasty or microsurgical reimplantations would be an obvious choice for patients as well as surgeons.^[2,3] However, such surgical reconstructions are often limited by insufficient residual soft and hard tissues and vascular

compromise.^[3] Nevertheless, maxillofacial prostheses present an attractive and practical alternative to restore at least the form and to some extent the function of the amputated fingers.^[4]

However, the success rate of these prostheses depends precisely on planning and designing the prosthesis meticulously. To ensure proper fit of prosthesis, the most important prerequisite is the presence of a well-healed stump with adequate length.^[5] In case the anatomy of the stump provides inadequate retention, alternate methods such as adhesive pastes, adhesive tapes, elastic bands, and rings have been suggested in the literature to enhance retention. In the present article, we describe a novel method to achieve a secure

Access this article online	
Quick Response Code:	Website: www.j-ips.org
	DOI: 10.4103/jips.jips_372_18

This is an open access journal, and articles are distributed under the terms of the Creative Commons Attribution-NonCommercial-ShareAlike 4.0 License, which allows others to remix, tweak, and build upon the work non-commercially, as long as appropriate credit is given and the new creations are licensed under the identical terms.

For reprints contact: reprints@medknow.com

How to cite this article: Mehta S, Agrawal R, Chitikeshi S, Nandeeshwar DB. Rehabilitation of missing digit using customized attachment supported prosthesis. *J Indian Prosthodont Soc* 2019;19:276-80.

prosthetic fit in patients where the residual finger stump is completely absent.

CASE REPORT

A 47-year-old male patient reported to the department of prosthodontics, with the chief complaint of missing little finger of the right hand. On taking proper history, the patient who is a farmer by occupation revealed that he had lost his finger 7 years back in an accident while working in the field. Inspection of the defect area revealed a missing little finger of the right hand with absolutely no residual stump present, and no signs of discoloration, pulsating veins, and edema were seen [Figure 1]. On palpation, the defect was compressible in nature, and no bony undercuts or subcutaneous nodules were present.

Presence or absence of a residual stump predominantly dictates the mode of retention suitable for restoring a defect. In cases like this, where there is a complete absence of a residual stump anatomy, the use of conventional modes of retention such as glove and strap types becomes questionable. Therefore, reconstruction of the defect area was considered by fabrication of a silicone prosthesis that could be retained with a customized ring-stump assembly which acted as a stump to offer better retention.

The procedure was started with making diagnostic impressions of both hands using irreversible hydrocolloid material (Hydrogum, Zhermack, Italy), following which, impressions were poured with Type 3 gypsum product (Kalabhai Kalstone) and positive replicas in the form of working models were obtained [Figure 2a]. The models were evaluated to study the anatomy of the defect area.

To fabricate the wax pattern, an impression of a suitable donor finger, resembling closely the dimensions and contours of the patient's missing finger, was made using polyvinyl siloxane (PVS) putty impression material (3M ESPE, soft putty, Bengaluru - 560 100, Karnataka, India). The impression was poured with modeling wax (Elite Dental Products, Nanded - 431 605, Maharashtra, India), and the wax pattern thus obtained was adapted on a stone model obtained from the patient [Figure 2b]. Sculpting and modification of the wax pattern was done to resemble the little finger of the patient's left hand. This was then tried to evaluate the esthetics, fit, and orientation on both the dorsal and ventral aspects of the patient's hand [Figure 2c].

Next, another wax pattern for the fabrication of a customized ring was made on the ring finger of the right

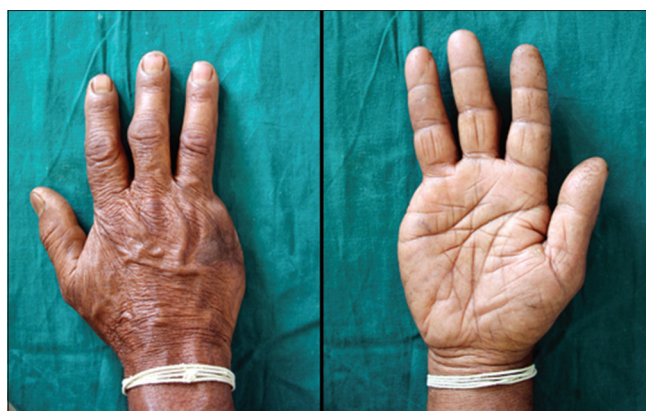

Figure 1: The dorsal and ventral aspects of the right hand with the defect

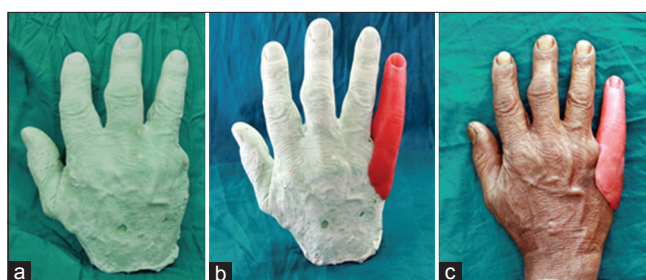

Figure 2: (a) The working model. (b) The wax pattern fabrication on the model. (c) The wax pattern try-in on the right hand

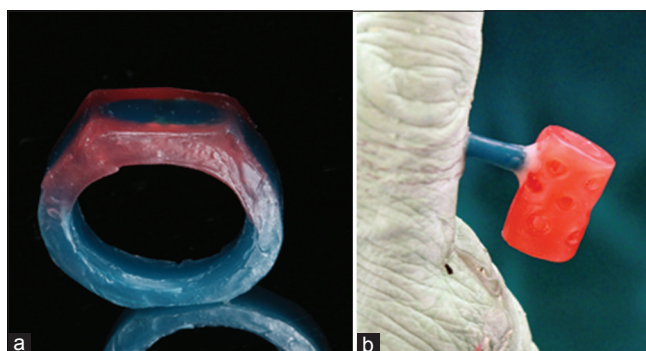


Figure 3: (a) The wax pattern of the customized ring. (b) The wax pattern fabrication of the hollow cylindrical stump

hand [Figure 3a]. Simultaneously, a wax pattern resembling a hollow cylinder with holes and sprue extension emerging at right angles to the hollow wax cylinder was fabricated, which acted as a stump [Figure 3b]. Holes helped to allow for retention of silicone to the casted stump, and the sprue extension acted as a connector between the customized stump and the customized ring. These wax patterns were then casted, finished, and polished.

The customized ring and stump were then placed on the patients' hand [Figure 4c], and once proper orientation was obtained, the same was indexed into PVS putty impression material [Figure 4a]. This was done to ensure proper

stability between the customized ring and customized stump during the soldering procedure. The assembly was soldered together [Figure 4b], and the final customized ring-stump assembly was tried on the patient's ring finger of the right hand once again to confirm the orientation [Figure 4c].

The stump portion of the customized ring-stump assembly was inserted into the wax pattern. This entire system was tried back on the patient's hand to check the final orientation [Figure 5a]. After the final verification, the finer details of the tissue surface of the defect area were recorded using light-body impression material (Affinis perfect impressions, Coltene) [Figure 5b]. This was done to ensure intimate contact between the skin of the defect area and the underlying tissue surface of the final prosthesis.

The customized ring-stump-wax pattern assembly was flaked using two-pour technique. In the first pour, the wax

pattern was embedded in the dental stone until the junction of the dorsal and the ventral surface of the wax pattern. To obtain finer details and increase the strength, the area surrounding the wax pattern was invested using Die Stone. The ring was embedded in putty material to ensure that there is no flow of dental stone into it, thereby creating an undercut. Later, a second pour was made using dental stone. Dewaxing was done, and the mold was inspected for any irregularities [Figure 6].

Medical grade Cosmesil RTV maxillofacial silicone (Cosmesil series material, Principality Medical Ltd, South Wales, UK) was used for the fabrication of prosthesis. The silicone is available in Part A and Part B (Part A: Part B to be mixed in the ratio of 10:1). Intrinsic skin color (Technovent Intrinsic Master Colour Series, Lot No. B13B, Principality Medical Ltd, South Wales, UK) matching was done chairside in the presence of the patient separately for dorsal and ventral aspects of the finger [Figure 7]. After satisfactory shade matching was obtained, Part B was mixed. The silicone mixture was packed into the mold [Figure 8] and the mold was left overnight for bench curing at room temperature following the manufacturer's recommendations.

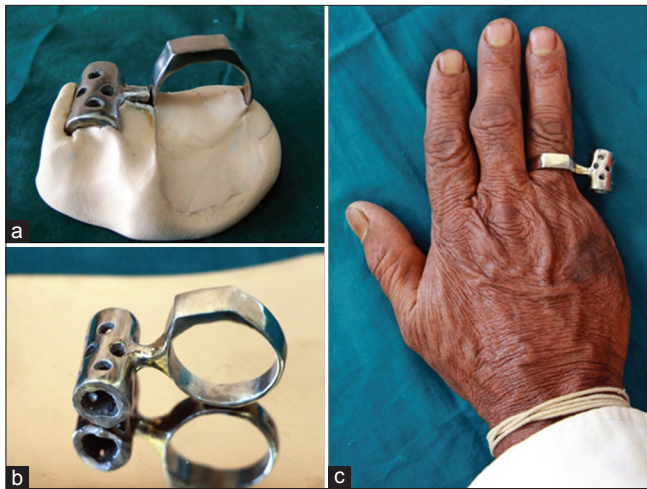

Figure 4: (a) The ring-stump assembly embedded in putty. (b) The customized ring-stump assembly after soldering. (c) The try-in of the ring-stump assembly

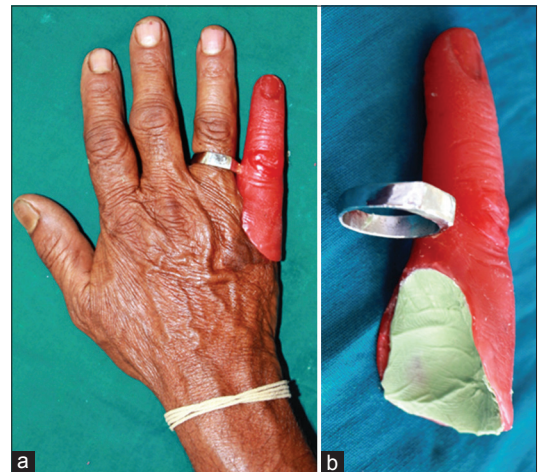


Figure 5: (a) The try-in of the ring-stump-wax pattern assembly. (b) The relining of the under surface of wax pattern with polyvinyl siloxane light-body material



Figure 6: The dewaxed mold obtained with two-pour technique

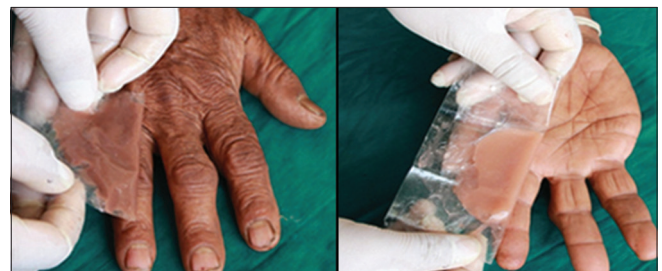

Figure 7: Shade matching for both dorsal and ventral aspects

After final curing, customized ring-stump assembly retained silicone prosthesis was retrieved, trimmed, and cleaned and tried on the patients' hand [Figure 9]. Matt finish ensures natural and life-like feel; hence, excessive polishing was avoided. Extrinsic pigments (Technovent Extrinsic Colour Series, Lot No. B14A, Principality Medical Ltd, South Wales, UK) were then added to the prosthesis for the final color matching. This was done in the presence of the patient and adequate natural light conditions. Medical grade adhesive (Technovent Probond Adhesive [G609] Principality Medical Ltd, South Wales, UK) was applied on the base of the prosthesis to ensure added retention. The prosthesis was inserted and checked for the color matching, orientation of the prosthesis, and its camouflage with the surrounding tissue.

Instructions regarding the maintenance and care of the prosthesis were given to the patient. The patient was very pleased and satisfied with the overall appearance and fit

of the prosthesis [Figure 10]. The patient was made to practice and demonstrate various prehensile activities such as holding a tumbler, writing, and shaking hands; the prosthesis seemed to be functionally stable and acceptable [Figure 11]. These functions were assessed on the basis of the Southampton Hand Assessment Procedure that allows contextual results of hand function to be obtained readily in a clinical environment.^[6]

DISCUSSION

The custom-fabricated metal ring attachment assembly proved to be beneficial in terms of being light weight, ensuring adequate fit, offering resistance to corrosion, and adequate mechanical interlocking of the silicone to the customized stump. Various case reports by Saxena *et al.*,^[7] Ahmad *et al.*,^[8] Mehta *et al.*,^[9] and Nazir *et al.*^[10] have been reported where they have shown techniques of fabricating customized prosthesis using retentive aids and used for added retention of finger prosthesis.

The stump of the amputated finger should be more than 1.5 cm in length measured from the metacarpophalangeal crease to fit the standard digital prosthesis.^[11] Since our patient had absolutely no residual stump, a standard prosthesis could not be fabricated. Other alternatives would

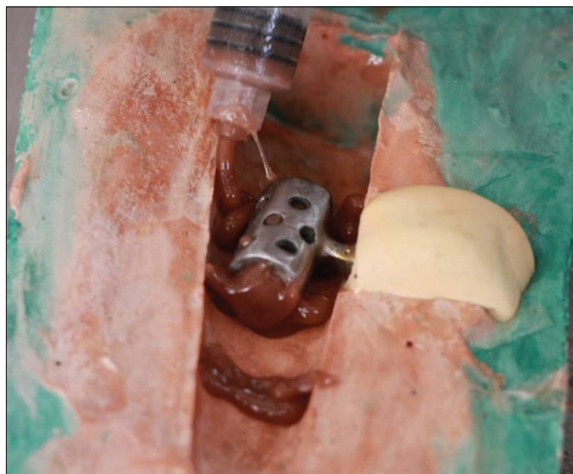


Figure 8: Packing of silicone material into stump holes to ensure retention

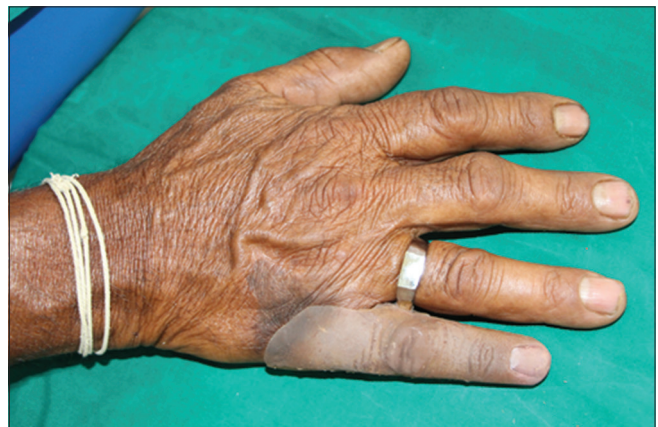

Figure 9: Try-in of the retrieved final prosthesis before finishing

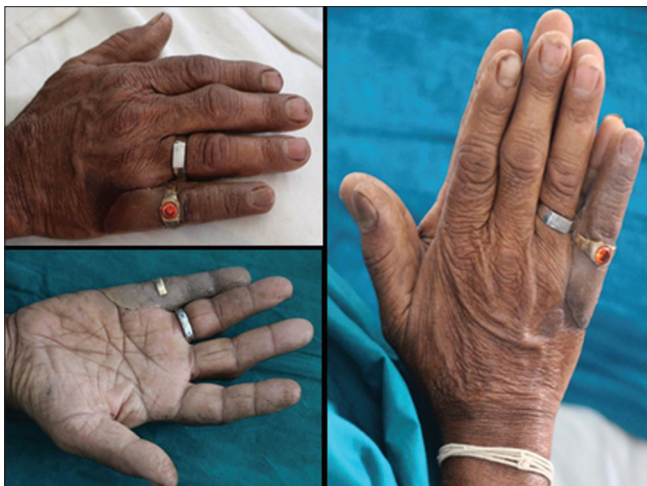

Figure 10: The final insertion of the prosthesis after extrinsic staining

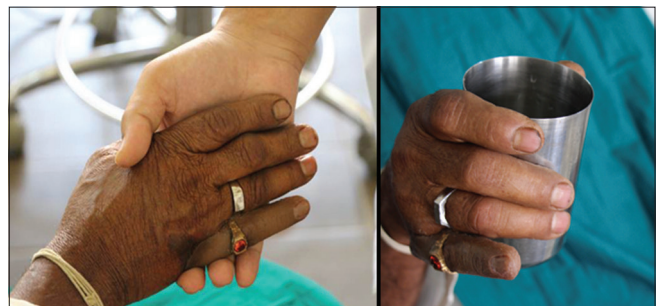

Figure 11: The functional assessment of the prosthesis

have been (1) bone grafting with a flap, which would result in a bulky stump, (2) bone distraction, which is very difficult to achieve in short stumps and is usually unsuitable for standard digital prosthesis,^[10] and (3) implant placement in the remaining metacarpal bone.^[3]

The use of osseointegrated dental implants to retain a finger prosthesis has been documented extensively in the literature.^[3] The retention provided by implants is much superior than the retention obtained by medical grade adhesives and other retentive modes.^[12] Although implant could have been a viable option, it was not used as a retention modality in the present case due to the reduced amount of bone available in the metacarpal of the little finger in the defect site. Apart from this, the patient was apprehensive regarding the surgical intervention and the cost aspects of implant.

In the present case report, the appearance and the retention of the prosthesis were improved using a customized ring-stump assembly. Since the residual stump was absent, there was practically no range of movement seen. The sprue which connected the ring and the prosthesis ensured the flexion and extension movements of the finger prosthesis. However, there were restricted abduction and adduction movements of the prosthesis. To avoid the axial deviation and accidental dislodgment of the prosthesis during digital manipulation in grip functions, relining of the inner surface of the prosthesis was done and a medical grade adhesive was used for the added retention. A well-fabricated esthetic and functional prosthesis can help in providing the patients with psychological support.^[13] The prosthesis is easily cleansable with water and soap; and is made of material that is pleasant to wear and have good fixation and prevents pressure sores. It ensures ease in application and removal of the prosthesis. Also there is enhanced counter-support for existing fingers and improved gripping function.^[7]

Declaration of patient consent

The authors certify that they have obtained all appropriate patient consent forms. In the form the patient(s) has/have given his/her/their consent for his/her/their images and other clinical information to be reported in the journal. The patients understand that their names and initials will not be published and due efforts will be made to conceal their identity, but anonymity cannot be guaranteed.

CONCLUSION

Repairing and restoring something which are given by nature and lost, unfortunately, help to buoy up the spirit and mind of the affected. Fabricating a maxillofacial prosthesis in situations encountering compromised anatomy has always been a challenge for a maxillofacial prosthodontist. Advantages of this customized attachment are as follows: cost-effective, easily customizable, improves functional ability, and provides a psychological advantage for patients who have lost a finger but do not have a residual stump.

Financial support and sponsorship

Nil.

Conflicts of interest

There are no conflicts of interest.

REFERENCES

1. Marty J, Porcher B, Autissier R. Hand injuries and occupational accidents. Statistics and prevention. *Ann Chir Main* 1983;2:368-70.
2. Kamble VB, Desai RG, Arabbi KC, Mahajan K, Patil S. Finger prostheses for multiple finger amputations: Two case reports. *Nat J Med Dent Res* 2013;1:38-42.
3. Ozkan A, Senel B, Durmaz CE, Uyar HA, Evinc R. Use of dental implants to retain finger prostheses: A case report. *Oral Health Dent Manag* 2012;11:11-5.
4. Saxena D, Jurel S, Gupta A, Dhillon M, Tomar D. Rehabilitation of digital defect with silicone finger prosthesis: A case report. *J Clin Diagn Res* 2014;8:ZD25-7.
5. Goyal A, Goel H. Prosthetic rehabilitation of a patient with finger amputation using silicone material. *Prosthet Orthot Int* 2015;39:333-7.
6. Light CM, Chappell PH, Kyberd PJ. Establishing a standardized clinical assessment tool of pathologic and prosthetic hand function: Normative data, reliability, and validity. *Arch Phys Med Rehabil* 2002;83:776-83.
7. Saxena K, Sharma A, Hussain MA, Thombare RU, Bhasin SS. A hollow silicone finger prosthesis with modified metal-mesh conformer. *J Indian Prosthodont Soc* 2014;14:301-4.
8. Ahmad M, Balakrishnan D, Narayan A, Naim H. Comprehensive rehabilitation of partially amputated index finger with silicone prosthesis: A case report with 3 years of follow up. *J Indian Prosthodont Soc* 2014;14:222-6.
9. Mehta S, Leela B, Karanjkar A, Halani AJ. Prosthetic rehabilitation of a partially amputated finger using a customized ring-wire substructure. *J Indian Prosthodont Soc* 2018;18:82-5.
10. Nazir S, Gangadhar SA, Manvi S. Fabrication of silicone finger prosthesis: A clinical report. *J Indian Prosthodont Soc* 2006;6:199-201.
11. Manurangsee P, Isariyawut C, Chatuthong V, Mekraksawanit S. Osseointegrated finger prosthesis: An alternative method for finger reconstruction. *J Hand Surg Am* 2000;25:86-92.
12. Pattanaik B, Pattanaik S. Fabrication of a functional finger prosthesis with simple attachment. *J Indian Prosthodont Soc* 2013;13:631-4.
13. Shanmuganathan N, Maheswari MU, Anandkumar V, Padmanabhan TV, Swarup S, Jibran AH, *et al.* Aesthetic finger prosthesis. *J Indian Prosthodont Soc* 2011;11:232-7.