

Retention and patient satisfaction with bar-clip, ball and socket and kerator attachments in mandibular implant overdenture treatment: An *in vivo* study

Nitish Varshney, Sumit Aggarwal, Shalabh Kumar, S. P. Singh

Department of Prosthodontics and Crown and Bridge, ITS - CDSR, Ghaziabad, Uttar Pradesh, India

Abstract

Aim: The aim of this *in vivo* study was to evaluate and compare the retention and patient satisfaction in implant supported mandibular overdenture with three different attachment system.

Materials and Methods: After evaluation of prosthetic space, fifteen edentulous subjects received two implants in the inter-foramina region of the mandible and were divided into 3 groups with 5 subjects each, delayed loading protocol was followed in all the patients. The retention force and satisfaction level with the attachments at baseline and after 6 months was measured in a standardised way using retentive device and VAS questionnaire. The study was based on evaluation of retention and patient satisfaction. 15 subjects were included in the study. The results obtained were statistically analyzed using one-way ANOVA test, and multiple comparisons were carried out using the Bonferroni tests.

Results: At the end of six months, the retention force and satisfaction level was higher in Group 3 (Kerator attachment) as compared to Group 1 (ball and socket attachment) and Group 2 (bar and clip attachment) and patient satisfaction was equal in groups 1, 2 and 3 but the total number of interventions is significantly higher in the attachment bar. Analysis of variance with repeated measures showed significant differences in retention force among the three attachment types.

Conclusion: (1) Group 3 (kerator attachment) exhibit higher retentive capacities than Group 1 (ball and socket attachment) and Group 2 (bar and clip attachment). (2) patient satisfaction was higher in Group 3 (Kerator attachment) in compare to Group 1 (ball and socket attachment) and Group 2 (bar and clip attachment).

Keywords: Ball attachment, bar attachment, Implant supported overdenture, Kerator attachment, patient satisfaction, retention value

Address for correspondence: Dr. Nitish Varshney, Department of Prosthodontics and Crown and Bridge, Room No. 4, ITS - CDSR, Murad Nagar, Ghaziabad, Uttar Pradesh, India.

E-mail: dr.nvarshney@gmail.com

Received: 20th August, 2018, **Accepted:** 29th November, 2018

INTRODUCTION


A common condition in geriatric patients is the occurrence of edentulism. According to the United Nations Population

Division (UN 2011), the share of India's edentulous population aged 60 and above is projected to climb from 8% in 2010 to 19% in 2050. One therapeutic approach

This is an open access journal, and articles are distributed under the terms of the Creative Commons Attribution-NonCommercial-ShareAlike 4.0 License, which allows others to remix, tweak, and build upon the work non-commercially, as long as appropriate credit is given and the new creations are licensed under the identical terms.

For reprints contact: reprints@medknow.com

How to cite this article: Varshney N, Aggarwal S, Kumar S, Singh SP. Retention and patient satisfaction with bar-clip, ball and socket and kerator attachments in mandibular implant overdenture treatment: An *in vivo* study. J Indian Prosthodont Soc 2019;19:49-57.

Access this article online	
Quick Response Code:	Website: www.j-ips.org
	DOI: 10.4103/jips.jips_281_18

directed at improving oral function in the elderly is the use of implant-supported over denture (ISOD).^[1]

The conventional dentures have been the treatment of choice for the edentulous patients for a long time. However, the patients usually have complaints of mandibular denture with problems such as lack of stability and retention because edentulous mandible loses four times more bone volume than the edentulous maxilla. An average of 0.4 mm of mandibular anterior vertical resorption occurs each year. These factors cause problems such as patients experiencing pain while eating and chewing, also arouses concerns about the denture loosen while eating, speaking, or laughing and report fears about the negative effect of dentures on social situations.^[2]

ISODs offer better stability and retention of the mandibular denture, better chewing function, and reduce further bone loss. The patients also report greater satisfaction with esthetics because the denture is not visibly moving. Implants reduce further bone resorption, and the long-term success rate of implants in the lower mandible is 95% with few serious complications.^[3]

According to The McGill and York consensus statements on overdentures, which was published following a symposium, held at McGill University in Montreal, Canada in 2002, “The evidence currently available suggests that the restoration of the edentulous mandible with a conventional denture is no longer the first-choice prosthodontic treatment. There is now overwhelming evidence that an ISOD has become the first choice of treatment for the edentulous mandible.”^[4]

In completely edentulous patient, implants which are used in conjunction with attachments to enhance the retention and stability of overdenture are considered as pillars of ISOD. It is very important for the clinician to have a good knowledge about different attachment systems, their advantages and disadvantages, indications, and contraindications for achieving long-lasting stable results because different clinical situations demand different types of attachment systems to serve better. To select a proper attachment, one should first understand the mechanical properties and the load distribution characteristics of different attachment systems.^[5]

For successful ISOD treatment, the evaluation of prosthetic space analysis is critical. For bar-supported overdenture, at least 13–14-mm interocclusal space is required considering teeth size, denture base thickness, bar thickness for the rigidity, the space from the mucosa to the bar for hygiene,

and the soft-tissue thickness. Minimum space requirement for ball attachment is 10–12 mm and for locators is 8.5 mm. Inadequate space for prosthetic components can result in an over-contoured prosthesis, excessive occlusal vertical dimension, fractured teeth adjacent to the attachments, attachments separating from the denture, fracture of the prosthesis, and overall patient dissatisfaction.^[6]

This study was, therefore, undertaken to evaluate and to compare the retention in implant-supported mandibular overdenture and their satisfaction level with three different attachment systems, i.e. ball-socket, bar-clip, and kerator attachments.

MATERIALS AND METHODS

Patient populations

Fifteen mandibular completely edentulous healthy patients in the age group of 35–65 years were selected for the study. Patients with uncontrolled diabetes and who were on intravenous bisphosphonate therapy were excluded from the study. Patients subjected to head-and-neck irradiation were also not counted for this study. After careful analysis of prosthetic space, the patients were divided into three groups, with five patients in each group:

- Group 1 - Ball and socket attachment group
- Group 2 - Bar and clip attachment group
- Group 3 - Kerator attachment group.

Surgical protocol

All patients were prescribed oral antibiotic (Augmentin 625 mg TDS) before the implant surgery, for 5 days. The radiographic template [Figure 1], which was fabricated while making the orthopantomogram (OPG) [Figure 2] for diagnostic purpose, was converted and utilized as a surgical template [Figure 3]. Implant was placed at B and D sites [Figure 4] under local anesthesia articaine (4%) with epinephrine (1:100,000). OPG was obtained to confirm the implant placement [Figure 5].

Prosthetic procedure

The prosthetic procedure was started 3 months after the first-stage surgery, and delayed loading protocol was followed and healing abutment was placed for 15 days [Figure 6]. The patients were divided into three groups.

Group I

Five patients were rehabilitated using ball and socket attachments (ADIN dental Implant System Ltd, Northern Israel) [Figure 7]. After the removal of healing abutment, the ball abutments [Figure 8a] were tightened by hand torque and torque wrench (30 Ncm). Separator was placed over the head of each ball abutment as a block

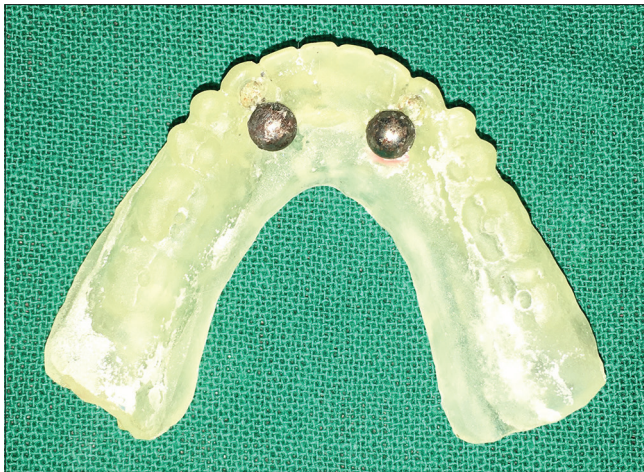

Figure 1: Radiographic stent

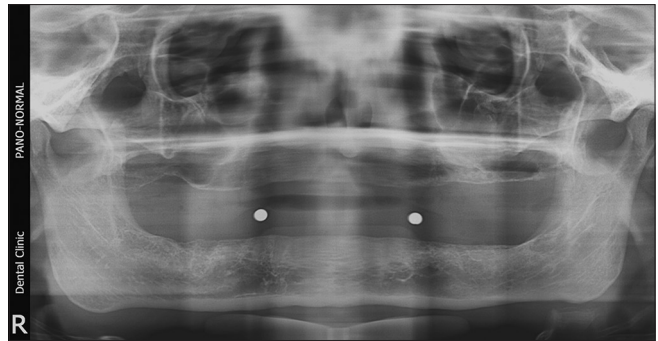


Figure 2: Digital pantomogram with radiographic stent

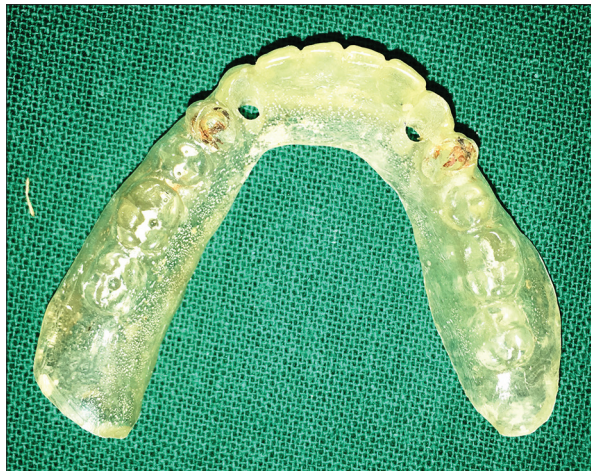

Figure 3: Surgical stent

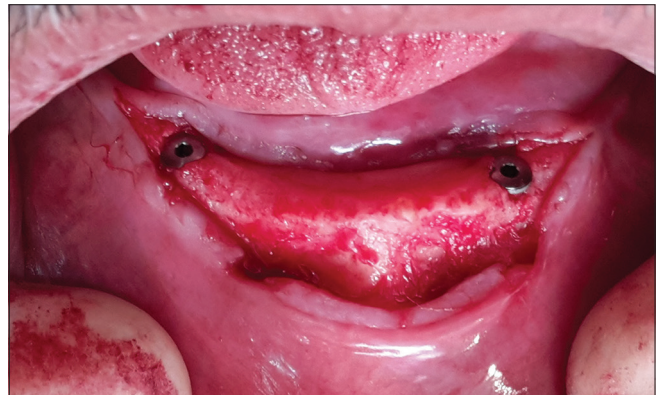

Figure 4: Implants with cover screw

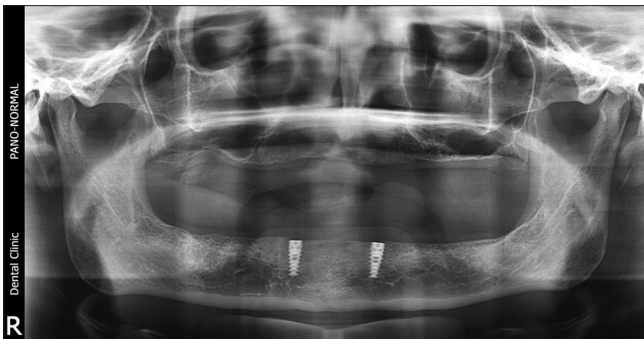


Figure 5: Digital pantomogram with implants in interforaminal region

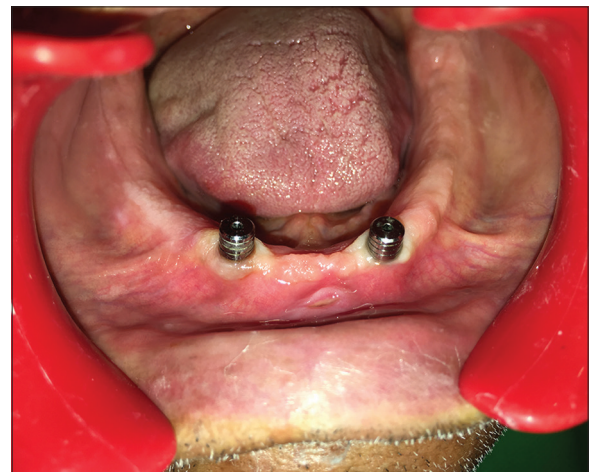

Figure 6: Healing abutments

out. Metal housings with nylon cap were inserted on the abutment, and recess was prepared in the denture. The vent hole was prepared on the lingual aspect to express resin. Autopolymerizing resin was mixed and placed in the recess of the denture, and the denture was inserted into position. After the resin had cured, denture was removed from the patient's mouth, and the excess material was trimmed and the denture was finished and polished [Figure 8b].

Group II

Five patients were rehabilitated using bar-clip attachments (CEKA PRECI-LINE, Belgium) [Figure 9]. After the removal of healing collars, pickup impression posts were placed at the implant level. An open-tray impression was made [Figure 10a], and the master cast was poured. On this master cast, nonengaging castable abutments were placed and were connected with a prefabricated plastic bar of 2-mm thickness and 3-mm height [Figure 10b]. The pattern was casted in a Co-Cr alloy using the standard

technique. Casting was than retrieved, finished, and highly polished to avoid any plaque accumulation along the bar. After verifying the passive fit, the metal framework was fitted intraorally [Figure 10c], and abutments were tightened by hand torque and torque wrench (30 Ncm). The under-surface was blocked with modeling wax on the mid-surface of the bar, and a plastic clip-metal housing assembly was placed. Recess was prepared in the denture. Autopolymerising resin was mixed and placed in the recess of the denture, and the denture was inserted into the position. After the resin had cured, denture was removed from the patient's mouth, excesses material was trimmed, and the denture was finished and polished [Figure 10d].

Group III

Five patients were rehabilitated using kerator attachments [Figure 11] (Hubermed U.K). After the removal of healing abutments, kerator abutment was engaged into the implant using carrier. Abutment was tightened by Hand torque and Wrench (30 Ncm) [Figure 12a]. White block-out spacer placed over the head of each kerator abutment [Figure 12b]. Metal housing was inserted with black cap on the abutment and recess was prepared in the denture. The vent hole was prepared on the lingual aspect to express excess resin. Autopolymerising resin was mixed and placed in the recess of the denture, and the denture was inserted into the position. After the resin had cured, the

denture was removed, and the white spacer was discarded. Black cap was removed from the metal housing, and blue color final cap was pushed into the metal housing using kerator magic tool. The denture was then finished and polished [Figure 12c].

Retention measuring device

An indigenous device was developed that allowed to apply an increasing vertical force on the denture. It has a straight metal bar that was fitted with strain gauges. The bar was rigidly connected to the denture. The patient was asked to keep his/her chin parallel to the floor, and the straight metal bar was inserted under the labial border of the mandibular denture. Bending of the bar with increasing vertical forces was registered by the strain gauges, and the applied load was expressed in mass and later force is being calculated and expressed in Newton. The applied force was gradually increased until it dislodged the denture. The test was repeated five times for each patient, and the mean was considered.^[7]

Assessment of patient satisfaction

To assess the level of satisfaction with different aspects of denture use, visual analog scale (VAS)-based questionnaire



Figure 7: Ball and socket attachment

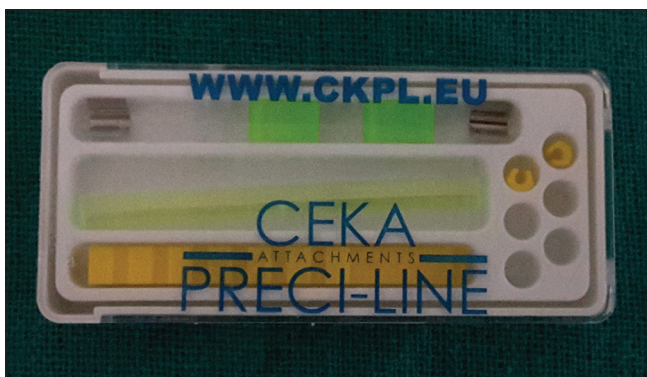

Figure 9: Bar and clip attachment

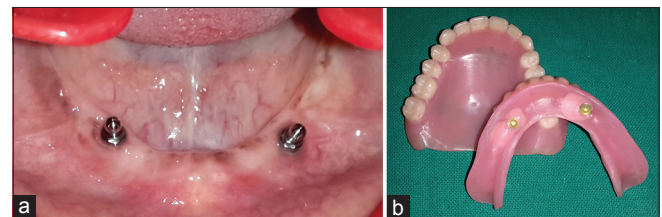


Figure 8: (a) Ball attachment. (b) Metal housing after incorporation in denture. (a and b) Prosthetic procedure for ball attachment

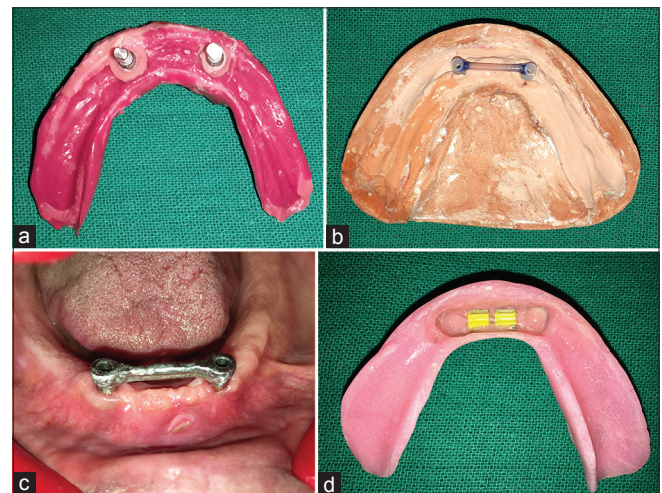


Figure 10: (a) Open tray implant impression. (b) Master cast with wax pattern. (c) Finished metal framework. (d) Final denture with metal housing and plastic clips. (a-d) Prosthetic procedure for bar and clip attachments

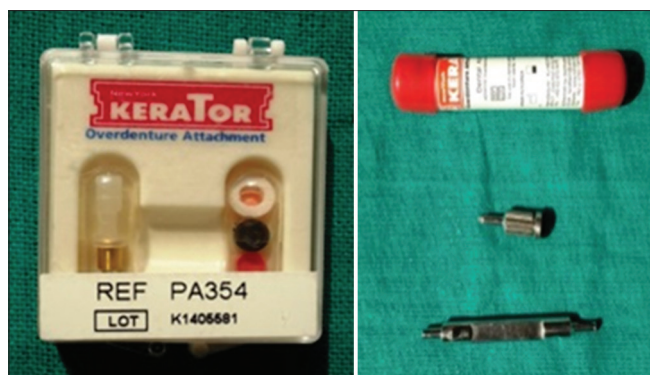


Figure 11: Kerator attachment

containing seven questions, was developed on the lines of previous studies.^[8] The VAS used was 100 mm in length with complete dissatisfaction at one end and complete satisfaction at the other end of the horizontal line on the scale. The patients were made to understand the method of answering the questionnaire by the same clinician and in a language that they could easily understand. Each question had to be answered by making a vertical mark intersecting the horizontal of the VAS. Retention and stability were assessed at rest, during chewing food, and during speech. The patients were also asked to rate the difficulty faced by them in chewing hard and soft food and also interacting with people while wearing the denture.

Measurements were performed at the time of installation of the attachment (prosthetic loading-around 3 months after implant placement) in the denture and after 6 months of function (around 9 months after implant placement), for all attachment types, respectively.

RESULTS

The mean retention (in Newton) was measured and compared at the time of loading and at 6 months after loading was compared between Group 1 (ball and socket attachment), Group 2 (bar and clip attachment), and Group 3 (kerator attachment) using the one-way analysis of variance (ANOVA) test. There was a significant difference in retention. The intergroup comparison of mean retention (in Newtons) at the time of loading and at 6 months after loading was done using the *post hoc* Bonferroni test. The mean retention at the time of loading and after 6 months of loading was significantly more among Group 3 (kerator attachment) in comparison to Group 1 (ball and socket attachment) and Group 2 (bar and clip attachment) [Table 1 and Graph 1].

The mean VAS score at the time of loading and 6 months after loading was compared between Group 1, Group 2,

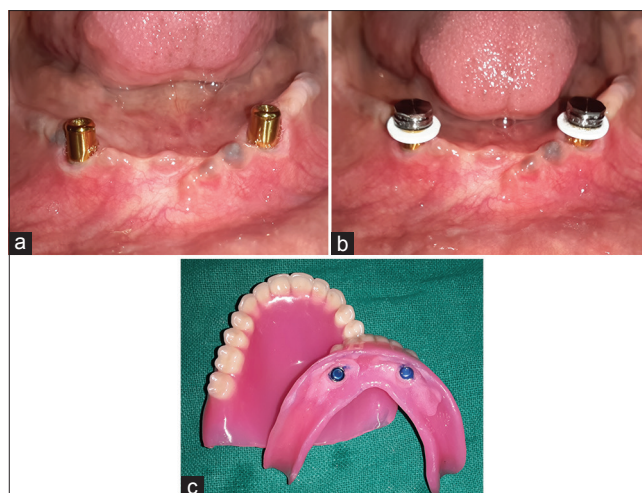


Figure 12: (a) Kerator attachment. (b) Kerator abutment with blackout rings. (c) Metal housing after incorporation into denture base. (a-c) Prosthetic procedure for kerator attachment

and Group 3 using the one-way ANOVA test. The mean VAS score at the time of loading and 6 months after loading was significantly more among Group 3 (kerator attachment) in comparison to Group 1 (ball and socket attachment) which was significantly more than Group 2 (bar and clip attachment) [Table 2 and Graph 2].

DISCUSSION

The conventional complete mandibular denture often exhibits poor retention, stability, and support in the patients with severely resorbed ridges. This result in marked difficulty in patients carrying out basic functions such as eating, speaking and leads to deterioration in satisfaction levels, and overall quality of life. Osseointegrated dental implants offer the possibility of stabilizing the complete denture prosthesis in such cases, thereby overcoming some of the limitations of conventional complete dentures.

Today, a multitude of implant and attachment systems are available for the fabrication of ISOD. Several studies have been reported the evaluation of the ball and bar attachment systems.^[9] On the other hand, there is a lack of clinical study which investigates the kerator attachment system.

There is strong evidence that retention is of great importance for the patient's satisfaction.^[7] In the literature, retention force is measured through objective means in both *in vitro* and *in vivo*.^[10,11] In the present *in vivo* study, the resistance against vertical dislodgement forces of the denture with kerator attachments is markedly higher than those of ball-socket and bar-clip attachments. Several studies evaluated the ball and bar attachments regarding

Table 1: Representing the mean retention (Newtons)

Retention (Newtons)	Mean	SD	F	P ^a	Significance	Post hoc comparisons ^b
At the time of loading (3 months after implant placement)						
Group 1	6.94	0.61	25.884	<0.001*	S	2, 3>1
Group 2	7.18	0.23				
Group 3	8.80	0.42				
6 months after loading						
Group 1	6.06	0.45	15.400	<0.001*	S	2, 3>1
Group 2	5.29	0.81				
Group 3	7.42	0.53				

^aOne-way ANOVA test, ^bPost hoc bonferroni test, *Significant difference. ANOVA: Analysis of variance, SD: Standard deviation

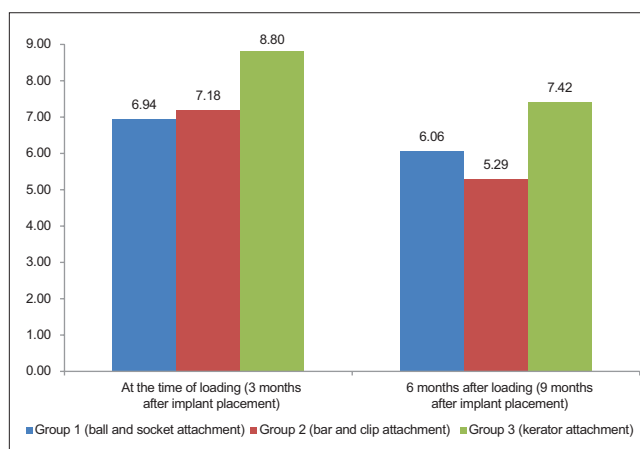
Table 2: Representing the mean visual analog scale score

VAS score	Mean	SD	F	P ^a	Post hoc comparisons ^b
At the time of loading					
Group 1	69.60	2.94	20.137	<0.001*	3>1, 2
Group 2	65.91	4.01			
Group 3	78.86	2.89			
6 months after loading					
Group 1	62.66	2.00	80.866	<0.001*	3>1 > 2
Group 2	57.11	1.87			
Group 3	72.69	2.01			

^aOne-way ANOVA test, ^bPost hoc bonferroni test, *Significant difference. ANOVA: Analysis of variance, SD: Standard deviation

the retention force and prosthetic complications. Cakarer *et al.*^[9] reported that solitary ball attachments appear to be less costly and less technique sensitive. However, ball attachments seem to be less retentive than the bar design. Naert *et al.*^[9] reported that single attachments provide lower retention than bars for the fixation of overdentures. In a multicenter study,^[9] on overdentures, where two implants were splinted, the need of clip activation was reported in 62% of the study group and clip fracture was reported in 33% of the patients. Walton *et al.*^[9] evaluated the prosthetic outcomes with implant overdentures, and reported that approximately 84% of the patients with ball-attachment dentures needed at least one repair, versus 20% of those with a bar-clip mechanism. On the other hand, Karabuda *et al.*^[9] reported that there were no differences in prosthetic complications for the ball and the bar attachment systems.

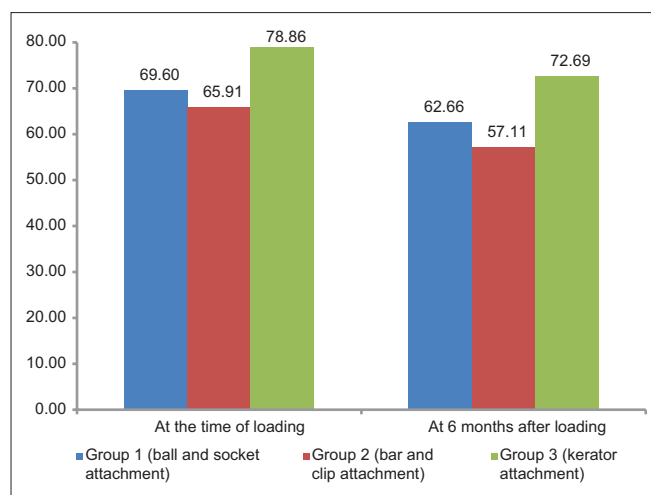
van Kampen *et al.*^[9] evaluated initial retention force, loss of retention force after 3 months of function, and postinsertion maintenance and complications associated with the use of magnet, bar-clip, and ball attachments in mandibular overdenture treatment. On the other hand, an *in vitro* study reported by Tokuhisa *et al.*^[9] showed that the use of the ball/O-ring attachment could be advantageous for implant-supported overdenture with regard to optimizing stress and minimizing denture movements. In the present study, one patient in the ball group and two patients in the bar group had complications associated with the attachments including replacement of attachment



Graph 1: Representing the mean retention (Newtons)

components, activation of attachment components, and attachment fracture. No retention problem was recorded in the kerator group.

Many investigators have evaluated mucosal reactions to different attachment systems. The majority of the clinical studies indicate that mucosal enlargements are most commonly found underneath maxillary prostheses regarding implant overdentures. Mucosal irritations and stomatitis were also commonly observed in maxillary overdentures. Payne *et al.*^[12] reported that there is a need for prospective reports to evaluate the incidence of mucosal enlargement with mandibular overdentures in relation to the design of the prosthesis and different dental implant systems. Klemetti *et al.*^[9] reported that to avoid soft-tissue problems in mandibular overdenture treatment with ball attachments; the amount of attached gingiva, as well as the pressure of the lip and the grade of alveolar atrophy, should be carefully assessed during treatment planning. If the labial musculature is tense or the amount of attached gingiva is limited, the implants should not be placed too deep or too labially, which might prevent gingival growth over the abutments. In the present study, the mucosal enlargements were observed in the mandible and only in the bar group. The common cause of this mucosal problem was associated with the lack of adequate attached gingiva.



Graph 2: Representing the mean visual analog scale score

In the present study, there was a significant difference in retention at the time of loading (3 months after implant placement) and at 6 months after loading (9 months after implant placement) between Group 1 (ball and socket attachment), Group 2 (bar and clip attachment), and Group 3 (kerator attachment). The intergroup comparison of mean retention at the time of loading and at 6 months after was significantly more among Group 3 (kerator attachment) in comparison to Group 1 (ball and socket attachment) and Group 2 (bar and clip attachment).

Patient's satisfaction has often evaluated as a treatment outcome in the field of dentistry. This has been done with the help of questionnaire covering different aspect of the influence that a particular treatment might have on a patient's lifestyle. In the present study, the questionnaire used for assessing the patient satisfaction level was similar to the one used by Awad *et al.*^[9] in 2003. A 100-mm VAS better reflect patient preferences and satisfaction levels as compared to a scale score^[10] and was thus used in the present study. The questions were asked in two languages (English and Hindi) to facilitate better understanding. The same clinician administered the question every time.

The mean score for the questions at the time of loading and 6 months after loading was compared between Group 1 (ball and socket attachment), Group 2 (bar and clip attachment), and Group 3 (kerator attachment). The same questions were asked at each interval.

The mean VAS score at the time of loading and 6 months after loading was significantly more among Group 3 (kerator attachment) in comparison to Group 1 (ball and

socket attachment) which was significantly more than Group 2 (bar and clip attachment).

CONCLUSION

Within the limitations of the study, the following conclusions were made:

1. All the attachment systems were useful. No significant difference was observed between the attachment systems regarding the implant failure, replacement of the attachment fragments, and fractured overdentures. However, ball and bar attachment fragments required more service. On the other hand, kerator attachment was found more advantageous to ball and bar systems with comparatively less incidence of postprosthetic complications
2. The ISOD loaded with kerator attachments gives higher degree retention as compared to ball-socket and bar-clip attachments
3. The ISOD loaded with kerator attachments gives a higher degree patient satisfaction as compared to ball-socket and bar-clip attachments within a short span of 6 months after implant loading.

Financial support and sponsorship

Nil.

Conflicts of interest

There are no conflicts of interest.

REFERENCES

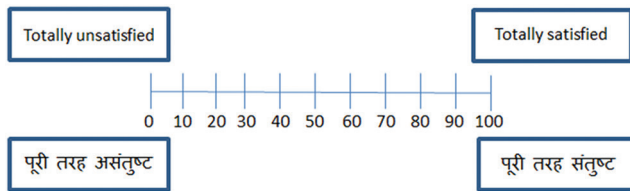
1. Mahajan N, Thakkur RK. Overdenture locator attachments for atrophic mandible. *Contemp Clin Dent* 2013;4:509-11.
2. Hyland R, Ellis J, Thomason M, El-Feky A, Moynihan P. A qualitative study on patient perspectives of how conventional and implant-supported dentures affect eating. *J Dent* 2009;37:718-23.
3. Burns DR. Mandibular implant overdenture treatment: Consensus and controversy. *J Prosthodont* 2000;9:37-46.
4. Thomason JM. The McGill consensus statement on overdentures. Mandibular 2-implant overdentures as first choice standard of care for edentulous patients. *Eur J Prosthodont Restor Dent* 2002;10:95-6.
5. Prasad DK, Prasad DA, Buch M. Selection of attachment systems in fabricating an implant supported overdenture. *J Dent Implants* 2014;4:176-1.
6. Ahuja S, Cagna DR. Defining available restorative space for implant overdentures. *J Prosthet Dent* 2010;104:133-6.
7. van Kampen F, Cune M, van der Bilt A, Bosman F. Retention and postinsertion maintenance of bar-clip, ball and magnet attachments in mandibular implant overdenture treatment: An *in vivo* comparison after 3 months of function. *Clin Oral Implants Res* 2003;14:720-6.
8. Awad MA, Lund JP, Dufresne E, Feine JS. Comparing the efficacy of mandibular implant-retained overdentures and conventional dentures among middle-aged edentulous patients: Satisfaction and functional assessment. *Int J Prosthodont* 2003;16:117-22.
9. Cakar S, Can T, Yaltirik M, Keskin C. Complications associated with the ball, bar and locator attachments for implant-supported

- overdentures. *Med Oral Patol Oral Cir Bucal* 2011;16:e953-9.
- Chung KH, Chung CY, Cagna DR, Cronin RJ Jr. Retention characteristics of attachment systems for implant overdentures. *J Prosthodont* 2004;13:221-6.
 - Türk PE, Geckili O, Türk Y, Günay V, Bilgin T. *In vitro* comparison of the retentive properties of ball and locator attachments for implant overdentures. *Int J Oral Maxillofac Implants* 2014;29:1106-13.
 - Kiener P, Oetterli M, Mericske E, Mericske-Stern R. Effectiveness of maxillary overdentures supported by implants: Maintenance and prosthetic complications. *Int J Prosthodont* 2001;14:133-40.

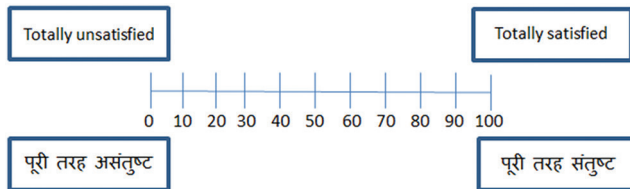
QUESTIONNAIRE

Questionnaire for patient satisfaction

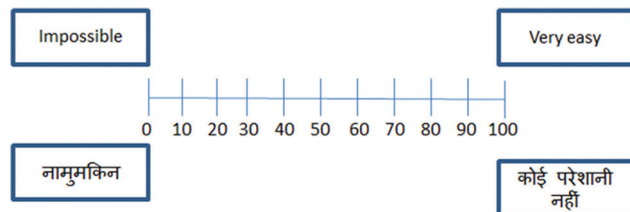
- How satisfied are you with the fit of the mandibular prosthesis in your mouth?
आपअपने नचिले डेन्चर (नकली दांतो) की पकड़ से कतिना संतुष्ट हैं?



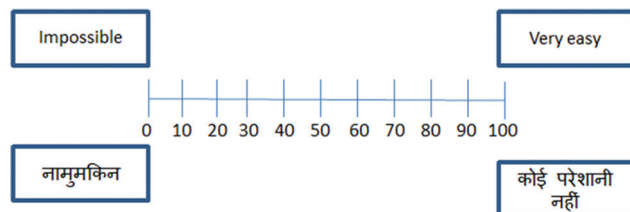
- How satisfied are you with the fit of the mandibular prosthesis in your mouth while chewing food?
आप खाना चबाने के वक़्त अपने नचिले डेन्चर (नकली दांतो) की पकड़ से कतिना संतुष्ट हैं?



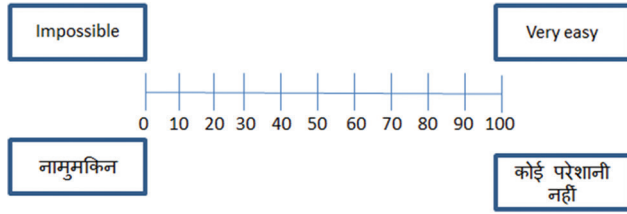
- How difficult is it for you to speak while using the dentures?
आपका डेन्चर (नकली दांत) लगाकर बोलचाल में कतिनी परेशानी होती है?



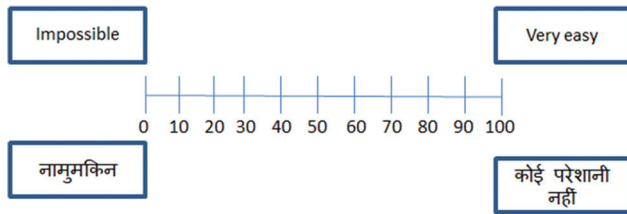
- How difficult is it for you to chew soft food using these dentures?
आपका डेन्चर (नकली दांत) लगाकर नरम खाना चबाने में कतिनी परेशानी होती है?



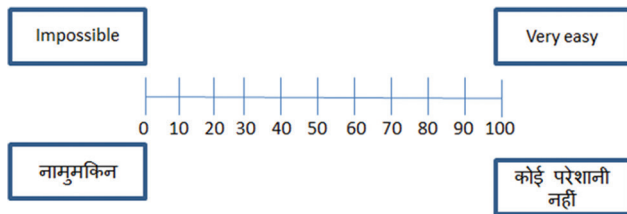
5. How difficult is it for you to chew firm/hard food using these dentures?
आपका डेन्चर (नकली दांत) लगाकर सख्त खाना चबाने में कतिनी परेशानी होती है?



6. How difficult is it for you to swallow food/fluids with these dentures?
आपका डेन्चर (नकली दांत) लगाकर खाना अथवा पानी नगिलने में कतिनी परेशानी होती है?



7. How difficult is it for you in interacting with other people while wearing these dentures?
आपका डेन्चर (नकली दांत) लगाकर दूसरे लोगो से मलिन जुलने में कतिनी परेशानी होती है?



Questionnaire filled: At the time of loading and 6 months after loading.

Patient's name: _____ Age/Sex: _____ self/father/mother: _____

Residence: _____ Phone: _____