

## Case Report

# A modified technique for fabrication of custom-made afterload brachytherapy appliance

Sumeet Jain, Namrata Agrawal<sup>1</sup>, Aparna Dwivedi<sup>1</sup>, Shobhit Bajaj<sup>1</sup>

Professor, <sup>1</sup>Post Graduate Students, Department of Prosthodontics, Sri Aurobindo College of Dentistry, Indore, Madhya Pradesh, India

**Abstract** Radiotherapy for carcinomas that involve the mouth and its related structures has been improved by the usage of different prostheses known as radiation carriers. These prostheses can accurately position radionuclide such as radium, iridium, cesium, and cobalt to allow adequate transfer of a concentrated radiation dose to a tumor region. At the same time, they minimize the exposure to radiation of nearby tissues due to rapid fall-off the radioactivity and thus minimizing the side effects of radiation. This study emphasizes the usage of a modified technique for the development of afterload mold brachytherapy appliance for squamous cell carcinoma patients of hard palate/soft palate.

**Keywords:** High-dose-rate brachytherapy, intraoral mold, radiotherapy, squamous cell carcinoma

**Address for correspondence:** Dr. Sumeet Jain, Department of Prosthodontics, Sri Aurobindo College of Dentistry, Crown and bridge, Indore Indore-Ujjain State Highway, Near M.R.10 Crossing, Indore, Madhya Pradesh, India.  
E-mail: [dentistsumeet@gmail.com](mailto:dentistsumeet@gmail.com)

**Received:** 07<sup>th</sup> January, 2018, **Accepted:** 17<sup>th</sup> March, 2018

## INTRODUCTION

The various therapeutic responses applied to malignant neoplasm of the mouth include surgical excision, radiotherapy, and chemotherapy. Radiation procedure is of two types: external beam radiation and intraoperative radiation therapy or brachytherapy. Cone beam computed tomography has now replaced the standard computed tomography (CT) in imaging and planning craniofacial defect reconstruction, and measurements were very accurate as compared to physical measurements.<sup>[1,2]</sup> But still, standard external beam radiation therapy is based on the assessment of target volumes to irradiate and organs at risk to protect in 3D-CT simulation plus multimodal images (e.g., positron emission tomography/CT, magnetic resonance imaging).<sup>[3]</sup> Brachytherapy is applied through

carriers. These carriers can be implants (interstitial), cone therapy, or surface molds. Brachytherapy can be used as either high dose-rate remote afterloading or low-dose-rate therapy.<sup>[4-6]</sup> In most carriers, which are previously described in the literature, the sources (radioactive) are placed and sealed individually within the carrier.<sup>[7-9]</sup> This procedure subjects the radiotherapist, patient, and the nurses to unnecessary subjection to the radiation sources during treatment. In the removable implantation procedure, hollow flexible tubes are situated in and around the tumor. Once in position, the isotopes (radioactive) are injected into the tubes. After radiotherapy, the entire apparatus is extracted from the tissues and the afterloading technique has been incorporated for use with surface applicators.<sup>[10,11]</sup> MacComb and Fletcher<sup>[12]</sup> stated, "For lesions of the hard palate, the multiple field arrangement must be designed to

Access this article online	
Quick Response Code:	Website: <a href="http://www.j-ips.org">www.j-ips.org</a>
	DOI: 10.4103/jips.jips_8_18

This is an open access journal, and articles are distributed under the terms of the Creative Commons Attribution-NonCommercial-ShareAlike 4.0 License, which allows others to remix, tweak, and build upon the work non-commercially, as long as appropriate credit is given and the new creations are licensed under the identical terms.

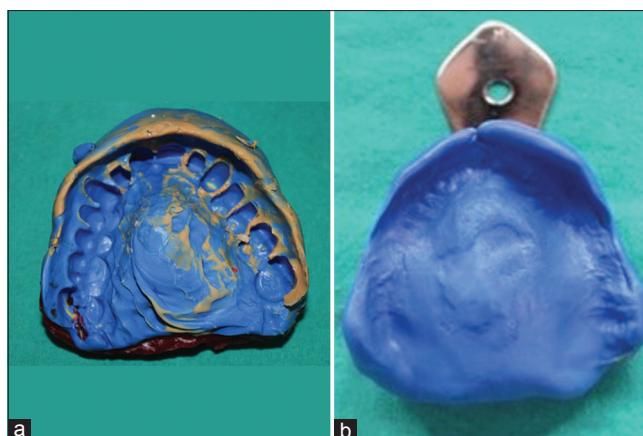
**For reprints contact:** [reprints@medknow.com](mailto:reprints@medknow.com)

**How to cite this article:** Jain S, Agrawal N, Dwivedi A, Bajaj S. A modified technique for fabrication of custom-made afterload brachytherapy appliance. *J Indian Prosthodont Soc* 2019;19:79-82.

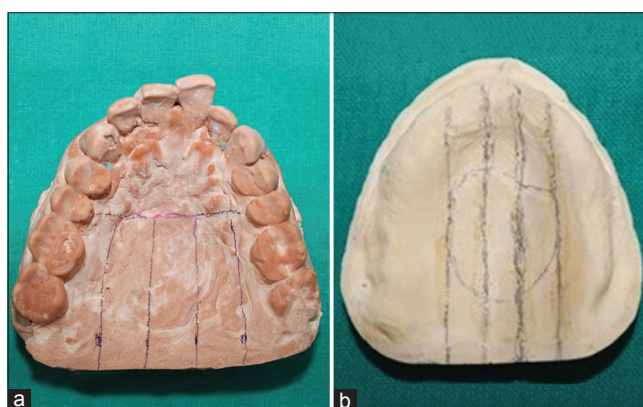
cover lesions of varying size and locations, surface molds can be used for superficial lesions.” This article describes a method of fabrication of two-piece surface molds for intraoral carcinoma to implement the need of proper loading of radioactive sources.

### MOLD PRODUCTION TECHNIQUE

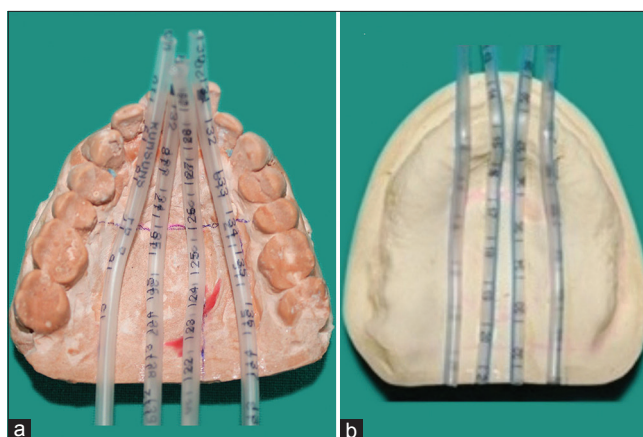
1. Impressions of the patient’s maxillary and mandibular arches were made with an elastomeric material and were poured with dental stone [Figure 1a and b]
2. The outline of the extent of the mold was marked after deciding the extent of tumor on the obtained cast [Figure 2a and b]. After the preliminary designing of the prosthesis, the number and positions of the carrier for radioactive sources were marked, in consultation with a radiotherapist
3. For the present cases of squamous cell carcinoma of the hard and soft palate, each dose of reference point was set by placing four parallel linings 1 cm apart, covering the external line of lesion in accordance, as suggested by a radiotherapist [Figure 2a and b]
4. Infant feeding tubes (“Feedy” Romsons scientific and surgical industries) with a diameter of 2.70 mm were stuck to the linings made. Stabilization of infant feeding tubes on the markings was done with the cyanoacrylate adhesive. The precaution was undertaken to avoid the wrenching of feeding tubes, so that radiotherapy source can be easily placed. Infant feeding tube of diameter 1.7 mm, similar to radioactive sources, was used to validate the patency of radioactive carrier tube [Figure 3a and b]
5. Then, the mold over the cast containing infant feeding tubes was fabricated, with the usage of clear auto polymerizing acrylic resin or thermoplastic resin sheet [Figures 4a, b and 5a, b]. The adequate clasps were used for the proper retention and adherence of the appliance
6. In another technique, 2-mm-thick thermoplastic resin sheet was used and pressed over the cast containing infant feeding tubes by the help of thermoplastic former. For the satisfactory retention of the appliance, occlusal and labial surfaces were incorporated in the manufacture of the appliance. Rest, all the procedures were similar
7. The final mold was then finished, polished [Figure 6a and b], and placed in the mouth, and necessary adjustments were made
8. With the lead wires and copper wires incorporated in the infant feeding tubes on the cast, radiation oncologists performed CT scan to reconfirm the patency of radiation carrier appliance and to plan the



**Figure 1:** Maxillary elastomeric impression: (a) dentulous, (b) edentulous



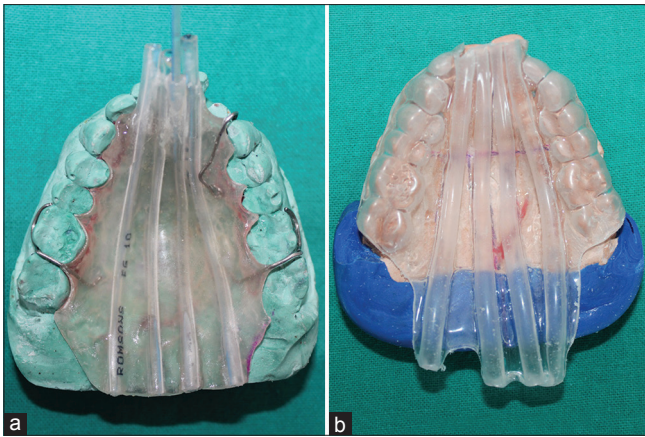
**Figure 2:** Markings of the outline on the cast: (a) dentulous, (b) edentulous



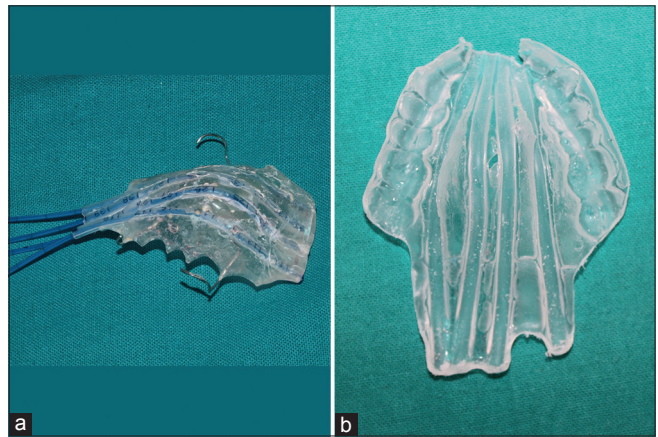
**Figure 3:** Attachment of infant feeding tubes on the cast: (a) dentulous, (b) edentulous

treatment procedure. After that, dummy checking was accomplished for placement and entry of radioactive sources and to start the whole treatment procedure [Figure 7a and b]

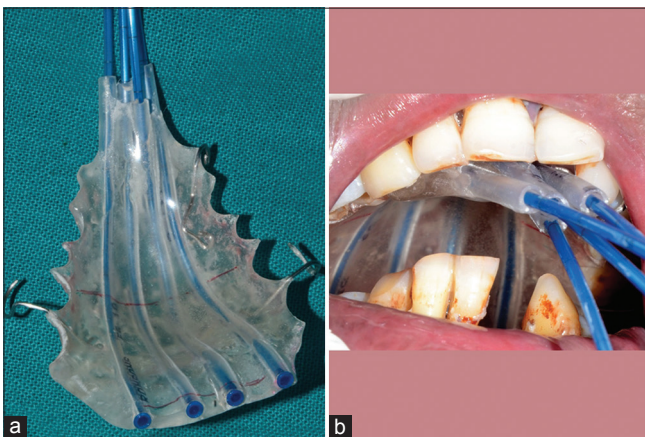9. Radiation oncologists then performed treatment procedure successfully, with the brachytherapy



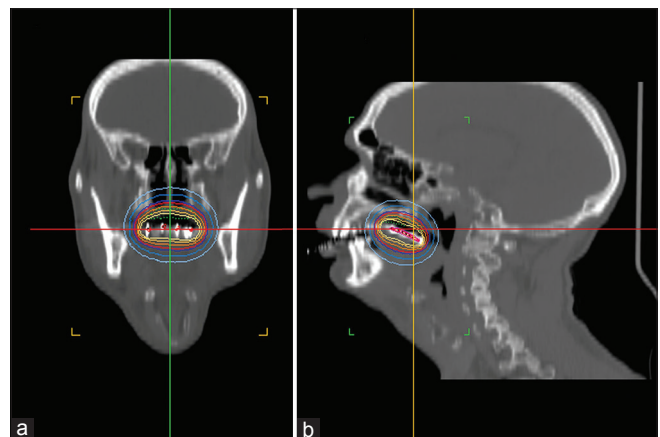
**Figure 4:** Afterload brachytherapy appliance on the cast: (a) clear acrylic resin, (b) thermoplastic resin



**Figure 5:** Intaglio surface of the mold: (a) clear acrylic resin mold, (b) thermoplastic resin mold



**Figure 6:** (a) Mold with radiation carriers, (b) mold placed intraorally



**Figure 7:** Computed tomography scan showing mold in position with radioactive sources: (a) horizontal view, (b) sagittal view

mold, and the patient was recalled for follow-up procedures.

## DISCUSSION

Previously irradiated and surgically excised head-and-neck squamous cell carcinoma patients have very less treatment options. Radical tumor resection with clear resection margins is difficult to accomplish, and repeated external beam radiotherapy carries a high threat of severe side effects. The technique was applicable to advanced or recurrent carcinomas only as a part of palliative therapy. Beumer *et al.*<sup>[13]</sup> briefly revealed this technique for radiation carriers in intraoral irradiation.

In previous studies, the mold was prepared with the help of flexible nylon tubes,<sup>[14]</sup> with either steel wires<sup>[6]</sup> or dummy seeds positioned within the tubes and sealed with auto polymerizing acrylic resin and in some studies, brachytherapy catheters<sup>[15,16]</sup> were also used; however, these catheters are more stiffer and are not flexible enough to get adapted easily without wrenching to treat intraoral carcinomas.

In this present technique, we constructed molds incorporating infant feeding tubes for contact brachytherapy to allow the adequate therapy of affected anatomical structures with difficult access. For the dentulous patient, the teeth were incorporated in the impression to provide stability; hence, movement during irradiation can be decreased. The patient can retain the mold intraorally for the necessary time without undue discomfort or excessive exposure of normal tissues. As a prosthodontist, we should be careful about the metallic alloy and nonremovable dental restorations and should convey to brachytherapist, as these restorations may cause a significant CT artifact and dose attenuation.<sup>[17]</sup>

The main advantage of this procedure is that it is economical; the infant feeding tubes reduces the price by almost 50% as compared to the other brachytherapy catheters used in previous studies.<sup>[1]</sup> Catheters have also been used for extraoral prosthesis like finger prosthesis; however, the type of catheter has not been specified.<sup>[18]</sup>

Our technique can also be used for such kind of extraoral prosthesis.

Multiple radioactive sources can be quickly and easily be placed; thus, exposure and time duration to the radiotherapist and the patient are minimized during the period of placement and activation of the prosthesis. The brachytherapy prosthesis can be suitable for the therapy of an intraoral malignancy with minimal patient morbidity. The primary disadvantage to this procedure is that brachytherapy may not be ideal for large tumor volumes, and thus, it requires the manufacture of delivery prosthesis to plan and adequately deliver the desired therapy dose.

### CONCLUSION

In the present case report, a modified economical method for fabrication of a radiation carrier with an adaptation of the afterloading technique has been described. The radiotherapist can place and position multiple sources simultaneously. This modified technique can also be used for small extraoral tumors also with minimal patient morbidity. This manuscript highlighted the role and responsibility of the prosthodontist in fabricating the radiation carrier and to maintain the predetermined position of the infant feeding tubes within the mold for placement and position of multiple sources simultaneously, which allows for well-adapted dose distribution to the tumor region as determined by the radiation oncologist for the desired results.

### Financial support and sponsorship

Nil.

### Conflicts of interest

There are no conflicts of interest.

### REFERENCES

1. John GP, Joy TE, Mathew J, Kumar VR. Applications of cone beam computed tomography for a prosthodontist. *J Indian Prosthodont Soc* 2016;16:3-7.
2. Michelinakis G. The use of cone beam computed tomography and three dimensional printing technology in the restoration of a maxillectomy patient using a dental implant retained obturator. *J Indian Prosthodont Soc* 2017;17:406-11.
3. Liu SH, Chao KS, Leu YS, Lee JC, Liu CJ, Huang YC, *et al.* Guideline and preliminary clinical practice results for dose specification and target delineation for postoperative radiotherapy for oral cavity cancer. *Head Neck* 2015;37:933-9.
4. Sela M, Taicher S. Intraoral radiation carrier for edentulous patients. *J Prosthet Dent* 1983;50:815-7.
5. Herring HW Jr., Greene PE. Use of a complete denture as a radiation carrier. *J Prosthet Dent* 1983;49:803-4.
6. Rudd KD, Pederson RE, Morrow RA, Green AE. Maxillary appliance for controlled radium needle placement. *J Prosthet Dent* 1966;16:782-7.
7. Kabcenell JL. A two-piece radiation therapy surface mold. *J Prosthet Dent* 1980;43:86-8.
8. Yaggi HK. An appliance which holds radioactive needles for treating morbid malignancies. *J Prosthet Dent* 1959;9:1066-8.
9. Dobson DP, Sowter JB, Webster WP, Johnson HF. Radium therapy appliance. *J Prosthet Dent* 1961;11:1166-9.
10. Joslin CA, Liversage WE, Ramsey NW. High dose-rate treatment moulds by afterloading techniques. *Br J Radiol* 1969;42:108-12.
11. Delclos L, Lopez-Cordovilla JJ. An after loading ear applicator to carry radium or substitute. *Radiologia* 1973;15:147.
12. MacComb WS, Fletcher GH. *Cancer of the Head and Neck*. Baltimore: Williams and Wilkins Co.; 1967. p. 150.
13. Beumer J, Curtis TA, Firtell DN. *Maxillofacial Rehabilitation: Prosthodontic and Surgical Considerations*. St. Louis: Mosby; 1979. p. 40-1.
14. Minsley GE, Rothenberg S. Use of the afterloading technique for intraoral radiation carriers. *J Prosthet Dent* 1985;53:676-8.
15. Rosen EB, Ko E, Wolden S, Huryn JM, Estilo CL. Intraoral angiosarcoma: Treatment with a brachytherapy prosthesis. *J Prosthet Dent* 2015;113:242-5.
16. Suma J, Sneha P, Shrestha S. Role of maxillo-facial prosthodontist to aid in brachytherapy for squamous cell carcinoma of palate with ancillary prosthesis: A case report. *JDOR* 2018;14:70-4.
17. Khan Z, Farman AG. The prosthodontist's role in head and neck cancer and introduction- oncologic dentistry. *J Indian Prosthodont Soc* 2006;6:4-9.
18. Wadhwa SS, Duggal N. A customized finger brachytherapy carrier. *J Indian Prosthodont Soc* 2014;14:326-9.