

Maxillary Posterior Bone Height in Relation to Maxillary Sinus Floor in Indian Dentulous Population

A. Jain · R. Chowdhary

Received: 25 November 2012 / Accepted: 6 March 2013 / Published online: 16 March 2013
© Indian Prosthodontic Society 2013

Abstract To establish a ratio of variable bone height (Infrazygomatic alveolar crest height) to constant bone height (Infraorbital zygomatic height) and, to estimate the relative sinus floor position from alveolar crest of maxillary first molar region of dentulous Indian males and females, using Digital panoramic radiographs. Panoramic radiographs of 74 patients were included in the study (37 male, 37 female) to measure maxillary posterior vertical bone height and their ratio in dentulous patients. Measurements were made from reference lines drawn from anatomic landmarks on soft digital versions of standardized panoramic radiographs using Kodak dental imaging software. Later the data were analyzed using normal test (*Z*-score). When the posterior maxillary bone height and their ratio were evaluated in Indian population, the vertical bone height (*x*, *y*, *z*) of males was more than the females. Ratio of Infrazygomatic-alveolar crest distance (*y*)/Infraorbital-zygomatic distance (*x*)-was 0.74 for Indian males and females. The relative sinus floor for Indian males was found to be 8.1 mm and that of Indian females to be 7.8 mm. The results are of significant value as “baseline” data, in serial studies where alveolar bone height for a single patient is compared at different times before and after tooth loss. The relative sinus floor position from alveolar crest can help in implant length selection. This study can be used as a diagnostic and predictive tool in

implant treatment planning but further long-term evaluation is still required to prove the efficacy of this study.

Keywords Dentate maxilla · Bone height · Posterior maxillary

Introduction

Prosthodontic studies [1, 2] have indicated the importance of knowing the location of the mandibular canal, the mental foramen, and the thickness of mucosal tissues, the integrity presence of alveolar extensions of the maxillary sinus as factors that can affect pre-prosthetic surgery and denture design. More recently, the increased use of dental implants to treat edentulous patients introduces an important element for prosthodontic treatment planning. The assessment of edentulous patients as candidates for implant therapy depends on radiographic imaging [3]. Studies have evaluated the vertical height of intact alveolar bone on panoramic radiographs of adult Caucasian population [4–6]. Indian race is definitely different from Caucasian population [4].

Estimation of the alveolar ridge has been done with various radiographic techniques, such as lateral cephalometric radiographs, panoramic radiographs and cone beam computerized tomography [7–11]. Panoramic radiography is commonly used in all clinical situations as the diagnostic tool and also for screening edentulous and dentate patients [12–17]. It is also a convenient radiographic approach for surveying dental conditions, providing information about most dental aspects with only one radiograph. Because the panoramic projection (pantomograph) is commonly used radiographic view in all disciplines of dentistry, methods of quantifying alveolar bone loss on panoramic films would be of value, particularly in clinical studies [4]. But due to

A. Jain
Department of Prosthodontics, S.Nijalingappa institute of dental sciences, Gulbarga 585105, India

R. Chowdhary (✉)
Branemark osseointegration center India, Golden plaza complex,
Court road, Gulbarga 585102, India
e-mail: drramc@yahoo.com

inherent difficulty in standardizing the head position among different patients and the differences in size and morphology of patients' jaws, it makes the use of absolute measurements from panoramic radiographs, of little value.

The purpose of this study was to establish a ratio of variable bone height i.e., the Infra zygomatic alveolar crest height to that of constant bone height (Infra orbital zygomatic height). Which can help in estimating the alveolar bone resorption, and to estimate the relative sinus floor position from that of alveolar crest in maxillary first molar region. Which was carried out in dentulous Indian males and females, using panoramic radiographs.

Materials and Methods

A total of 74 panoramic radiographs of 37 males and 37 females were evaluated to establish a ratio between a variable bone height (from most inferior point of infra zygomatic arch to alveolar crest between first and second molar region) to constant reference bone height (from Inferior part of the infraorbital notch to the inferior point of the infra zygomatic arch) for the maxillae and, to estimate the relative sinus floor position from alveolar crest of maxillary first molar region on panoramic radiographs. These Panoramic radiographs were procured from a Kodak 8000 digital panoramic system (Kodak, France). Criteria for selection of the subjects for the radiographs were similar to those used by Wical and Swoope [10].

1. Only films of adult patients 18 years of age or older were used.
2. All teeth in the regions of measurement had to be present and in normal relationship.
3. Evidence of alveolar crest resorption in the molar regions had to be minimal or absent.
4. The images of the mandible and maxillae could not be distorted; the size of the images of the posterior teeth could be neither magnified nor narrowed in the horizontal dimension.
5. The images of the orbits and zygomatic processes of the maxillae had to be clearly visible.
6. The space between the maxillary and mandibular teeth had to form a gentle arc such that the mid portion of the arc was lower than the ends.
7. The radiograph had to be free of artifacts in the sites being measured and
8. Both the left and right sides of the film had to meet the preceding criteria [10].

Measurements

A first horizontal reference line was drawn joining the most inferior border points of the right and left bony orbits (Lo).

Second horizontal reference line was drawn joining the inferior margins of the images of the right and left zygomatic processes of the maxillae (Lz). Third horizontal reference line was drawn joining the midpoint of alveolar crest margins of maxillary first molars on right side and left side (Lc). On both sides, a first vertical line was drawn perpendicular to the inter-orbital line (Lo) from the point where it intersected the inferior border of the orbit. This perpendicular line was extended, intersecting Lz and then further extended to meet a point at alveolar crest (in between the first and second maxillary molar region), this distance from the inter-orbital line (Lo) to the alveolar crest was designated as z. The distance from the inter-orbital line (Lo) to the zygomatic process line (Lz) was designated as "x", the distance from the zygomatic process line (Lz) to the alveolar crest (between first and second maxillary molar region) as "y". A second vertical line was drawn perpendicular to the intercrestal line (Lc) from the midpoint of alveolar crest in first molar region. This perpendicular line was extended to the inferior margin of maxillary sinus floor and this distance from the intercrestal line (Lc) to the inferior margin of sinus floor was designated as "h" These distances are illustrated in Fig. 1. All the measurements were made from reference lines drawn from anatomic landmarks on soft versions of standardized panoramic radiographs by Kodak dental imaging software (version 6.12.10.0).

Statistical Analysis

Statistical analysis of differences between right side and left side of males and females and also between males and females was performed with normal test (Z-score).

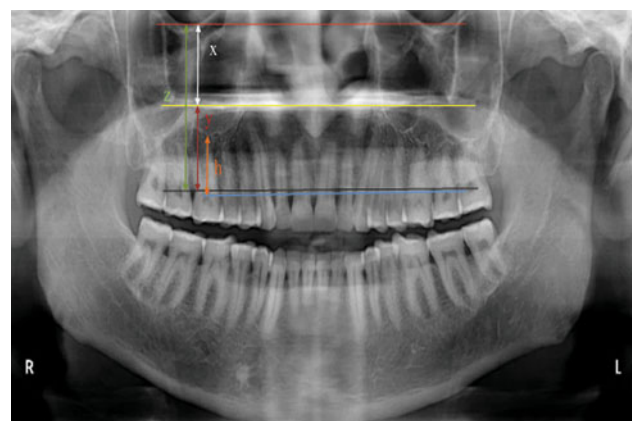


Fig. 1 Distances measured on radiographic images of maxillae: (x) from line joining most inferior points of borders of bony orbits to line joining inferior margins of images of zygomatic processes; (y) from zygomatic process line (described above) to alveolar crest in between maxillary first and second molar regions; (z) from the interorbital line to the alveolar crest; (h) from the intercrestal line to the inferior margin of sinus floor as h

Results

Seventy-four pantomographs from 37 male and 37 female subjects were investigated. Various vertical heights were measured between selected radiologic reference points in the maxilla (Table 1). Normal test (Z-score) was done to compare both (right and left) sides of males and females (Table 2). The vertical bone heights of the posterior maxilla were significantly greater in dentate males than in the dentulous females (Table 3). The means and standard deviations of y/x ratio for all radiographs studied are shown in Table 4. The means and standard deviations of relative sinus floor position for all radiographs studied are shown in Table 5 from the obtained results the following findings were found:

1. Vertical bone heights (x, y, z) of male are greater than that of female.
2. Ratio of Infra-zygomatic-alveolar crest distance (y)/Infra-orbital-zygomatic distance (x)-is 0.74 for Indian males and females. Infra-zygomatic-alveolar crest distance is 74 % of Infra-orbital-zygomatic distance for Indian males and females.
3. The relative sinus floor for Indian male was found to be 8.1 mm and that of Indian female to be 7.8 mm.

Discussion

Since there appear to be no reports of measuring intact alveolar bone height in the maxillae on radiographs in Indian population, this could be the first study to estimate the various heights of the fully developed dentate maxilla on pantomographs in Indian population. Many clinicians routinely use panoramic radiographs to assess alveolar ridge as a practical method of examination. However, according to the manufacturer, a magnification factor is present in the panoramic apparatus. The magnification factor of the Kodak 8000 digital panoramic system is 1.15. In the present study it was not necessary to correct the

Table 1 Mean, SD of x, y and z for right and left sides of male and female

		Right side				Left Side			
		Mean	SD	Max	Min	Mean	SD	Max	Min
Male	x	19.86	2.07	25.3	15.6	19.95	2.12	25.3	13.4
	y	14.42	1.88	20.1	11.1	14.57	1.78	20.2	11.9
	z	34.28	2.35	38.7	28.3	34.52	2.28	38.3	30.2
Female	x	18.70	2.11	24.7	14.2	18.82	2.05	22.9	15.0
	y	13.52	2.01	19.3	9.9	13.48	2.01	18.9	10.2
	z	32.22	2.48	37.6	26.7	32.30	2.51	37.6	27.1

Table 2 Z-score to compare between right and left side (for x, y, z) of male and female

Z-score		
Distance	Male	Female
x	0.38	0.33
y	0.33	0.09
z	0.43	0.19

Table 3 Mean, SD of x, y and z for male and female

Height	Male		Female		Z-score
	Mean	SD	Mean	SD	
x	19.91	2.10	18.74	2.08	2.41
y	14.49	1.78	13.49	2.01	2.27
z	34.40	2.32	32.23	2.49	3.87

Z-score to compare between male and female

Table 4 Mean, standard deviations for y/x ratio of male and female and Z- score to compare between male and female

	Male		Female	
	Mean	SD	Mean	SD
Right side	0.74	0.14	0.74	0.15
Left side	0.74	0.14	0.73	0.14
Total	0.74	0.14	0.73	0.15
Z-score	0.18			

All Z-scores (<1.96 for P = 0.05)

No statically significance between sex and sides for y/x ratio

Table 5 Mean, standard deviation of relative sinus floor position for male and female and Z-score to compare between male and female for sinus distance Z-score (<1.96 for P = 0.05)

	Male	Female
Mean	8.15	7.82
SD	2.31	2.22
Z-score	0.61	

No statically significance

radiographic heights for the magnification factor, because all radiographs were taken with the same panoramic apparatus [6]. Separate results for the maxillae for right and left sides of panoramic radiographs are given because during analysis of the maxillae on these films, it occasionally appeared that there were differences in the values of vertical heights between the right and left sides [4].

Larheim and Svanaes [18] investigated the precision of measurements of mandibular linear dimensions in panoramic radiographs and found that the variability of vertical measurements made from repeated panoramic radiographs

is small when patients are properly positioned in the panoramic apparatus. According to Xie et al. [19] if reference lines and measured points are located in the same vertical plane or in approximately the same plane as the teeth, variations in vertical measurements in the mandible and the posterior regions of the maxilla fall within a small range. Wical and Swoope [10] believed the lower edge of the mental foramen to be a useful reference mark in panoramic radiographs for estimating the amount of alveolar bone lost. They rationalized that the bone below the foramen constitutes a predictable proportion of the total bone height in most normal patients and is not significantly affected by resorption until extreme atrophy occurs. Alveolar ridge height was expressed as ratios instead of absolute measurements because differences in patient size and positioning of the patient may make absolute measurements less meaningful for purposes of comparison between patients and in the same patient at different times [4]. So the technique described here, established normal posterior maxillary bone height ratio and estimated relative sinus floor position from alveolar crest. Koivumaa [20] used a pantomographic assessment as part of his investigation into changes in periodontal tissues and supporting structures associated with partial dentures. Although he admitted that measurement of actual lengths could not be done accurately on pantomograms, he pointed out that “shifts of the object and the film along the roentgen beam cause no changes in the mutual relations of the different parts of the images, provided the object and film retain their mutual position”. This would seem to justify the use of ratio in comparing alveolar bone height with other constant distances on the films.

This study shows that posterior maxillary vertical bone height of Indian dentulous males is more than Indian dentulous females. But according to Saglam et al. [6] height of maxilla were not significantly different between men and women in dentulous patients of Turkish population. Ratio of Infra-zygomatic-alveolar crest distance (y)/Infra-orbital-zygomatic distance (x) is 0.74 for Indian males and females so Infra-zygomatic-alveolar crest distance is 74 % of Infra-orbital-zygomatic distance for Indian males and females. According to Packota et al. [4] ratio (x/y) of constant bone {Infra-orbital zygomatic (x)} height to variable bone {Infra-zygomatic alveolar crest (y)} height is 1.2 in Canadian population which means that Infra-zygomatic-alveolar crest distance is 83 % of Infra-orbital-zygomatic distance. This study shows that bone height from alveolar crest of maxillary first molar region to inferior margin of sinus floor is 8.1 ± 2.3 mm in Indian dentulous males and 7.8 ± 2.2 mm in Indian dentulous females. According to Farina et al. [5] bone heights from alveolar crest of maxillary first molar region to inferior margin of sinus floor is 9.1 ± 3.8 mm in Italian population.

This study increases the usefulness of the ratio reported here as “baseline” data to accurately estimate the degree of maxillary alveolar bone loss in studying a panoramic radiograph of an person at different times. So, this method may be of greater value in studying sequential changes to estimate reduction in height of the maxillary alveolar process of a patient after tooth loss. Another conceivable use for the data obtained might be the predicting of relative long-term success of complete dentures for patients. For example, if the treatment plan for two patients of the same age includes full extractions and complete dentures, the individual with the higher y/x ratio may be able to wear complete dentures more successfully for a longer period of time, simply because more alveolar bone is available than in the other person. Patients with ratio on the low end of “normal” could more enthusiastically be encouraged to keep their teeth, if this is a reasonable treatment option. The relative sinus floor position from alveolar crest can help in implant length selection.

Conclusion

This study describes a method of estimating alveolar bone height on panoramic radiographs by using constant anatomic landmarks as reference points and calculating ratios of given distances between certain of these landmarks and relative sinus floor position from alveolar crest in dentate patients with no radiographic evidence of horizontal bone loss. The results may be of significant value as “baseline” data, in serial studies where alveolar bone height for a single patient is compared at different times before and after tooth loss. The relative sinus floor position from alveolar crest can help in implant length selection. This study can be used as a diagnostic and predictive tool in implant treatment planning but further long-term evaluation is still required to prove the efficacy of this study.

Acknowledgments We would like to thank Dr. Mahoorkar S, Professor, Department of Prosthodontics, for supporting our ideas during this study.

References

1. Lyman S, Boucher LJ (1990) Radiographic examination of edentulous mouths. *J Prosthet Dent* 64:180–182
2. Perrelet LA, Bernhard M, Spirgi M (1977) Panoramic radiography in the examination of edentulous patients. *J Prosthet Dent* 37:494–498
3. Bremner VA, Grant AA (1971) A radiographic survey of edentulous mouths. *Aust Dent J* 16:17–21
4. Packota GV, Hoover JN, Neufeld BD (1988) A study of the height of intact alveolar bone on panoramic radiographs of adult patients. *J Prosthet Dent* 60:504–509
5. Farina R, Pramstraller M, Franceschetti G, Pramstraller C, Trombelli L (2011) Alveolar ridge dimensions in maxillary

- posterior sextants: a retrospective comparative study of dentate and edentulous sites using computerized tomography data. *Clin Oral Implant Res* 22:1138–1144
6. Saglam AA (2002) The vertical heights of maxillary and mandibular bones in panoramic radiographs of dentate and edentulous subjects. *Quintessence Int* 33:433–438
 7. Humphries S, Devlin H, Worthington H (1989) A radiographic investigation into bone resorption of mandibular alveolar bone in elderly edentulous adults. *J Dent* 17:94–96
 8. Mercier P, Lafontant R (1979) Residual alveolar ridge atrophy: classification and influence of facial morphology. *J Prosthet Dent* 41:90–100
 9. Tallgren A, Lang BR, Walker GF, Ash MM (1980) Roentgen cephalometric analysis of ridge resorption and changes in jaw and occlusal relationships in immediate complete denture wearers. *J Oral Rehabil* 7:77–94
 10. Wical KE, Swoope CC (1974) Studies of residual ridge resorption. Part I. Use of panoramic radiographs for evaluation and classification of mandibular resorption. *J Prosthet Dent* 32:7–12
 11. Wilding RJC, Levin I, Pepper R (1987) The use of panoramic radiographs to measure alveolar bone areas. *J Oral Rehabil* 14:557–567
 12. Scandrett FR, Tebo HG, Miller JT, Quigley MB (1973) Radiographic examination of the edentulous patient. I. Review of the literature and preliminary report comparing three methods. *Oral Surg Oral Med Oral Pathol* 35:266–274
 13. Saxen L, Aula S, Westermarck T (1977) Periodontal disease associated with Down's syndrome: an orthopantomographic evaluation. *J Periodontol* 48:337–340
 14. Davis WH, Delo RI, Ward WB et al (1975) Long-term ridge augmentation with rib graft. *J Maxillofac Surg* 3:103–106
 15. Van Waas MAJ (1983) Ridge resorption in denture wearers after vestibuloplasty and lowering of the floor of the mouth, measured on panoramic radiographs. *Dentomaxillofac Radiol* 12:115–121
 16. Davis WH, Martinoff JT, Kaminishi RM (1984) Long-term follow-up of transoral rib grafts for mandibular atrophy. *J Oral Maxillofac Surg* 42:606–609
 17. Tammsalo EH (1964) Dimensional reproduction of the image layer in orthopantomography. *Suom Hammasliik Toim* 60:2–12
 18. Larheim TA, Svanaes DB (1986) Reproducibility of rotational panoramic radiography: mandibular linear dimensions and angles. *Am J Orthod Dentofac Orthop* 90:45–51
 19. Xie Q, Wolf J, Ainamo A (1997) Quantitative assessment of vertical heights of maxillary and mandibular bones in panoramic radiographs of elderly dentate and edentulous subjects. *Acta Odontol Scand* 55:155–161
 20. Koivumaa KK (1956) Changes in periodontal tissues and supporting structures connected with partial dentures. *Suom Hammaslaak Toim* 52:142–152