

Extra Oral Cementation of Implant Prosthesis: A Case Report

Rita Singh · Lanka Mahesh · Sagrika Shukla

Received: 9 August 2013 / Accepted: 23 August 2013 / Published online: 27 September 2013
© Indian Prosthodontic Society 2013

Abstract Extraoral cementation is a technique that utilizes a stock abutment and a laboratory fabricated crown that is cemented extra orally; the advantage of this technique is that the retained excess luting agent during intra-oral cementation, which can be a source of bacterial retention and cannot be observed radiographically and is not possible to remove with explorer all the time, does not get accumulated and can be trimmed off easily before the final placement of the crown. Thus this technique allows no retention of luting cement, providing better soft tissue contours, no soft tissue inflammation, no retention of plaque and no bone loss. In short it prevents implant failure related to retained cement around implants. This technique provides overall health of peri-implant soft tissues as compared to conventional technique of crown placement where cement retention is a common problem, leading to implant failures.

Keywords Laboratory fabricated crown · Extra oral cementation · Healthy peri-implant soft tissues · Stock abutment

Introduction

The crown is the most important part of implant placement, fulfilling the very purpose of prosthetic rehabilitation. Supported crown restorations may be retained either by

retrievable screws or cement. And both these types have merits and demerits.

Screw retained crowns offer a rigid connection between the restoration and the abutment, as well as retrievability [1] but the main disadvantage is of screw loosening in 50 % of restorations during the first year in function [2], a phenomenon that was also observed in 43 % of single-tooth implant crowns [3]. These crowns are also expensive. To overcome such problems cement retained crowns were introduced. The problem with cement retained crowns was the difficulty associated with visualizing and removing excess cement at the crown margin [1].

On the other hand cement retained implant prostheses provide easier access to the posterior section of the mouth, reduced costs, reduced complexity of components and laboratory procedures, and reduced chair-side time and superior esthetics, which is important from the patient's perspective [4]. However, cement retained implant restorations may cause soft tissue infection. According to Pautetto et al. [1] Cement retained crowns cause rapid onset of complications such as peri-implant inflammation associated with swelling, soreness, deeper probing depths, bleeding and/or exudation on probing, and radiographic loss of peri-implant bone. There was plaque deposition and a shift of microflora, with an increase in gram-negative anaerobic bacteria [5]. Another important factor to be considered is the type of cement used for luting purpose.

Weber et al. [6], in his study stated that, soft tissue surrounding screw retained implant crowns was found to be healthier than soft tissue surrounding cemented restorations. Thus to overcome soft tissue infection arising due to cement retained implants a method known as extra oral fixation was developed. The method is simple, as the name suggests, the crown is cemented extra orally and then placed on the implant. The advantage of this technique is superior

R. Singh
Kathmandu, Nepal

L. Mahesh (✉) · S. Shukla
New Delhi, India
e-mail: drlanka.mahesh@gmail.com

esthetics, no difficulty in removing excess cement, no passage of cement into the gingival sulcus, no soft tissue infection. It is advised that all ceramic crowns should be extra orally cemented.

The latest concept for a better biocompatible environment is extraoral cementation where the crown is cemented extra orally and then placed in the patient's mouth. The main advantage of extraoral cementation is that as cementation takes place on the model, the emergence contours can be ideally created in the crown regardless of gingival margin position. Other advantages are no retention of luting cement, provides better soft tissue contours, no soft tissue inflammation, no retention of plaque and no bone loss, no bacterial growth and no implant failure.

Material and Method

A 38 year-old male with a history of aggressive periodontitis presented with inability to chew food from the right side. He had missing upper molars but the premolars were in a functional state. Since the lower premolars were missing, shortened dental arch concept was planned to meet the requirements of a functional dentition.

Under profound anaesthesia, two implants 4.5/9.5 mm and 4.5/8 mm (Ankylos) were placed in the edentulous region distal to the canine. The implants were placed 1 mm subcrestally. Postoperative instructions and medications were given. Amoxicillin 500 mg was prescribed for 5 days. Sutures were removed after 7 days.

After 3 months of uneventful healing, gingival formers were placed for 2 weeks. The gingival collars appeared well formed. The impression was made with open tray technique and the metal trial was done. Three-unit bridge was fabricated with the holes occlusally in straight line access with the abutment screw channel. Using the pattern resin jig, the abutments were hand tightened in the implants. The prosthesis was then seated on the abutments and its passive fit verified intra-orally. The occlusion was checked at this phase. The abutment screws were loosened and the abutments transferred to the cast again.

Extraoral Cementation Technique

The abutment channels were blocked with the cotton pellets in order to avoid cement getting into it. The luting cement (GC FujiCEM) was applied around the abutments and the prosthesis was seated completely. The excess cement seen on the surface was easily removed. This obviated the possibility of cement lodging in the sulcular region, which can facilitate plaque retention and subsequent changes in the adjacent mucosa.

The prosthesis was then placed intra-orally in the implants and screwed to the required torque. Temporary restorative material (Cavit) was placed in the abutment channels and the holes restored with the composites (Ceram X Duo) to match the shades (Figs. 1, 2, 3, 4, 5, 6).

Discussion

As an alternative to intraoral cementation, extraoral cementation is advantageous in many ways and can be fabricated with an occlusal screw access hole, allowing for the crown to a stock or CAD/CAM abutment on the laboratory model.

The mechanical advantage of the screw is that it can overcome soft tissue resistance, creating restoratively directed gingival contours. Utilizing extraoral cementation provides easy and complete cement removal and the opportunity to polish the abutment-crown interface after cementation and prior to intraoral placement which does not leave rough margins creating a nidus for plaque attachment and its retention. In addition, keeping its smooth surface in mind, thus created 'smooth' abutment-crown connection can be placed subgingivally, approaching the implant-abutment interface without the concern of intraoral cement removal. This also allows for porcelain to be placed subgingivally, hiding any metal in a shallow sulcus and obviating the possibility of metal exposure due to any future gingival migration.

The cementation will take place on the model, the emergence contours can be ideally created in the crown without regard to gingival margin position. Some have suggested that a vent hole in the cemented crown will allow cement escape, thus preventing apical cement expression. [7] It turns out that when utilizing extraoral cementation with a large occlusal screw access hole, there is usually cement expression apically along the abutment-crown margin. With extraoral cementation, this potentially destructive material can be easily and completely removed.

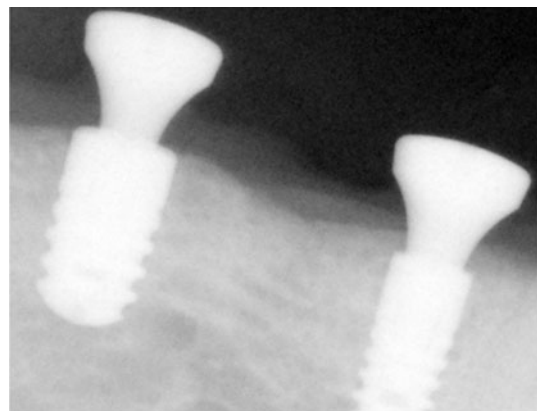


Fig. 1 IOPA of implants placed

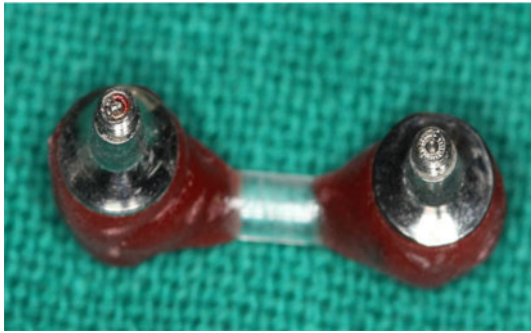


Fig. 2 Jig fabricated extra orally

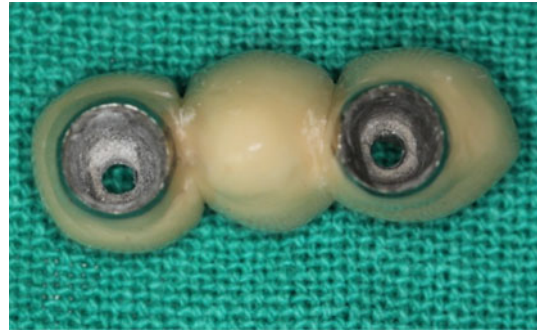


Fig. 5 Removal of excess cement

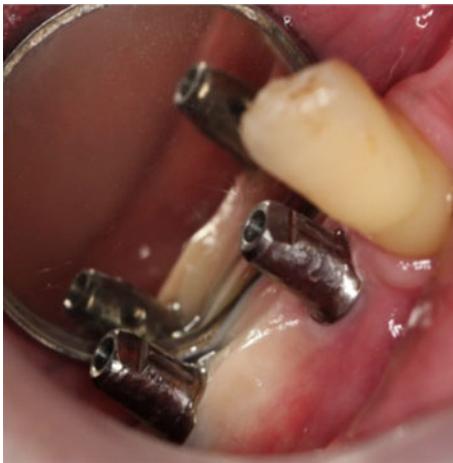

Fig. 3 Abutment intra-orally

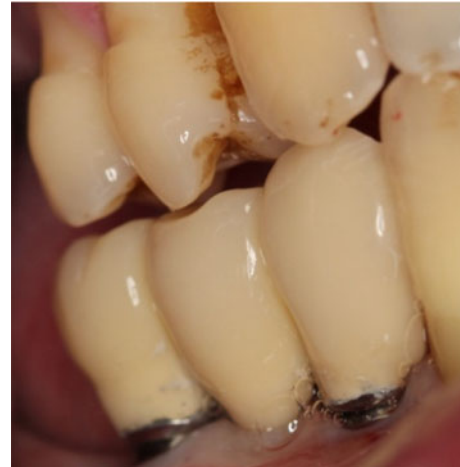

Fig. 6 Crown placement on implants

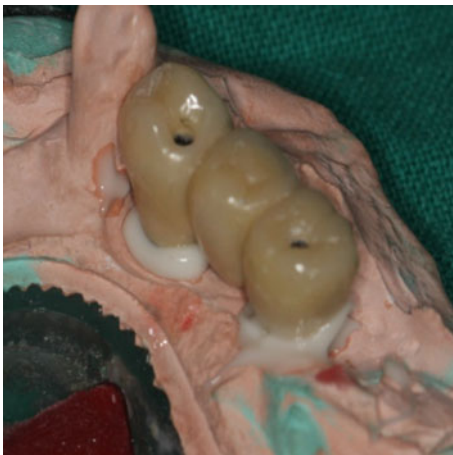

Fig. 4 Extra oral cementation

Conclusion

Extraoral cementation is a technique that utilizes a stock abutment and a laboratory fabricated crown that is cemented extra orally. This method eliminates the possibility of apical migration of cement due to hydrostatic forces and allows the restorative dentist complete control

over cement removal. In addition, post-cementation polishing of the abutment-crown interface is possible.

The patient had aggressive periodontitis, where keeping patient's healthy gingival and prevention of luting agent seeping into pocket was of utmost importance, thus this treatment was decided to safe guard further periodontal health issues in the patient and hence Extraoral cementation was chosen. On periodic recall and check-up patient showed healthy gingival conditions with improvement in gingival contours and no signs of inflammation.

This technique can not only be used for periodontally compromised patients but for all patients for maintenance of gingival health. All these features of extra oral cementation provide better soft tissue contours, no soft tissue inflammation, no retention of plaque and no bone loss, in short in prevents implant failure related to retained cement around implants.

References

1. Pauletto N, Lahiffe BJ, Walton JN (1999) Complications associated with excess cement around crowns on osseointegrated

- implants: a clinical report. *Int J Oral Maxillofac Implant* 14:865–868
2. Jemt T, Lekholm Y, Gröndahl K (1990) A 3-year follow-up study of early single implant restorations ad modum Brånemark. *Int J Periodontics Restorative Dent* 10:341–349
 3. Ekfeldt A, Carlsson GHE, Borjesson G (1994) Clinical evaluation of single-tooth restorations supported by osseointegrated implants: a retrospective study. *Int J Oral Maxillofac Implant* 9:179–183
 4. Hebel KS, Gajjar RC (1997) Cement-retained versus screw-retained implant restorations: achieving optimal occlusion and esthetics in implant dentistry. *J Prosthet Dent* 77:28–35
 5. Lang NP, Kiel RA, Anderhalden K (1983) Clinical and microbiological effects of subgingival restorations with overhanging or clinically perfect margins. *J Clin Periodontol* 10:563–578
 6. Weber HP, Kim DM, Ng MW et al (2006) Peri-implant soft-tissue health surrounding cement- and screw- retained implant restorations: a multi-center, 3-year prospective study. *Clin Oral Impl Res* 17:375–379
 7. Patel D, Invest JC, Tredwin CJ et al (2009) An analysis of the effect of a vent hole on excess cement expressed at the crown-abutment margin for cement-retained implant crowns. *J Prosthodont* 18:54–59