

# Implant Supported Prosthesis After Ridge Augmentation Procedure by Distraction Osteogenesis for Atrophic Mandible

Arlingstone Khongshei · Saurav Banerjee ·  
Tapas Gupta · Ardhendu Banerjee

Received: 2 June 2011 / Accepted: 14 December 2012 / Published online: 10 January 2013  
© Indian Prosthodontic Society 2013

**Abstract** Rehabilitation of deficient alveolar ridges has long been a challenge. The distraction osteogenesis procedure before placement of dental implants has solved the puzzle and its advantages over block grafting includes simultaneous expansion of soft tissue, high degree of dimensional stability, abbreviated overall treatment time, and no graft required. In this case report distraction osteogenesis of deficient anterior mandibular ridge was performed and then an implant supported fixed prosthesis was fabricated.

**Keywords** Distraction osteogenesis · Dentscan · Vertical cantilever

## Introduction

Rehabilitation of partially edentulous patients with osseointegrated implants has become the order of the day. However, unfavourable conditions of the alveolar ridge may provide insufficient bone volume for implant place-

ment. A vertical defect of the alveolar ridge is still a particular challenge as this leads to an increase in crown height space leading to increased stresses on the implants. The crown height space acts as a vertical cantilever and a force magnifier. In these situations surgical procedures, such as inlay or onlay bone grafts, vertical guided bone regeneration (GBR) and alveolar distraction osteogenesis are used to overcome the bone deficit then implant placement is planned [1].

Alveolar distraction osteogenesis is a process of new bone formation subjected to two fundamental biological principles (1) tension/stress effects, in which a force produces stress or strain and induces growth of soft tissue and bone and (2) load/morphology effects, in which loading and blood supply influence the shape and mass of skeletal segments. These principles are defined as Ilizarov effects [2].

It offers less overall treatment time, there is little or no bone resorption than standard staged bone grafting techniques and there is concomitant proliferation of attached gingiva, obviating the need for soft tissue augmentation [3, 4].

While other procedure includes gingiva colored prosthetic material may not favor biomechanics. Changing the prosthesis design to removable restoration might decrease the nocturnal parafunction but may not be acceptable to the patient.

## Case Report

A 26 year old male patient reported to the department with a chief complaint of difficulty in chewing and inability to talk and smile properly.

There was no relevant systemic history. He was a healthy patient with a vertically deficient anterior mandibular alveolar ridge due to loss of teeth because of accident.

---

A. Khongshei (✉)  
Pynursla, east khasi hills, Shillong 793110, Meghalaya, India  
e-mail: drsauravb@rediffmail.com

S. Banerjee  
Department of Prosthodontics, Awadh Dental College & Hospital, Jamshedpur, India

T. Gupta  
Department of Prosthodontics, Dr R Ahmed Dental College & Hospital, Kolkata, India

A. Banerjee  
Department of Prosthodontics, Kalinga Institute Of Dental Sciences, Bhubaneswar, India

On examination the teeth # 14, 15, 31–34, and 41–45 were missing. The anterior mandibular alveolar ridge height was deficient. The crown height space was found to be excessive (20 mm) (Fig. 1a, b). After considering the amount of crown height space required for implant supported prosthesis, it was decided to increase the alveolar height ridge by 10 mm. The patient consent was obtained and the procedure of mandibular distraction osteogenesis was decided to be undertaken in co-ordination with the maxillo-facial surgery department.

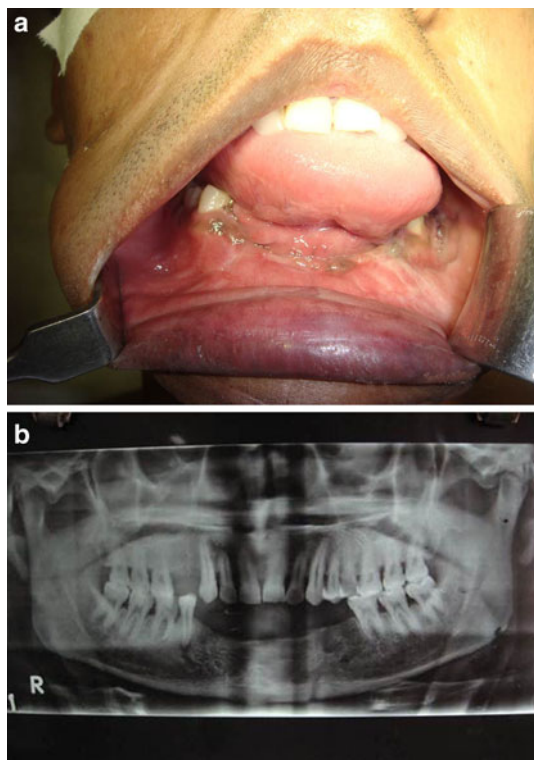
## Procedures

### Surgical Phase

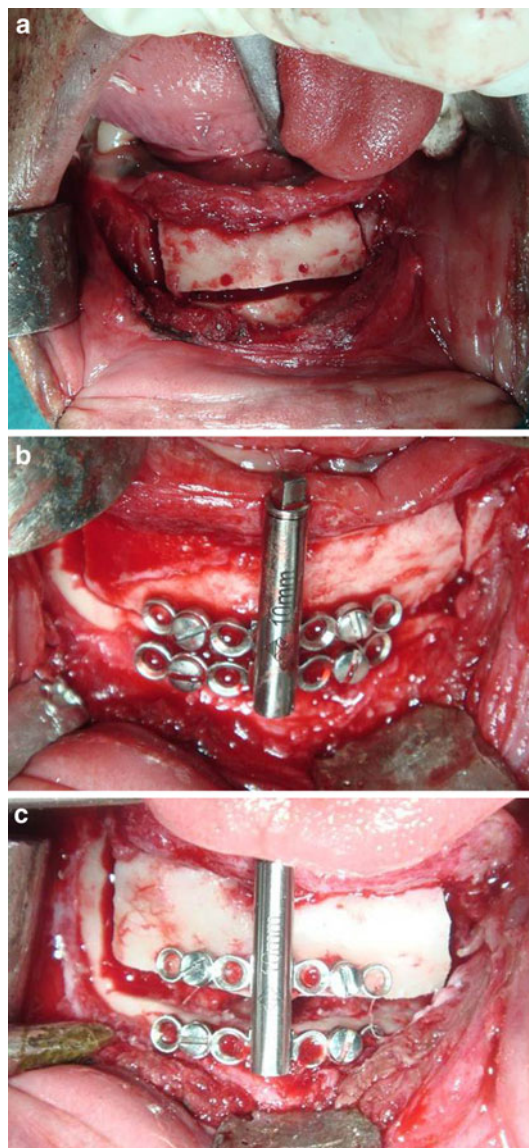
The distraction was carried out in two stages

Stage 1: placement of the distraction device and distraction (Fig. 2a–c).

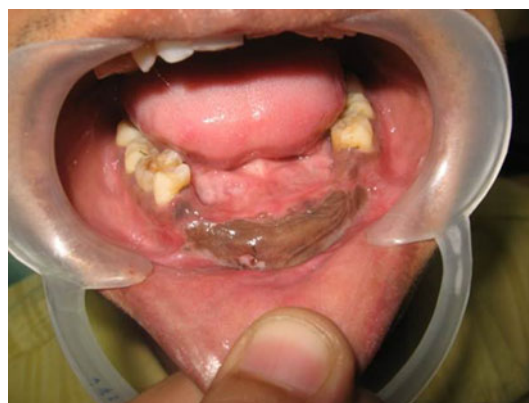Stage 2: surgical removal of the distraction device after the consolidation phase (usually 12 weeks period for adults). Around 10 mm of the anterior mandibular ridge height was increased by distraction osteogenesis. New bone formation was similar to fracture



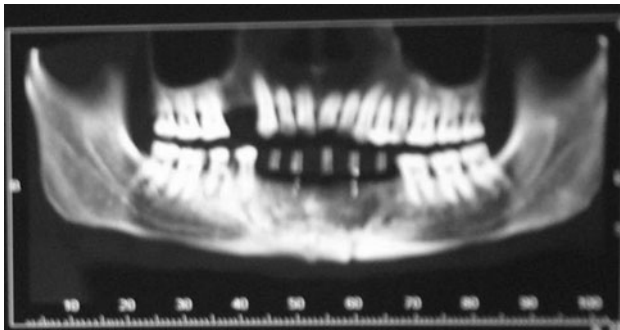
**Fig. 1** a Pre operative intraoral view. b Pre operative panoramic radiograph



**Fig. 2** a Osteotomy cut given. b Distractor inserted (activation stage). c Distraction completion stage



**Fig. 3** Partial thickness skin graft done



**Fig. 4** Dentascan with template

bone healing. Eventually the distraction regenerate was remodeled to mature bone.

After the distraction procedure was completed it was found that the soft tissue over the ridge was flabby and not conducive for implant placement. The second surgery was done to correct the flabby soft tissue of the ridge. Here a partial thickness skin graft was used (Fig. 3).

#### Radiographic Analysis

Three panoramic radiographs were taken, one immediately following the placement of the distractor, another after 12 weeks. The third one was taken after a year before implant placement for evaluation and diagnostic purposes.

#### Dentascan

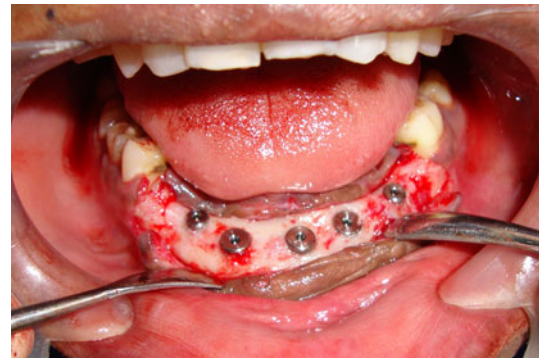Impressions of both arches were made with irreversible hydrocolloid material (Tropicalgin, Zhermack, Italy) and diagnostic casts were obtained. Mounting of casts were done on a semiadjustable articulator and a diagnostic wax up was done. A surgical template was fabricated with self-cure acrylic resin over the diagnostic wax up. Dentascan was then done to evaluate the bone height, width, length and angulation with the surgical template in the patient's mouth during the scanning procedure (Fig. 4).

#### Implant Phase (Stage 1)

After the diagnostic part it was decided to restore the missing teeth with implant supported prosthesis. Following the guidelines for key implant position (Carl E. Misch).

- (1) No three adjacent pontics
- (2) No cantilever
- (3) Canine-molar rule and
- (4) Arch dynamic [5].

After administration of local anesthesia (2 % of xylocaine with 1:200,000 epinephrine) a crestal incision was made with no. 15 B.P. blade and a full thickness flap was raised to access the alveolar bone. Five 4.2 mm diameter, 11.5 mm length



**Fig. 5** Placement of implants done at the proposed site

implants (EZ Hi-Tec implants, Israel) were inserted between and above the mental foramen. The exact position of the implant was marked using the surgical template (Fig. 5).

#### Prosthetic Phase

After 3 months of implant placement a panoramic radiograph was taken to evaluate the implant conditions in the bone. Then a second stage surgery was done to attach the per-mucosal extensions (PME). The PME was left in place for 2 weeks before impression was made.

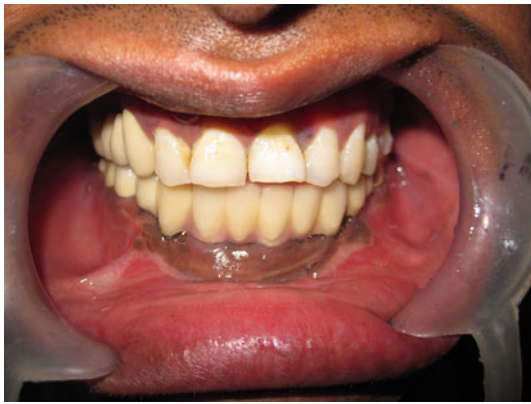Impression copings were attached to implants and an open tray impression technique using poly (vinyl siloxane) impression material (Reprosil, Dentsply, USA) was made. Implant analogs were attached to the impression coping and impression poured with type IV gypsum (Kalabhai Karson, Mumbai). This cast was mounted on Whip-mix articulator using the facebow transfer and a centric relation record.

Implant abutments were prepared for metal-ceramic restorations using the index of the diagnostic wax up as a guide. Provisional prosthesis (DPI dental products, Mumbai) were cemented with zinc oxide non eugenol cement (Freegenol, GC, India). Metal coping try in was done. Definitive prosthesis were cemented with GIC luting cement (Ketac Cem, 3M ESPE, Germany).

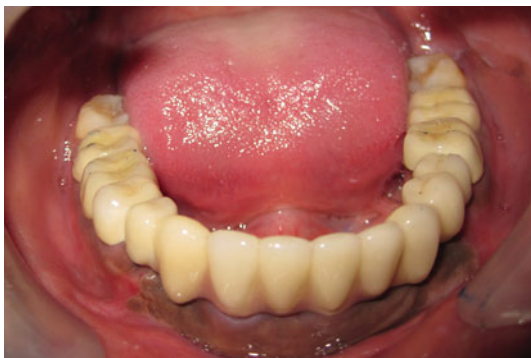The prosthesis was splinted as a single unit for uniform stress distribution. Implant protected occlusion protocol like mutually protected articulation, absence of premature occlusal contact and increased surface area were followed. Oral hygiene instructions emphasizing use of dental floss and proper brushing were given and follow-up was carried out at an interval of 6 weeks (Figs. 6, 7).

#### Discussion

The reconstruction objective is to obtain an alveolar ridge with proper ridge height and width along with the lengthening of the soft tissue. The above process was obtain by distraction osteogenesis procedure.



**Fig. 6** Post operative intraoral frontal view in occlusion



**Fig. 7** Postoperative intraoral occlusal view of the implant supported prosthesis

Under the control of the distraction device, the mobilized alveolar segment is transported coronal in a slow, incremental manner. The increase in the bone volume is due to regeneration of the distant, distraction zone that acts as regeneration chamber. The procedure offers less overall treatment time with little or no bone resorptions as compare to the grafting procedure, because it is the mature cortical bone that is transported on the surface to bare the maximum stress.

A preliminary morphologic classification of the alveolar ridge after distraction osteogenesis was devised to provide a useful basis for decision making regarding implant placement. Histological analysis confirmed that both bone quantity and quality after 1 year reached the degree of maturation

that mimics natural bone. It can be loaded under function after the consolidation phase [6].

The disadvantages of this technique would include patient discomfort with externally directed intraoral distraction device, difficulty with rigid control of the segments during distraction, lingual deviation of the transport segment [7–9].

### Summary

In the present case, taking into consideration the patient compliance, oral hygiene, and systemic fitness, the patient with vertically deficient mandibular alveolar ridge could undergo distraction osteogenesis as part of the pre-prosthetic procedure to receive the implant supported prosthesis.

### References

1. Sant S, Jagtap A (2009) Alveolar distraction osteogenesis: revive and restore the native bone. *J Prosthodont* 18:694–697
2. Consolo U, Bertoldi C, Zaffe D (2006) Intermittent loading improves results in mandibular alveolar distraction osteogenesis. *Clin Oral Implants Res* 17(2):179–187
3. Chiapasco M, Lang NP, Bosshardt DD (2006) Quality and quantity of bone following alveolar distraction osteogenesis in the human mandible. *Clin Oral Implants Res* 17(4):394–402
4. Chiapasco M, Zaniboni M, Boisco M (2006) Augmentation procedures for the rehabilitation of deficient edentulous ridges with oral implants. *Clin Oral Implants Res* 17(Suppl 2):136–159
5. Misch CE (2008) *Contemporary implant dentistry*, 3rd edn. Elsevier, St. Louis, p 147
6. Samchukov ML, Cope JB, Cherkoshin AM (2001) *Craniofacial distraction osteogenesis*. Mosby, St. Louis, pp 25–36
7. Raghoebar GM, Heydenrijk K, Vissink A (2000) Vertical distraction of the severely resorbed mandible. The Groningen distraction device. *Int J Oral Maxillofac Surg* 29(6):416–420
8. Uckan S, Haydar SG, Imirzalioglu P, Acar AG (2002) Repositioning of malpositioned segment during alveolar distraction. *J Oral Maxillofac Surg* 60(8):963–965
9. García García A, Somoza Martin M, Gandara Vila P, Gandara Rey JM (2004) A preliminary morphologic classification of the alveolar ridge after distraction osteogenesis. *J Oral Maxillofac Surg* 62(5):563–566