

Prosthetic Rehabilitation of Patient with Ameloblastoma: A Case Report

N. Kalavathy · K. Premnath · N. Jayanthi ·
Vijetha Jadav

Received: 2 April 2011 / Accepted: 3 June 2011 / Published online: 21 June 2011
© Indian Prosthodontic Society 2011

Abstract Loss of the continuity of the mandible destroys the balance and the symmetry of mandibular function, leading to altered mandibular movements and deviation of the residual fragment towards the surgical side. To regain normal mandibular function for surgical resection of the ameloblastoma, initial rehabilitation was done using avascular fibular bone graft. Prosthetic rehabilitation was done by Placement of four implants in the anterior region followed by fabrication of suprastructure using UCLA abutments and ceramic crowns.

Keywords Implant supported prostheses · Ameloblastoma rehabilitation · UCLA abutment

Introduction

Ameloblastoma is a slow growing benign tumour of the jaw and patients usually present late after the tumour achieved considerable size to cause facial disfigurement [1]. The most common site for ameloblastoma is mandibular molar region. Ameloblastoma of the jaw is an aggressive benign tumor of epithelial origin that has generally been treated surgically for metastases. It is the second most common odontogenic neoplasm.

Benign mandibular swellings can be due to a wide variety of lesions and can be divided into odontogenic and nonodontogenic origin. Ameloblastoma is the commonest benign tumour of odontogenic origin which developed

from epithelial cellular elements and dental tissues in their various phases of development. It is generally a slow growing but locally invasive tumour [1].

Its peak incidence is in the 3rd to 4th decades of life and the male to female ratio is 1:1 [1, 2]. It is often associated with an unerupted third molar (Gerzenshtein et al. [3]). It may present as a result of routine radiographic examination finding. 80% of ameloblastomas occur in the mandible and majority is found in the angle and ramus region [2, 3].

There are three forms of ameloblastomas, namely peripheral, unicystic, and multicystic tumors. Multicystic ameloblastoma is commonly seen among all and represent 86% of cases [2, 4]. Peripheral tumors are odontogenic tumors, with the histological characteristics of intraosseous ameloblastoma that occur solely in the soft tissues covering the tooth-bearing parts of the jaws. Unicystic tumors include those that have been referred to as “mural ameloblastomas”, luminal ameloblastomas, and ameloblastomas arising in dentigerous cysts (Chana et al. [5]).

Diagnosis mainly from tissue biopsy and characteristic findings on plain X-rays does assist in differentiating between types of ameloblastoma. The challenges in the management of this tumour is to provide complete excision and reconstruction of the bony defect in order to give reasonable cosmetic and functional outcome to the patient [1].

Case Report

A male patient named Mr. Harsha of 23 years old with swelling in the anterior mandibular region, visited out patient department of DAPMRV Dental College, Bangalore and after necessary investigation was diagnosed as ameloblastoma. Excision of the lesion followed by the resection of portion of the mandible and placement of avascular fibular

N. Kalavathy (✉) · K. Premnath · N. Jayanthi · V. Jadav
Department of Prosthodontics, D A Pandu Memorial R V Dental
College, CA-37, 24th Main, J P Nagar I phase,
Bangalore 560078, Karnataka, India
e-mail: drkalavathy@gmail.com

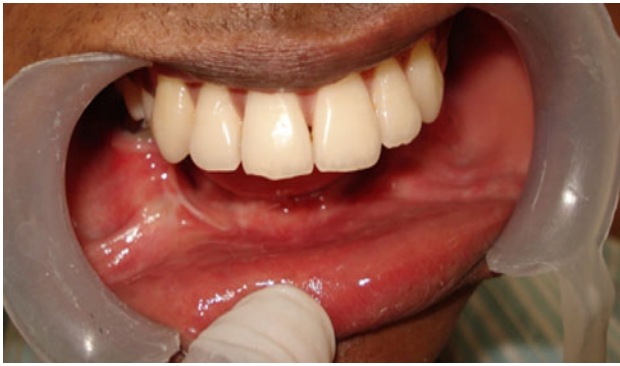

Fig. 1 Pre-operative view

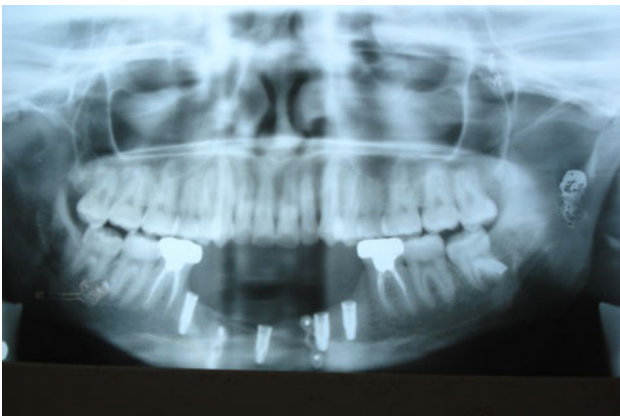


Fig. 2 OPG showing implant placement in the region of 31, 35, 43 & 44

bone graft was done and implant supported prostheses (progressive loading type) was planned.

Necessary investigations like study model intra oral radiographs were done and stent was fabricated and four implants of selected size namely 3.3 and 3.75 mm diameter and length of 12 mm were placed. After sufficient healing period second stage surgery was done and provisional restoration was fabricated (Figs. 1, 2).

It was observed that there was proliferation of tissues around provisionals because of which surgical intervention was inevitable. But sufficient inter ridge space was a boon because of which it was decided to go ahead with castable UCLA abutments for final prostheses (Figs. 3, 4, 5, 6).

Final Impression was made with open tray technique using transfer coping and addition silicone material. Once the cast was ready the UCLA abutments were placed in respective places and resin pattern was fabricated. This frame work was tried in the patient's mouth.

Face bow transfer was done and lower cast with pattern resin was mounted on semi adjustable articulator.

The resin pattern was invested, casting was done using cor alloy and framework was fabricated. This framework was

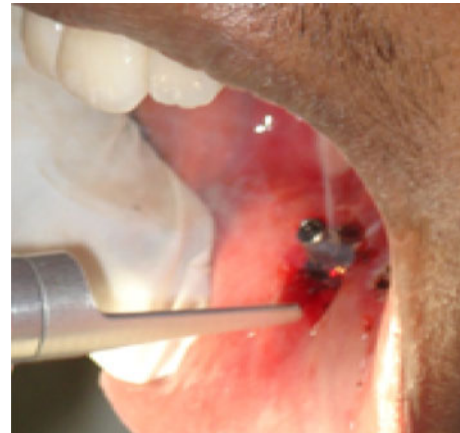

Fig. 3 Surgical excision

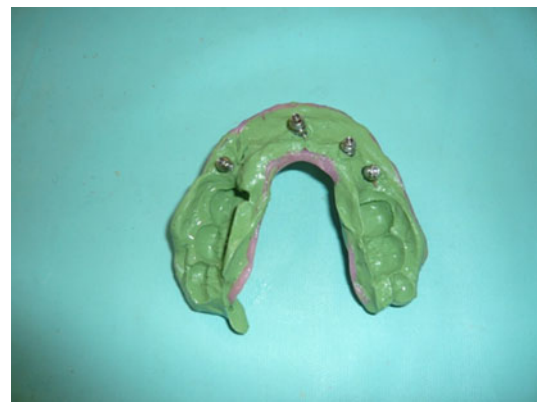

Fig. 4 Impression with transfer coping

subsequently tried in patients mouth and checked for the fit of the framework on the implant for the occlusal clearance. Metal ceramic restorations were fabricated, tried in patient's mouth & cemented using interim luting cement. Gingival portion was added to the framework where ever it was required to enhance esthetics (Figs. 7, 8, 9).

Discussion

Ameloblastoma in the mandible can progress to great size and cause facial asymmetry, displacement of teeth, loose teeth, malocclusion, and pathologic fractures. Radiographically, ameloblastoma appear as radiolucent lesion that may have either a unilocular or multilocular appearance. It may expand the cortical plate which gives rise to a paper-thin and soap bubble appearance on panoramic X-ray as well as CT scan [1]. Bilkay et al. [6] in retrospective analysis of 100 patients with benign mandibular lesion has found that 78% of the cases had a radiolucent lesion and 83% of this had cysts with welldefined borders. Yilmaz et al. [7] did a comparison between vascularised iliac crest flap (24 cases) and

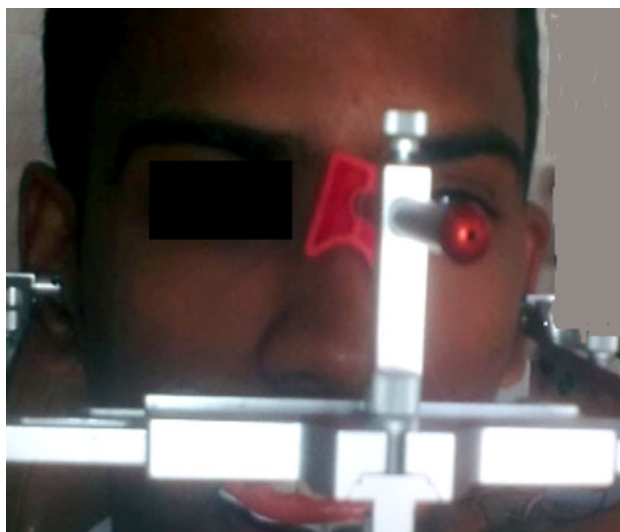


Fig. 5 Face bow record

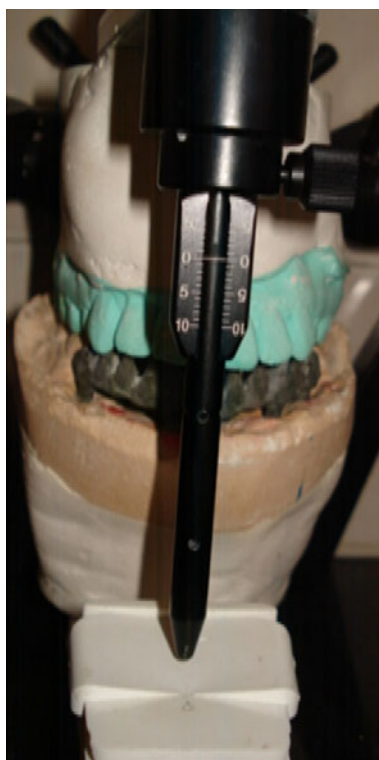

Fig. 6 Mounted casts on articulator

vascularised free fibular flap (13 cases) and noticed that less complication rate and superior functional and aesthetic results were achieved for those with fibular flap. Chana et al. [5] in their series of 10 cases utilized vascularised fibula flap with simultaneous placement of osseointegrated dental implants and claimed it is the ideal treatment for large ameloblastoma. Becelli et al. [8] elucidate two phases in the reconstruction process which are first, the phase of

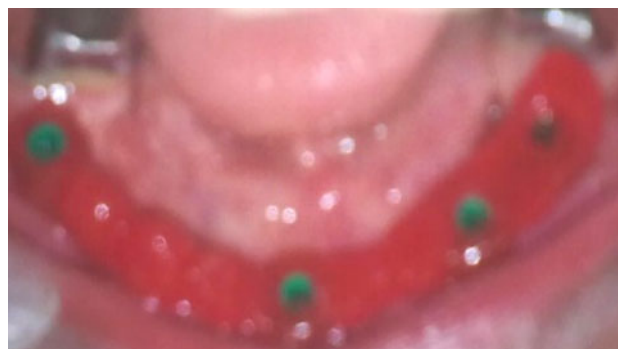

Fig. 7 Resin pattern tried in patient mouth

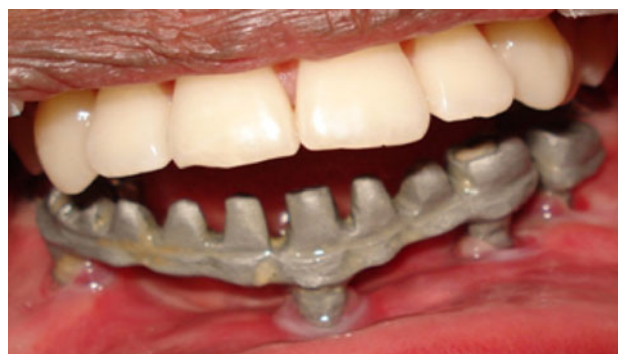

Fig. 8 Metal framework try in done

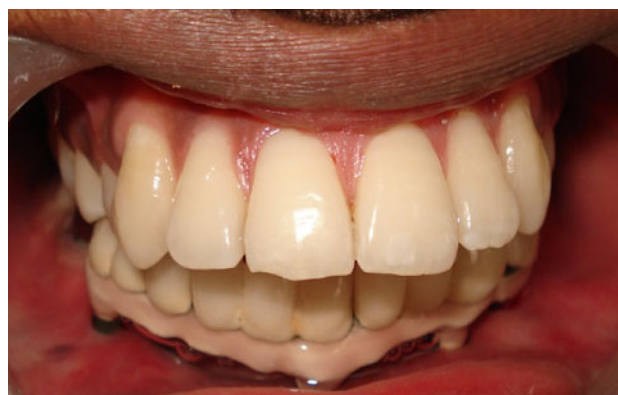

Fig. 9 Framework with gingival porcelain and crown cemented

reconstruction of the surgical defect with free or autogenous bone graft or revascularized autogenous bone graft and the subsequent phase which is carried out to obtain prosthetic restoration by means of endosseous implants.

Becker & wong reported an early functional loading case in the fully edentulous mandibular resection and reconstruction due to an ameloblastoma and placed five implants 2 years after the removal of the tumour and they concluded that the implants are stable.

For this patient with resection of ameloblastoma of anterior mandible, reconstruction with avascular fibular

graft and placement of implants in 33,34,41,45 regions of mandible was done and patient was recalled once a month for regular checkup. After 4 months of healing period, second stage surgery was done. As the prefabricated abutment was not favorable, it was decided to go ahead with UCLA abutments. Open tray impression technique was used & resin pattern was fabricated in the lab. When it was tried, we had to section the patterns, re-orient different positions of the abutment & impression was made again and cast framework was fabricated which was also tried. Finally tooth coloured & gingival porcelain was used & prostheses were fabricated & were cemented with interim luting cement.

Conclusion

A case of hemimandibulectomy was managed by using avascular fibular graft and implants. Since the tissue overgrowth around the conventional abutment was present the tissues were resected using laser. Hence to overcome this, we used customised UCLA abutments. An open tray impression technique was used and the UCLA abutments were tied using pattern resin. This was cast and gingival porcelain was added to the framework. Then crowns were fabricated on the framework and same were cemented. Thus we can conclude that customisable UCLA abutments are best choice for a case of hemimandibulectomy.

References

1. Kahairi A (2008) Management of large mandibular ameloblastoma—a case report and literature reviews. *Arch Ofac Sci* 3(2):52–55
2. Ramesh et al (2010) Unicystic ameloblastoma of the mandible—an unusual case report and review of literature. *Head Neck Oncol* 2:1
3. Gerzenshtein J, Zhang F, Caplan J, Anand V, Lineaweaver W (2006) Immediate mandibular reconstruction with microsurgical fibula flap transfer following wide resection for ameloblastoma. *J Craniofac Surg* 17(1):178–182
4. Philipsen HP, Reichart PA (2004) Classification of odontogenic tumors and allied lesions. *Odontogenic tumors and allied lesions*. Quintessence Pub. Co. Ltd, pp 21–3
5. Chana JS, Chang YM, Wei FC et al (2004) Segmental mandibulectomy and immediate free fibula osteoseptocutaneous flap reconstruction with endosteal implants: an ideal treatment method for mandibular ameloblastoma. *Plast Reconstr Surg* 113(1):80–87
6. Bilkay U, Tokat C, Helvacı E, Ozek C, Alper M (2004) Free fibula flap mandible reconstruction in benign mandibular lesions. *J Craniofac Surg* 15(6):1002–1009
7. Yilmaz M, Vayvada H, Menderes A, Demirdover C, Kizilkaya A (2008) A comparison of vascularized fibular flap and iliac crest flap for mandibular reconstruction. *J Craniofac Surg* 19(1):227–234
8. Becelli R, Carboni A, Cerulli G, Perugini M, Iannetti G (2002) Mandibular ameloblastoma: analysis of surgical treatment carried out in 60 patients between 1977 and 1998. *J Craniofac Surg* 13(3): 395–400