

Prosthetic rehabilitation of patient with immediate implant placement

Clinical Report

Sandeep Kumar, Giridhar Kamath, Seema Gupta¹

ABSTRACT

The use of immediate postextraction implants presents several advantages in terms of reduction of surgical steps and time required to conclude the therapy. Particularly important is the possibility to minimize bone loss that otherwise would occur in the physiologic healing of the alveolus. Immediate implant placement has helped solve issues with regard to bone quality, quantity and esthetics and also treatment time, as opposed to delayed implant placement. Here, a case report has been presented in which immediate extraction Frialet implant has been placed in mandibular premolar region.

KEY WORDS: Atraumatic extraction, immediate implants, Osseo integration, implant stability, bone grafts

DOI: 10.4103/0972-4052.57087

INTRODUCTION

Implant dentistry has come a long way from skepticism to being accepted as best modality to treat complete and partial edentulism. In the last two decades a great deal of activity in the field has occurred with the development of better material and newer techniques that have resulted in the clinical performance of implants. The advent of immediate extraction implants and immediate loading have, however, proved to be an interesting point in dentistry.

Following extraction, a healing period of four to six months has been considered mandatory for implant placement.^[1] However, this procedure leads to some volume of crestal bone resorption, loss of interpapillary volume and eventual compromise in esthetics- "black triangle effect". A gradual diminishing of the emerging profile is noticed^[2] due to labial bony plate being resorbed at a faster rate than the remaining bone. Controlled clinical studies have demonstrated an average of 4.4mm of horizontal and 1.2mm of vertical bone resorption six months after tooth extraction.^[3] Experimental animal researches and clinical studies demonstrated that the immediate implant placement reduces alveolar resorption.^[4-6]

Advantages of immediate implants

Placement of dental implants into fresh extraction sites offers a number of advantages:^[7]

- Immediate implant placement reduces alveolar bone resorption that occurs in delayed implant placement.
- Implants in the fresh extraction sites can be placed in the same position as the extracted tooth.
- Immediate implant placement facilitates the final restoration and minimizes the need for severely angled abutments or the fabrication of telescopic copings.
- When necessary, the surgeon can position the implant more favorably than the original tooth by redirecting the burs when preparing the implant receptor site.
- With the extraction socket as a guide, the surgeon can also more easily determine the appropriate parallelism and alignment relative to the adjacent and opposing residual dentition.
- Elimination of wait for primary healing of soft tissues and regeneration of osseous structures significantly shortens the overall treatment time.

Guidelines for extraction when planning for immediate implant placement^[7]

- 1. Preoperative Evaluation:** Patient should be

Departments of Prosthodontics and Maxillofacial Prosthetics, ¹Orthodontics, Manipal College of Dental Sciences, Manipal, India.

Address for correspondence: Dr. Sandeep Kumar, Department of Prosthodontics and Maxillofacial Prosthetics, Manipal College of Dental Sciences, Manipal - 576 104, Karnataka, India. E-mail: mdssandy07@gmail.com

thoroughly evaluated before all elective procedures. If presurgical evaluation reveals any sign of potential acute infection, antibiotic therapy should be initiated three to five days before surgery.

2. **Preservation of Bony Receptor Site:** After reflection of the mucoperiosteal tissues, care should be taken to remove the tooth with as little trauma as possible.
3. **Procedural Delays:** If any purulent exudate is discovered after removing the tooth, placement of the implant should be delayed. The tissues should be allowed to heal for several weeks before implant placement.
4. **Avoidance of Excessive Pressure:** During socket preparation, care must be taken not to create any force or pressure on the thin cortical bone.
5. **Osteotomy Preparation:** Directing the osteotome along the same long axis as the tooth socket is recommended.
6. **Improvements for Placement (stability):** Ideally the implant should be seated in at least two-thirds in the host bone. When adjacent vital structures allow it, the apex should be at least one to two mm longer than the tooth being replaced to improve the initial placement stability and crown-root ratio for the final restoration. In addition, the implant diameter at the cervical area should be as wide as possible to prevent soft tissue ingrowth.
7. **Bone Graft:** Whenever a greater than one mm circumferential defect exists, the surgeon should consider grafting the area.
8. **Soft Tissue Closure:** Primary closure of the soft tissues is usually recommended. When closure is not possible, the use of vertical relaxing incisions or horizontal ribboning of the periosteum or both should be considered to increase flap manipulation.
9. **Successful Osseo Integration:** The chances for successful osseo integration can be increased by a stress-free nonfunctional healing period.
10. **Implant Loading:** The surgeon may wish to consider loading the newly placed implant immediately when any one of the following conditions exists at the extraction site;
 - Bone is type I and II
 - Site can accommodate an implant with a length of at least 13mm

All these factors contribute to the initial and continued stability of the implant.

CASE REPORT

A 30-year-old male patient referred to the Department of Prosthodontics and Maxillofacial Prosthetics, Manipal College of Dental Sciences, from the Department of Oral Medicine and Radiology for replacement of missing teeth. On examination, root stump was found in relation

to mandibular right second premolar with no other teeth missing [Figure 1].

Treatment options

Patient was told about different treatment options. He refused removable partial denture treatment as he did not want the denture which is removable in nature. He also refused conventional fixed partial denture treatment as he did not want his other teeth to be prepared adjacent to the edentulous space.

Finally on examining the OPG [Figure 2] and IOPA of the patient, immediate implant treatment option was decided as the root stump was very small and could be extracted atraumatically.

Treatment

The distance between superior border of inferior alveolar canal and crest of residual alveolar ridge was measured on the preoperative OPG and IOPA of the patient. Width of the residual ridge was also measured with bone gauge. It was decided to place 13mm long and 4.5mm wide Frialet implant.

Patient was prepared for implant placement. Right inferior alveolar, lingual and long buccal nerve blocks were given. Mandibular right second premolar root stump was extracted atraumatically by carefully reflecting the buccal and lingual flaps. After extraction, osteotomy site was prepared and implant was screwed into the preparation site to the full depth. Then cover screw was placed on the implant [Figure 3]. Implant site was closed with sutures. Postoperative OPG and IOPA [Figure 4] were taken to see the implant placement. It was found to be satisfactory. Sutures were removed after one week. Healing period of three to four months was given before second stage to allow for proper osseo integration. After approximately four months second stage surgery was performed and gingival former was placed [figure 5]. Medium size abutment was selected and crown was fabricated in a usual way [Figure 6]. Patient was highly satisfied with the treatment results.

DISCUSSION

Immediate implant placed in fresh extraction sockets are a proven and predictable treatment modality which has helped solve issues with regard to bone quality, quantity and esthetics and also treatment time, as opposed to delayed implant placement. Immediate extraction implant, however, requires careful case selection and extraction of the tooth. Achieving good primary stability is the key factor in the success of immediate implants. Studies with patient satisfaction clearly indicate that a substantial number of patients

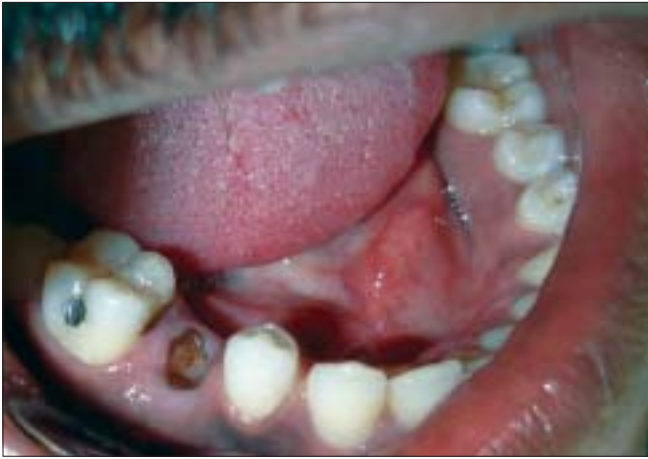

Figure 1: Preoperative intraoral view

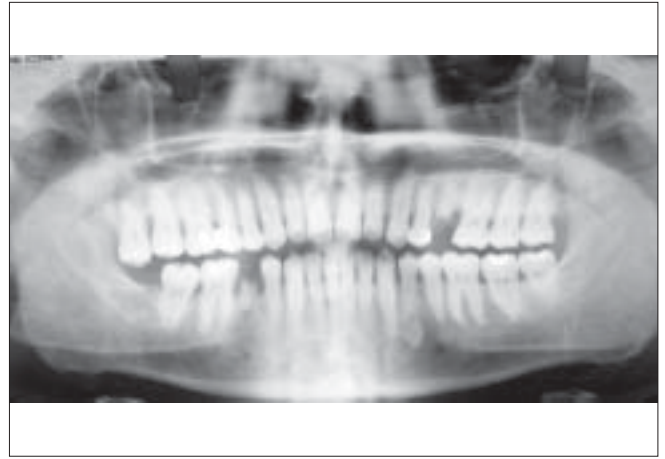

Figure 2: Preoperative OPG

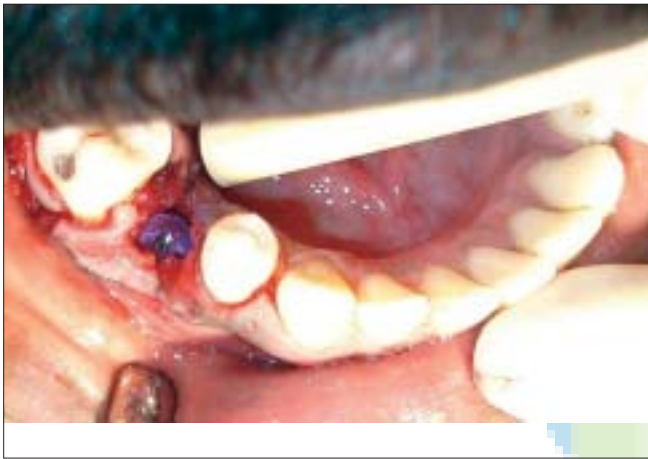

Figure 3: Implant with cover screw in place

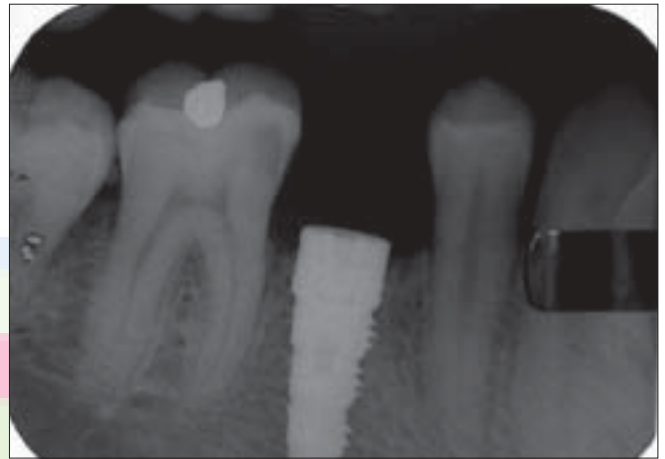

Figure 4: Postoperative IOPA

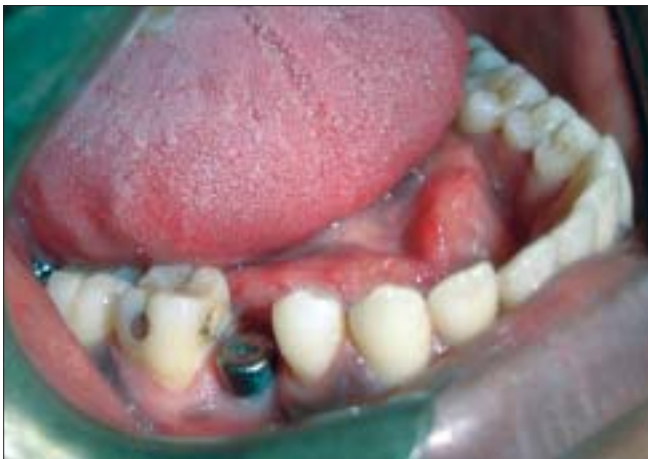

Figure 5: Gingival former in place

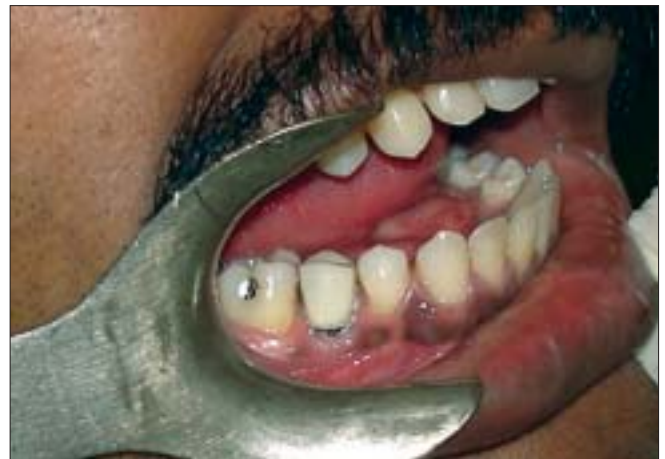

Figure 6: Metal ceramic implant crown cemented


were highly satisfied with immediate implant-supported prostheses over fixed bridges and soft tissue supported prostheses. As research avenues span across newer surgical techniques and material

our constant endeavor as clinicians is to provide our patients with predictable, functionally and esthetically sound treatment.

REFERENCES

1. Lazzara RJ, Porter SS, Testori T, Galante J, Zetterqvist L. A prospective multicenter study evaluating loading of osseointegrated implants two months after placement: One year result. *J Esthet Dent* 1998;10:280-9.
2. Bianchi AE, Sanfilippo F. Single-tooth replacement by immediate implant and connective tissue graft: A 1-9 year clinical evaluation. *Clin Oral Implants Res* 2004;15:269-77.
3. Strub JR, Kohal RJ, Klaus G, Ferrareso F. The re implant system for immediate implant placement. *J Esthet Dent* 1997;9:187-96.
4. Wheeler SL, Vogel RE, Casellini R. Tissue preservation and maintenance of optimum esthetics: A clinical report. *Int J Oral Maxillofac Implants* 2000;2:265-71.
5. Parr GR, Steffik DE, Sisk AL. Histomorphometric and histologic observations of bone healing around immediate implants in dogs. *Int J Oral Maxillofac Implants* 1993;5:534-40.
6. Barzilay I, Graser GN, Iranpour B, Proskin HM. Immediate implantation of pure titanium implants into extraction sockets of *Macaca fascicularis*. Part 1 clinical and radiographic assessment. *Int J Oral Maxillofac Implants* 1996;3:299-310.
7. Charles A Babbush. *Dental implants: The art and science*. W B Saunders Company; 2001. p. 305-16.

Source of Support: Nil, Conflict of Interest: None declared.



Dispatch and return notification by E-mail

The journal now sends email notification to its members on dispatch of a print issue. The notification is sent to those members who have provided their email address to the association/journal office. The email alerts you about an outdated address and return of issue due to incomplete/incorrect address.

If you wish to receive such email notification, please send your email along with the membership number and full mailing address to the editorial office by email.