

# Management of an edentulous patient having xerostomia with artificial saliva reservoir denture

## Clinical Report

Murtuza A. Burhanpurwala, Swaroop Kumar Magar, Aruna J. Bhandari, S. A. Gangadhar

### ABSTRACT

Xerostomia is a clinical condition caused by a decrease in the production of saliva. It may present itself as a local symptom, as part of a systemic disease, as side effects of medications or following therapeutic radiation to the head and neck regions. Xerostomia can lead to difficulties during management in patients receiving prosthodontic treatment. The comfort and retention of removable dentures depends largely on the physical properties and the lubricating ability of the saliva and dry mucosa. To help overcome this problem, various techniques have been proposed for incorporating reservoirs that contain salivary substitutes into dentures. These techniques have had varying degrees of success. This paper presents the management of a patient suffering from xerostomia who was successfully treated by providing reservoir denture made by dual flasking method. This technique resulted in a reservoir denture that provided good lubrication for the tissues, was hygienic, and was made from routine denture base material.

**KEY WORDS:** Reservoir denture, xerostomia

DOI: 10.4103/0972-4052.55252

### INTRODUCTION

Xerostomia, a clinical condition caused by a decrease in the production of saliva may present itself as a local symptom, as part of a systemic disease such as Sjogren's syndrome, diabetes, alcoholism or as side effects of medications or during following therapeutic radiation to the head and neck regions. Edentulous patients suffering from xerostomia may complain of not only dry mouth, but also of difficulty in normal functions like eating, speaking, swallowing, etc. Extreme discomfort in wearing dentures is a common complaint.<sup>[1]</sup>

Depending upon the cause, several treatment options are available to the clinician. If xerostomia is drug induced, the drug needs to be substituted. In most cases, symptomatic treatment is required and this includes the change in dietary pattern, frequent sipping of water, use of artificial salivary substitutes,

etc. However, the main problem is how to deliver this substitute constantly into the patient's mouth without his normal routine being affected. Here comes the role of an artificial saliva reservoir denture that delivers the artificial salivary substitute continuously into the patient's mouth.

This paper presents a case of an edentulous patient suffering from xerostomia who was successfully treated with a new form of reservoir denture made by dual flasking method. This technique resulted in a reservoir denture that provided good lubrication to oral tissues, was hygienic, and was made from routine denture base material.

### CASE REPORT

A 75-year-old male patient reported to the Department of Prosthodontics, Rural Dental College, Loni with the chief complaint of difficulty in mastication, dry feeling

Department of Prosthodontics, Rural Dental College, Loni, India

**Address for correspondence:** Dr. Murtuza A. Burhanpurwala, Department of Prosthodontics, Rural Dental College, Pravara Institute of Medical Sciences, Rahata, Ahmednagar, Loni – 413 736, India. E-mail: [murtuza\\_burhan@hotmail.com](mailto:murtuza_burhan@hotmail.com)

of the mouth, and frequent need for sipping water.

The patient had a history of smoking about 10 bidis per day since 20 years. Medical history was noncontributory and the patient was not on any medication.

Extraoral examination revealed reduced vertical dimension of the face, hollow cheeks, unsupported lips, and mild distortion of speech articulation on sibilant sounds. General physical examination was normal. Intraoral examination revealed maxillary and mandibular edentulous residual ridges, dry cracked tongue, and minimal frothy saliva in the floor of the mouth. Hence, a provisional diagnosis of xerostomia was made.

#### Treatment plan

Treatment plan included either conventional complete denture along with salivary substitute to be applied in the oral cavity or making lower complete denture with artificial saliva reservoir in it.

It was decided that the patient should be given maxillary denture and modified mandibular complete denture to accommodate an artificial saliva reservoir in it. This was decided so because the conventional complete denture along with saliva substitute does not provide a continuous flow of saliva affecting retention. Artificial saliva substitute (Wet Mouth, ICPA) was used. Also the patient was given multivitamin supplements. He was instructed to avoid dry foodstuffs like biscuits, smoking of cigarettes as tobacco increases oral dryness, and use a salivary substitute till the final dentures were ready.

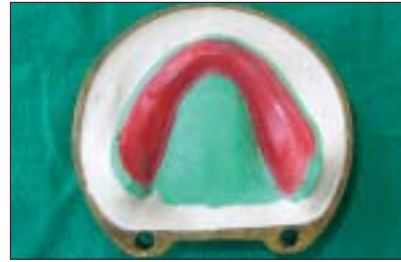#### Procedure

1. Primary impressions were made in impression compound while final impressions was made in light body elastomeric impression material since zinc oxide eugenol paste may cause burning sensation to the patient. Jaw relation was recorded keeping in mind that vertical dimension of occlusion be kept 2 mm less than normal. This was done to compensate for the slight increase in vertical dimension of occlusion that takes place when the two parts of the reservoir denture are attached to each other. Teeth arrangement was done and the trial bases were tried in the patient's mouth.
2. Now extra bulk of wax was added to the mandibular trial denture to make the denture approximately 6 mm thick. The trial denture was finished [Figure 1] and retried in the patient's mouth to check for retention, stability, esthetics, and comfort. The upper denture was fabricated in the conventional manner.

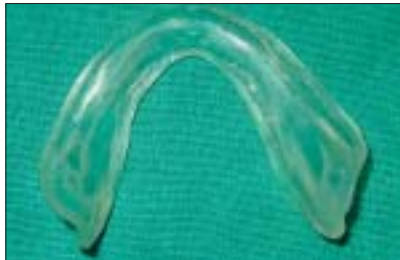3. Flasking followed by dewaxing of the lower trial denture was done to obtain a base portion containing the cast and a counter portion containing the teeth. Two mm of wax was adapted onto the mandibular cast and a bevel was carved at the entire periphery [Figure 2]. A separate flask was selected whose counter fits into the base of the first flask. Counter was again poured, the flasks were dewaxed, packed in clear heat cure acrylic resin, and processed to obtain the tissue bearing plate of the two piece reservoir denture [Figure 3].
4. The two pieces of the denture would be attached to each other using conventional stainless steel press on buttons. The male portion of this button was attached to the tissue bearing plate in the molar region. Modeling wax was adapted onto the tissue bearing plate in areas where the reservoir would be located [Figure 4].
5. A putty index was made of the entire base flask with the cast, buttons, and modeling wax. Once the putty had set, the base flask was gently deflasked. The empty base flask was kept on the putty index and dental plaster was poured to obtain the entire set up again in plaster [Figure 5].
6. Pink colored heart cure acrylic resin was then packed between this new base flask and the teeth bearing counter portion of the first flask to obtain the teeth bearing plate of the reservoir denture. This duplication was done in putty to maintain the original relationship of the teeth to the mandibular cast and to get a uniform reservoir between the two plates simultaneously.
7. The tooth bearing plate was finished and polished and it now rests on the bevel created on the tissue bearing plate. Now the female portions of the buttons were placed on their male counterparts, little amount of pink colored self cure acrylic was sprinkled on it, and the tooth bearing plate was placed to pick the female portion of the buttons in the tooth bearing plate [Figure 6].
8. Artificial saliva substitute was then filled in the lower denture and it was observed that there was a slight seepage of fluid between the two plates. To prevent this seepage, a thin sheet of non-water absorbing sponge was stuck with cyanoacrylate all along the beveled portion of the tissue bearing plate to give a perfect watertight seal [Figure 7].
9. Three outlet holes were made for the salivary substitute on each side in the retromylohyoid region of the tooth bearing plate and they were adjusted in



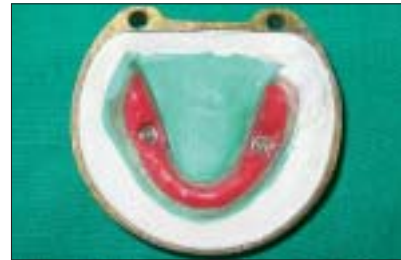**Figure 1:** Adding bulk to the lower trial denture



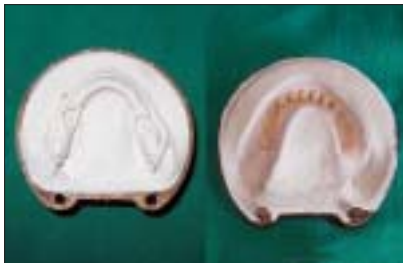**Figure 2:** Two mm wax adapted over mandibular cast with bevel created at periphery




**Figure 3:** Clear tissue bearing plate



**Figure 4:** Male portion of snap on button and modeling wax adapted to the tissue bearing plate



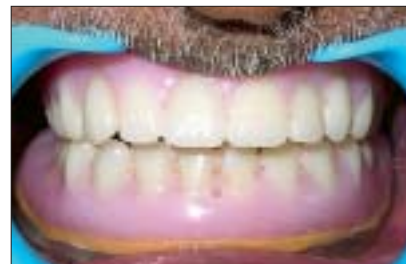**Figure 5:** New base flask closed against counter of first flask



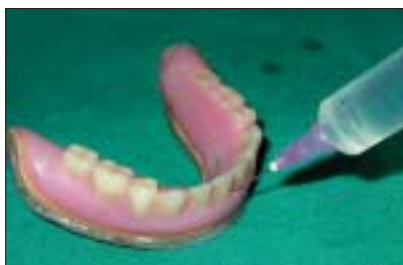**Figure 6:** Tooth bearing plate with female portion of snap on buttons



**Figure 7:** The two plates together with sponge attached to tissue bearing plate



**Figure 8:** Post-treatment intraoral view



**Figure 9:** Filling of salivary substitute with needle and syringe

size similar to the thickness of a 26-gauge needle. Also an inlet hole of diameter similar to a 19 gauge needle was made in the teeth bearing plate labially just between the two central incisors [Figure 8].

10. The patient was instructed as for routine denture and oral hygiene maintenance. He was taught how to open and close the reservoir denture for cleaning and fill the artificial salivary substitute in the denture through the inlet hole [Figure 9].

## DISCUSSION

The two-piece lower reservoir denture offers clinician an alternative method of treating patients suffering from xerostomia. Since the reservoir is placed only in the lower denture, chances of increasing the vertical dimension and the bulk is decreased as compared to reservoir in both upper and lower dentures.

The advantage of this two-piece lower denture lies in the ready access to the reservoirs and allows easy cleaning and adjustments of the reservoirs as needed. The snap on buttons orient the two plates in a perfect manner and the sponge provides for a watertight seal. The clear acrylic tissue bearing plate allows the patient

to visualize the levels of the salivary substitute in the reservoir. From a clinician's perspective, the clinical stages of denture construction are routine. However, laboratory stages are time consuming and precision is essential to ensure accurate and smooth fitting segments. Another advantage of this technique is that it utilizes routine denture materials.<sup>[1]</sup>

## CONCLUSION


This paper provides a novel approach in the management of a xerostomia patient by fabricating an artificial saliva reservoir denture made from routine denture base material. The technique of fabrication is simple, denture is easy to clean, and it provides good lubrication to the oral tissues.

## REFERENCES

1. Mendoza AR, Tomlinson MJ. The Split denture: A new technique for artificial saliva reservoirs in complete denture. *Aust Dent J* 2003;48:190-4.
2. Sinclair GF, Frost PM, and Walter JD. New design for an artificial

saliva reservoir for the mandibular complete denture. *J Prosthet Dent* 1996;75:276-80.

Source of Support: Nil, Conflict of Interest: None declared.



### Staying in touch with the journal

- 1) **Table of Contents (TOC) email alert**  
Receive an email alert containing the TOC when a new complete issue of the journal is made available online. To register for TOC alerts go to [www.jprosthodont.com/signup.asp](http://www.jprosthodont.com/signup.asp).
- 2) **RSS feeds**  
Really Simple Syndication (RSS) helps you to get alerts on new publication right on your desktop without going to the journal's website. You need a software (e.g. RSSReader, Feed Demon, FeedReader, My Yahoo!, NewsGator and NewzCrawler) to get advantage of this tool. RSS feeds can also be read through FireFox or Microsoft Outlook 2007. Once any of these small (and mostly free) software is installed, add [www.jprosthodont.com/rssfeed.asp](http://www.jprosthodont.com/rssfeed.asp) as one of the feeds.