

Full-mouth rehabilitation of completely edentulous patient using implant-supported fixed prosthesis

D. R. Prithviraj, Ankit Gupta

Department of Prosthodontics, Government Dental College, Bangalore, India

For correspondence

Dr. D. R. Prithviraj, Room No. 7, Department of Prosthodontics, Government Dental College, Bangalore, India.
E-mail: prithvidr@yahoo.com

Modern dentistry aims to return patients to normal oral health and function in a predictable fashion. The selection of the available therapy has a substantial influence on the level of quality with which this objective can be met. Satisfying a completely edentulous patient is always considered a difficult task. Various treatment options for rehabilitation of the completely edentulous patient are available: conventional complete denture, overdenture, implant-supported overdenture and full-arch fixed implant-supported prostheses. The patient's function while wearing a complete denture may be reduced to 60% compared with that previously experienced with natural dentition; however, implant prosthesis may return the function to near normal limits. This clinical report presents rehabilitation of a completely edentulous patient who was not satisfied with his existing conventional complete dentures. The patient was rehabilitated using full-arch implant-supported fixed ceramometal prostheses. The final treatment result provided the patient with esthetically and functionally efficient prostheses.

Key words: Ceramometal prosthesis, full-mouth rehabilitation, implant-supported fixed prosthesis

INTRODUCTION

The conventional prosthetic treatment for tooth loss can greatly be improved by implant dentistry.^[1] Implants are devices inserted into the body below the skin or oral mucosal membrane, which penetrate, for modifying the form and function of the jaw or face, usually by mechanical means. Dental implants are used in the oral cavity with the target of improving the stability of a dental prosthesis.^[2]

The predictability of successful osseointegrated implant rehabilitation of the edentulous jaw as described by Branemark *et al*, introduced a new era of management for the edentulous predicament.^[3] Osseointegrated implant treatment was originally developed for edentulous patient to support a fixed detachable prosthesis. Adell *et al*, reported impressive success in long-term implant using this prototype. However, alternative designs have evolved for treating patients with compromised bone or special needs.^[4]

Careful planning to combine the surgical, restorative and dental technical parameters into one overall concept is essential for successful implant therapy.^[1] Edentulous patients who require implant-supported prosthesis have diverse jaw anatomy and functional, esthetic and economic concerns. Four main prosthetic designs have been used to meet these requirements. These include the fixed ceramometal prosthesis, fixed detachable prosthesis, overdenture prosthesis and fixed removable prosthesis.^[4]

Overdentures have been shown to improve the quality of life for edentulous patient and to contribute significantly to the well-being of patient psychology. Patients have reported increased satisfaction with implant-retained overdenture rather than conventional complete dentures.^[5]

The implant-supported fixed prosthesis is a treatment option for edentulous patient in the following situations: sufficient bone in the second premolar position to house a 10-mm implant.^[4] If a patient exhibits adequate facial muscle tonus, which does not require support from the facial flange of a denture and if the lips do not descend below the cervical line of anterior teeth.^[6]

A fixed restoration provides the psychological advantage of acting and feeling similar to natural teeth, whereas overdentures, even fully implant supported, remain a removable prosthesis. Implant overdenture requires greater maintenance and exhibit more frequent prosthetic-related complications than fixed restorations.^[7] A fixed ceramometal prosthesis is similar in design to a conventional fixed prosthesis used to replace partially edentulous ridges. The ceramometal prosthesis can be cemented to transmucosal abutments or secured with gold alloy screws. Optimal esthetic, phonetic and hygiene are possible with this design.^[4]

This clinical report describes full-mouth rehabilitation of an edentulous patient using full-arch implant-supported fixed prosthesis.

CASE REPORT

A 68-year-old man was referred to the department of prosthodontics, Government Dental College, Bangalore, with a complaint of difficulty in managing his existing conventional complete dentures. The medical history was non-contributory.

The dental history revealed that he was edentulous since past 3 years, and was rehabilitated with a conventional complete denture for his missing dentition. The patient was not satisfied with removable prostheses due to poor masticatory efficiency, and he was interested in fixed prosthesis for replacing his missing dentition.

The intraoral examination revealed edentulous ridges of medium size, parallel walls with no undercuts and mucosal covering of healthy and uninflamed nature [Figure 1A]. The panoramic radiograph and computed tomography (CT) scan were performed for evaluating the bone quality and quantity [Figure 1B].

The definitive treatment plan included fabrication of implant-supported fixed ceramometal prosthesis to rehabilitate both maxillary and mandibular edentulous ridges. The treatment plan included placement of six endosseous implants in each edentulous ridge in the region of canine, second premolar and second molar. Technically, it is preferable to place one implant for each missing tooth; however, the economic condition of the patient restrained the number of implants to six in each arch.

The implant surgery was designed in two phases; phase 1, mandibular rehabilitation and phase 2, maxillary rehabilitation.

A clear acrylic resin surgical stent was prepared on the diagnostic cast with the small steel balls of known diameter placed over the proposed implant site. A second OPG was performed with stent in the patient's mouth to assess the height of the available bone accurately. Later in the same stent, the steel balls were removed and the resultant holes were used as a surgical guide during implant placement.

The mandibular rehabilitation was initiated with the first implant surgery, which included specific oral surgical procedures. Under local anesthesia, mucoperiosteal flap was reflected and with the help of surgical stent, six endosseous implants (four of which are Endopore system; Innova company, Canada, USA; 2 are of Screw type; Zimmer Dental, Canada, USA) were placed. Implants measuring: 12 mm for the canine region, 13 mm for the second premolar region and 9 mm for the second molar region were placed at the proposed implant sites. The surgery was uneventful.

The healing screws were secured over the implant after evaluation of primary implant stability and the mucoperiosteal flap was meticulously sutured. The

patient was instructed not to use the existing denture for two weeks. After two weeks of healing, the lower denture was relined with soft liner (Ufi Gel P; Voco, Germany) and inserted. The postoperative healing was uneventful.

After 15 days of mandibular implant placement, with the help of surgical stent, six endosseous implants were placed in the maxillary arch. The patient had extremely soft and cancellous bone in the right maxillary tuberosity region, which complicated the implant placement. The endosseous implant [Endopore system] was simply tapped into the cancellous bone without any osteotomy holes in the abovementioned region.

During the placement of the implant in the left maxillary second molar region, a perforation was observed in the floor of the maxillary sinus; however, the sinus mucosal lining remained intact [Figure 2]. After evaluation of primary stability, healing screws were placed and flap was closed. After 15 days of healing, the upper denture was relined with soft liner and inserted.

After 3 months of uneventful healing and radiographic evaluation, the second-stage surgery for the mandible was designed. Two of the cover screws of the implants in the mandible were already visible and for the remaining implants, punch incisions were made to expose the healing screws. Impression copings were attached to the implant bodies [Figure 3A].

Using a close tray technique, an elastomeric impression (Vinyl polysiloxane Impression material; 3M ESPE, Germany) was made. The impression copings were removed from the implant bodies and implant analogs were attached to them. Subsequently, they were repositioned into the impression. The cast was fabricated using dental stone (Goldstone, Asian chemicals, Mumbai). The abutments were fixed on the implant analogs in the mandibular cast.

The interocclusal record was made using modeling wax (Hindustan; Hindustan Dental Products, Hyderabad, India) and zinc oxide eugenol paste (Denzomix Dental Impression paste; Mixodent, India) between upper conventional denture and lower implant abutments. The cast was mounted on a mean value articulator. The ceramometal prosthesis was fabricated in two sections: a right half and a left half. This was done to avoid any torsion/flexural forces.

The prosthesis was cemented on the abutment using zinc oxide eugenol cement (Kalzinol; Germany) [Figure 3B]. For the next two months, the patient used maxillary conventional denture against the opposing mandibular implant-supported fixed prosthesis.

Two months later, the second stage surgery for the maxillary arch was performed. Similar prosthetic procedures were carried out for the maxillary arch [Figure 4A]. The interocclusal record was made using

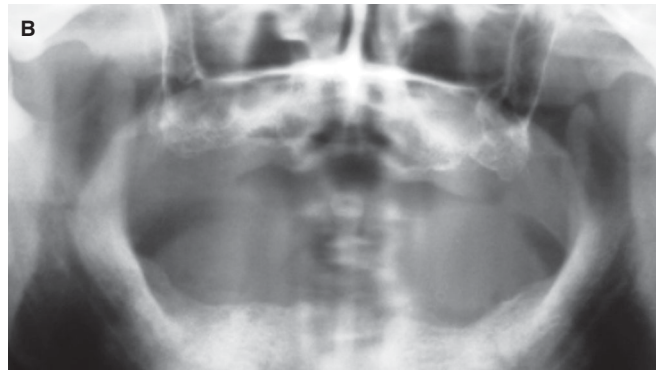
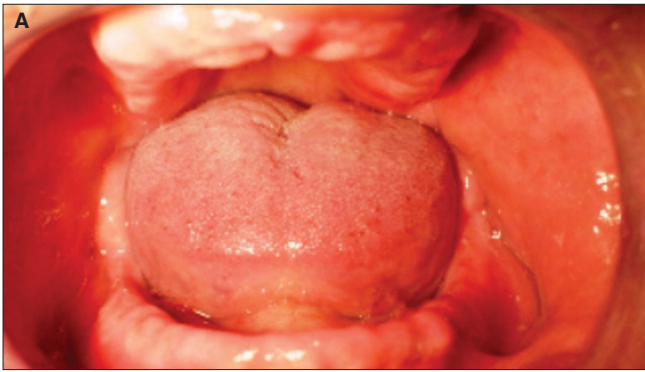


Figure 1: (A) Preoperative intraoral photograph. (B) Preoperative panoramic radiograph.

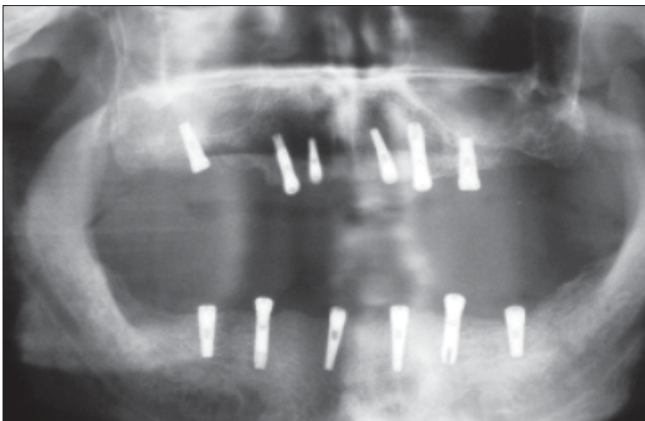


Figure 2: Postimplant placement panoramic radiograph

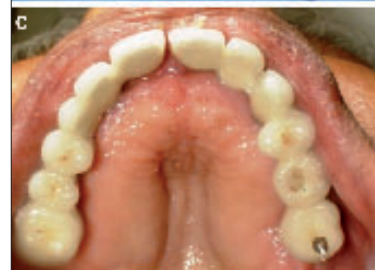
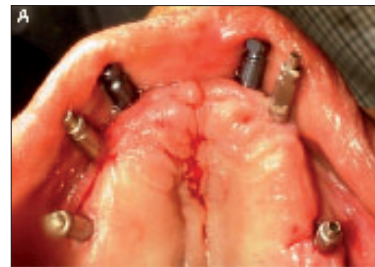
Figure 4: (A) Impression copings attached to maxillary implants. (B) Interocclusal record and mounted articulator. (C) Cemented maxillary implant-supported fixed prosthesis

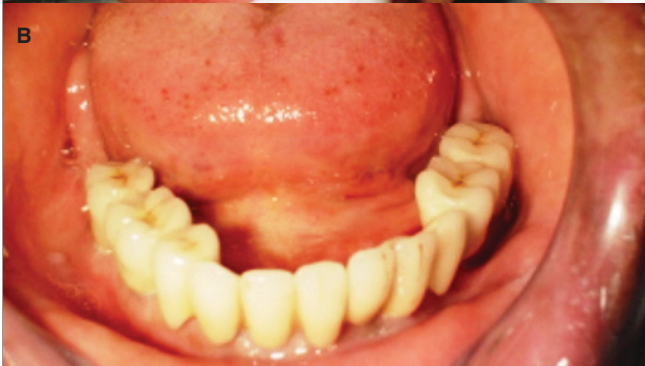
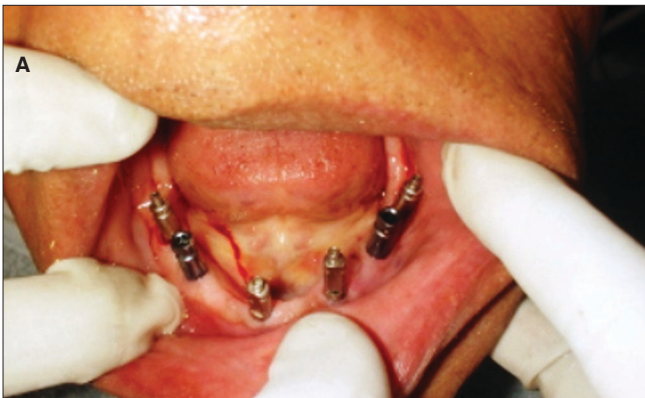
Figure 3: (A) Impression copings attached to mandibular implants. (B) Cemented mandibular implant-supported fixed prosthesis

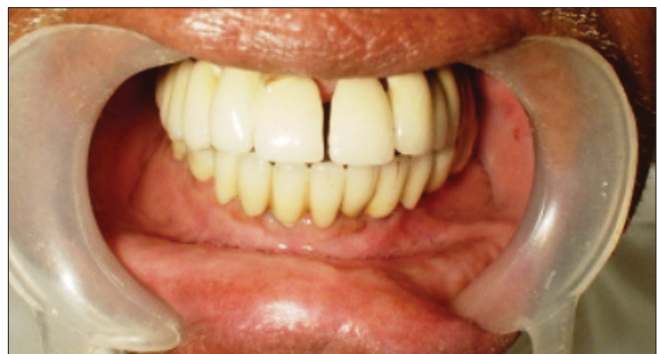

Figure 5: Posttreatment intraoral photograph.

modeling wax and zinc oxide eugenol paste between maxillary abutments and opposing mandibular fixed prosthesis [Figure 4B]. The maxillary prosthesis was also fabricated in two sections to overcome the difficulty encountered due to divergent abutments in the maxillary anterior region. The occlusal adjustments were carried out at the bisque stage and the mutually protected occlusion scheme was established. The final prosthesis was cemented onto the abutments using zinc oxide eugenol cement [Figure 4C].

The patient was explained the importance of maintenance of the implant-supported prosthesis and discharged. The patient was recalled after 1 week, 1, 3, 6 months and 1 year. Presently, the patient is comfortable and happy and periodic recall examination reveals gingiva is healthy and free from any inflammation [Figure 5].

DISCUSSION

The procedure explained in this clinical report for the rehabilitation of the edentulous patient results in accurately fitted, esthetic and functionally efficient prosthesis. The patient in this clinical report was previously restored with a conventional complete denture and revealed his dissatisfaction with his removable prostheses. Therefore, for this patient, the use of full-arch implant-supported fixed prostheses (or Bone-anchored complete denture or Toronto denture) provided a prosthetic solution.

There were various treatment options for this patient. The fixed restoration provides the psychological advantage of acting and feeling similar to natural teeth. The removable prostheses such as complete

denture or overdenture do not provide “part of their body feeling.” In fact, a common remark made by patients with fixed restoration is “their implant teeth are better than their own teeth,” whereas comments related to implant overdenture are “these are better than their dentures.”

The advantage for fixed prostheses compared to removable prostheses also includes less repair and maintenance and they often last till the life of the implant support.^[7]

REFERENCES

1. Weigl P. Implant prosthodontics: What next?. *Quintessence Int* 2003;34:653-69.
2. Hobkirk JA, *et al.* Color atlas and text of dental and maxillofacial implantology. Wolfe Company: Mosby; 1995. p. 35.
3. Henry JP. A review of guidelines for implant rehabilitation of the edentulous maxilla. *J Prosthet Dent* 2002;87: 281-8.
4. Sadowsky JS. The implant-supported prosthesis for the edentulous arch: Design considerations. *J Prosthet Dent* 1997;78:28-33.
5. Pasciuta M, Grossmann Y, Finger MI. A prosthetic solution to restoring the edentulous mandible with limited interarch space using an implant-tissue-supported overdenture: A clinical report. *J Prosthet Dent* 2005;93: 116-20.
6. Loos GL. A fixed prosthodontic technique for mandibular osseointegrated titanium implants. *J Prosthet Dent* 1986;55:232-42.
7. Misch CE. *Dental implants prosthetics*. Elsevier: Mosby; 2005. p. 252.

Source of Support: Nil, **Conflict of Interest:** None declared.