

The third point of reference and its effect on the protrusive condylar guidance angles obtained in semi-adjustable articulator

Deviprasad Nooji, Suresh M. C. Sajjan¹

Department of Prosthodontics including Crown and Bridge and Implantology, KVG Dental College and Hospital, Kurunjibag, Sullia, DK, Karnataka, ¹Vishnu Dental College, Bheemavaram, Andra Pradesh, India

For correspondence

Dr. Deviprasad Nooji, Department of Prosthodontics, KVG Dental College and Hospital, Sullia, DK, Karnataka - 574 327, India.
E-mail: devinooji@yahoo.co.in

CONTEXT: Clinicians have questioned the transferability of occlusal plane relationship from the patient to the articulator when Orbitale was used as anterior point of reference for the facebow transfer. **AIMS:** The aim of this study was to evaluate the effect of 4 different anterior reference points on the protrusive condylar guidance angles in using an articulator. **SETTINGS AND DESIGN:** Twelve dentate patients were selected for the study. Hanau Wide Vue (No. 183, Teledyne Water Pik, Fort Collins, Colorado, USA) and corresponding SpringBow (Teledyne Water Pik, Fort Collins, Colorado, USA) were used in the study. **MATERIALS AND METHODS:** Four maxillary casts were obtained for each patient and mounted on a Hanau Wide Vue articulator with the help of a SpringBow using Orbitale, Orbitale minus 7 mm, and the inferior and superior annular notches of the articulator incisal guide pin as four points of references. The mandibular casts were hand articulated in the maximum intercuspal position. Protrusive records were made using Polyether Bite Registration material (Ramitec, 3M ESPE, St. Paul, MN), and the articulator was programmed for all the 4 mountings in each patient. The protrusive condylar path angles to Frankfort plane were obtained from lateral cephalometric tracings made in maximum intercuspation and protrusive position for comparison. **STATISTICAL ANALYSIS USED:** Statistical analysis was done using paired *t* test and Wilcoxon's signed rank test ($P < 0.05$) to make a comparison between the protrusive condylar guidance angles obtained from the interocclusal records with the mountings using 4 different third points of references and those of radiographic tracings. **RESULTS:** The protrusive condylar guidance values obtained on the casts related to the third point of reference with the superior annular notch and Orbitale minus 7 mm reference points differed significantly from the radiographic values ($P < 0.05$). The mean protrusive condylar guidance angles differed from the mean radiographic values in an ascending order: inferior annular notch (-2.4 degrees), Orbitale (5.2 degrees), Orbitale minus 7 mm (13.1 degrees), and superior annular notch (17.0 degrees) respectively ($P < 0.05$). The protrusive condylar guidance registrations for the right and the left sides on the casts related to the third point of reference with Orbitale (R = 41.8 degrees and L = 36.9 degrees) and inferior annular notch (R = 49.4 degrees and L = 44.8 degrees) were found to be closer to radiographic values (R = 47.0 degrees and L = 41.0 degrees) ($P < 0.05$). **CONCLUSIONS:** Within the limitations of this study, the Orbitale and inferior annular notches were found to be more accurate anterior points of references than the superior annular notch and Orbitale minus 7 mm reference points to mount the casts in Hanau Wide Vue articulator using Hanau SpringBow.

Key words: Facebow transfer, inferior annular notch, protrusive condylar guidance, semi-adjustable articulator, superior annular notch, third point of reference

INTRODUCTION

Semi-adjustable articulators are commonly used in restorative dentistry, especially in prosthodontics for their simplicity in handling and programming. Facebow is a caliperlike instrument used to record the spatial relationship of the maxillary arch to some anatomic reference point or points and then transfer this relationship to an articulator.^[1] The use of 2 posterior points and an anterior point of reference

for orienting a maxillary cast to an articulator has long been advocated.^[2] An anterior reference point is a physical requirement for orienting casts in the three-dimensional space in an articulator.^[3] Improper

This paper won the 'Best Paper Award' at the 7th Indian Prosthodontic Society Postgraduate Students' Convention held at Chennai from 27th to 28th August 2005; and the 'F. D. Mirza Award' at the Indian Prosthodontic Society 33rd IPSCON '05 held at Aurangabad from 24th to 27th November 2005.

positioning of the casts in an articulator may result into an inadequate restoration with an undesirable appearance and cause damage to the supporting structures.^[4]

The rotational axis of the condyles is selected as posterior reference point whenever axis-orbital plane is the reference plane of an articulator.^[5] The condylar axis may be either arbitrary (Bergstrom's point and Beyron's point) or kinematic (true hinge axis).^[5] When the Frankfort horizontal plane is the reference plane of an articulator, the superior most point of external auditory meatus is used as posterior point of reference.^[5] Present-day facebows for semi-adjustable articulators, most common being meatus type, use the external auditory meatus as posterior determinants.

Since the introduction of Snow's facebow, not much change has been made in the fundamental design of a facebow.^[6] Snow determined the position of plaster casts in an articulator, not only with regard to distance of the median incisal point from the condyles, but also other points on the occlusal plane were identified in relation to the condyles.^[6] However, the problem in ascertaining the level of the occlusal plane of the casts in the articulator was not solved.^[6,7]

The recommended anterior reference point is Orbitale for mounting casts in a Hanau Wide Vue (Teledyne Water Pik, Fort Collins, Colorado, USA) semi-adjustable articulator whenever Hanau SpringBow (Teledyne Water Pik, Fort Collins, Colorado, USA) is used.^[8] Orbitale is a notch present in the lower rim of the orbit in line with the pupil of the eye.^[9] Some investigators have suggested to use Orbitale minus 7 mm and the superior and inferior annular notches of the incisal guide as an anterior point of reference.^[5] However, the effect of different anterior reference points on the condylar guidance settings of the articulator has not been studied. It is also important to know which of the above-mentioned reference points would orient the casts in an articulator nearest to the natural position and best reproduce the condylar guidance values of a patient. The lateral cephalometric radiographic measurements have been used by few authors to provide results that were representative of anatomic orientations.^[10]

An average anterior reference level on the incisal guide pin has been indicated with many articulators.^[7] In all the Hanau articulators, this is marked by means of a groove placed into the incisal guide pin.^[7] Snow used the plane extending from the bottom of the glenoid fossa and passing through the anterior nasal spine (Camper's plane or Bromell's plane) as the reference plane to fix the occlusal plane by making them parallel to each other.^[6,7] This plane could not be determined clinically; but it approximately corresponds to a line drawn from the upper part of the tragus to the lower

part of the ala of the nose.^[6,7] The facebow introduced by Wordsworth was based on a 'naso-optic-condylar' triangle, and the midpoint of an imaginary line drawn from the lower border of the ala of nose to the outer canthus of eye was used as an anterior reference point.^[11]

In many articulators the Frankfort plane is more popularly being used as the plane of orientation for the facebow records and to mount the maxillary casts in the articulator. This is achieved by using the infraorbital notch from the patient as the third point of reference, for which an alignment pointer was made. The record is then transferred to the articulator in the same relation by having the Orbitale pointer coincide with Orbitale indicator counterpart on the articulator.^[7]

The use of Orbitale as a third point of reference is said to orient the maxillary cast to the upper member of the articulator, as the maxilla is oriented to the Frankfort horizontal plane.^[11] The earlier Hanau articulators had different anterior points of references marked on the incisal guide pin at the levels 30 mm, 37 mm, and 51 mm below the condylar plane.^[12] Lauciello and Appelbaum^[12] suggested a new incisal notch situated 47 mm below the condylar plane (54 mm below the orbital plane). The presence of many markings on the incisal guide pin would put the practitioner in confusion as to which one should be used and when. The Hanau Wide Vue articulator is provided with 2 incisal notches at the levels of 37 mm and 54 mm from the orbital plane. The 37-mm incisal notch orients the maxillary cast based on Balkwell's triangle, and the 54-mm incisal notch orients the maxillary cast in an average position.^[12]

Bailey and Nowlin^[2] found that neither the Orbitale nor the incisal notch on the incisal guide pin when used as anterior reference point could accurately transfer the relationship of maxillary plane to the Frankfort horizontal plane. The authors have used Hanau model 130-28 articulator which had the condylar plane and the orbital plane at the same level and was used with Hanau 132-25m facebow.^[2] Gonzalez and Kingery^[10] found that the relationships of the planes of reference are not maintained during the transfer from the patient to the articulator and suggested using an anterior point of reference 7 mm below the Orbitale. However, the 7-mm difference between the orbital plane and the condylar plane is being compensated in the Hanau Arcon H2 and Hanau Wide Vue articulators.^[13]

Hanau SpringBow is routinely used with Hanau Wide Vue articulator. Hanau SpringBow is a earpiece type of facebow, and the external auditory meati are used as posterior determinants for recording the orientation of maxilla to the cranium and then transferring it to an articulator.^[1]

The orbit produced by the centers of right and left condyles during protrusive movement is referred to as the protrusive condylar path.^[14] The angle formed by the protrusive condylar path and the horizontal reference plane is called the sagittal inclination of the protrusive condylar path or protrusive condylar guidance angle.^[14] The lateral cephalometric radiographs have been used to measure the angulations between various reference planes.^[10]

The purpose of the present study was to evaluate the effect of 4 different anterior reference points on the protrusive condylar guidance registrations in Hanau Wide Vue semi-adjustable articulator and to compare the protrusive condylar guidance values registered on mountings with 4 different resultant reference planes to the protrusive condylar path angle relative to Frankfort's horizontal plane obtained from radiographic tracings. The null hypothesis stated that there was no difference in the protrusive condylar guidance registrations in a Hanau Wide Vue semi-adjustable articulator when 4 different anterior reference points were used with Hanau SpringBow.

MATERIALS AND METHODS

Twelve patients, all within 18 to 26 years of age, with a full complement of teeth and without any history of orthodontic treatment, extraction, or temporomandibular disorders were chosen for the study with informed consent. Four sets of stone casts were obtained for each patient after making irreversible hydrocolloid impressions. Four different anterior reference points selected for mounting the casts on a Hanau Wide Vue semi-adjustable articulator were, Orbitale of the patient, Orbitale minus 7 mm on the patient, superior annular notch on the incisal guide pin of the articulator (37 mm below the orbital plane), and inferior annular notch on the incisal guide pin of the articulator (54 mm below the orbital plane).

The right Orbitale was located over the notch present in the lower rim of the orbit in line with the pupil of the eye.^[9] A radiographic marker was placed on the located point [Figure 1], and a lateral cephalometric

radiograph was made [Figure 2]. The position of the Orbitale was confirmed and marked on the patient's face with an indelible pencil [Figure 3]. This marking was used as the anterior point of reference for the facebow transfer using a facebow (Hanau SpringBow, Teledyne Water Pik, Fort Collins, Colorado, USA). The external auditory meati were used as posterior determinants for recording the orientation of maxilla to the cranium. A second mark was made 7 mm below the Orbitale marking [Figure 4] and used for the second facebow transfer. The recorded orientation relations were used to mount the first two sets of casts on an articulator. A new facebow record was made without considering the anterior reference point on the patient. The third and the fourth set of casts were mounted using the new facebow record. The facebow was adjusted by using an anterior elevator (no. 010358-000, Teledyne Water Pik, Fort Collins, Colorado, USA) to locate the incisal edges of the maxillary casts at the level of superior and inferior annular notches of the incisal guide pin respectively [Figure 5]. The mandibular casts were then mounted in maximum intercuspation with the maxillary cast by hand articulation. The same procedure was followed to mount the casts of all 12 patients in 4 different resultant reference planes.

Three sets of protrusive interocclusal records were made using Polyether Bite Registration Material (Ramitec, 3M ESPE, St. Paul, MN). The articulator was programmed using each of the interocclusal records, and mean protrusive condylar guidance angle for each mounting was calculated and tabulated.

Lateral cephalometric radiographs were made in maximum intercuspation and protrusive positions for both right and left sides using a Broadbent cephalostat to standardize the head positions [Figure 6]. The cephalograms were traced and overlapped for each side [Figure 7]. The protrusive condylar path was obtained by joining the centers of the condyles in maximum intercuspation and in the protrusive position. Frankfort horizontal plane was drawn from the deepest point of inferior orbital rim to the highest point of the external auditory meatus. The angle between the

Table 1: Results of paired *t* test for protrusive condylar guidance values of right side obtained on mountings using 4 different anterior reference points and those obtained from radiographic tracings (*P* < 0.05)

Right side	Difference from radiographic values						
	Mean±SD	Mean	SE	95% CL	Range	SD	CV (%)
Radiograph	47.0±5.0	-	-	-	-	-	-
Orbitale	41.8±7.4	5.2	1.9	1.5 to 8.9	-9 to 15	±6.4	125
Orbitale – 7 mm	33.3±9.8	13.1	2.7	7.8 to 18.4	-4 to 25	±9.2	70
Superior annular notch	30.0±7.1	17.0	2.6	11.8 to 22.2	1 to 29	±9.0	53
Inferior annular notch	49.4±8.1	-2.4*	2.2	-6.9 to 2.0	-14 to 10	±7.7	320

*Not significant (*P* = 0.31), Paired *t* test, Wilcoxon's signed rank test, SE = Standard error, CL = Confidence level, SD = Standard deviation, CV = Coefficient of variance

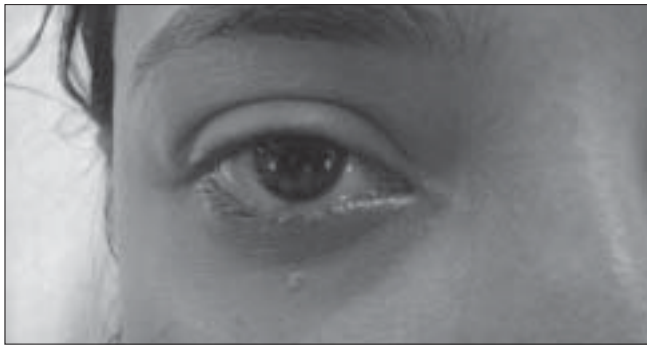

Figure 1: Radiopaque marker placed over right Orbitale region




Figure 5: Casts were mounted using A, Orbitale; B, Orbitale minus 7 mm; C, superior annular notch; and D, inferior annular notch as anterior reference points

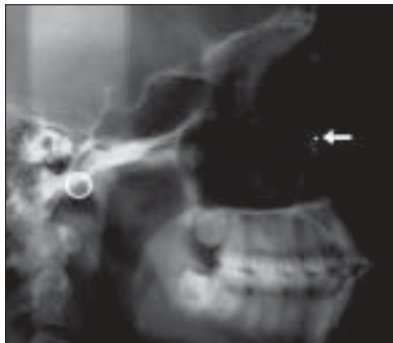

Figure 2: Position of Orbitale was confirmed with lateral cephalogram

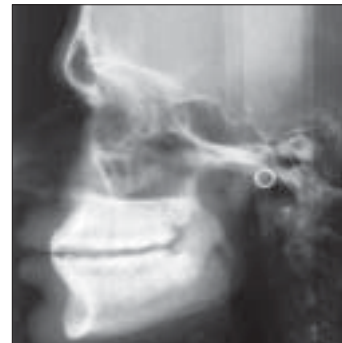

Figure 6: Lateral cephalometric radiographs in A, maximum intercuspitation; and B, protrusive position

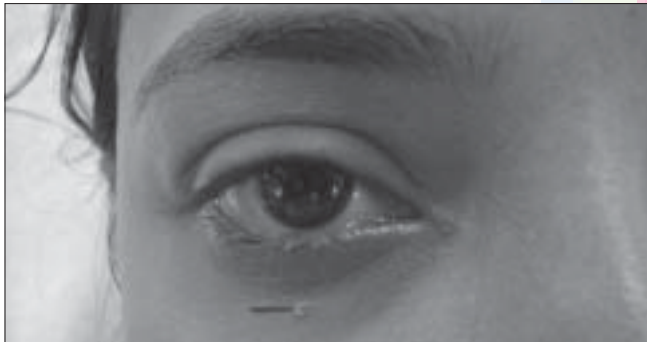


Figure 3: Orbitale marking made with indelible pencil

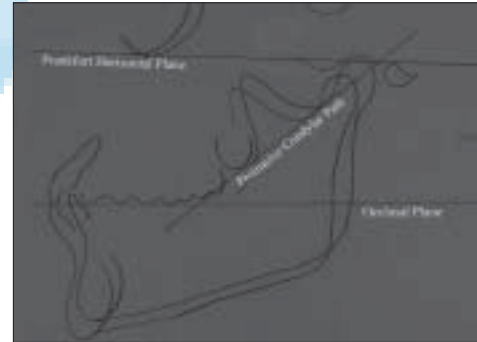


Figure 7: Tracings of lateral cephalograms in maximum intercuspitation and protrusive position were overlapped

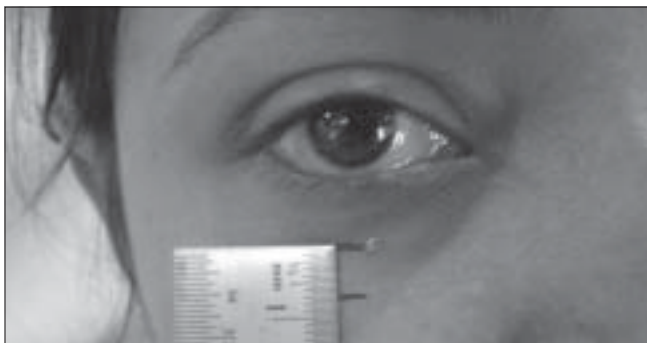


Figure 4: Second marking made 7 mm below Orbitale marking

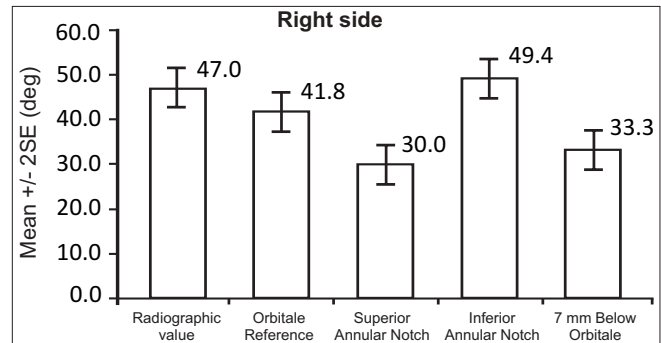


Figure 8: Comparison of mean protrusive condylar guidance registrations (with standard error) obtained for mountings using Orbitale, Orbitale minus 7 mm, superior annular notch, and inferior annular notch as anterior reference points with those obtained from radiographic tracings for the (A) right and (B) left sides

condylar path and the Frankfort horizontal plane was measured and tabulated.

Reliability of method

A second set of radiographic tracings and measurements for all the patients was made by a different operator for testing the reliability. The differences between measurements on the first and second tracings were calculated. The percentage error was found to be 4.9%.

The values obtained for protrusive condylar guidance in 4 different mountings and the radiographic tracings were analyzed using paired *t* test and Wilcoxon's signed rank test with 95% level of significance (*P* < 0.05) [Tables 1 and 2].

RESULTS

The protrusive condylar guidance values obtained

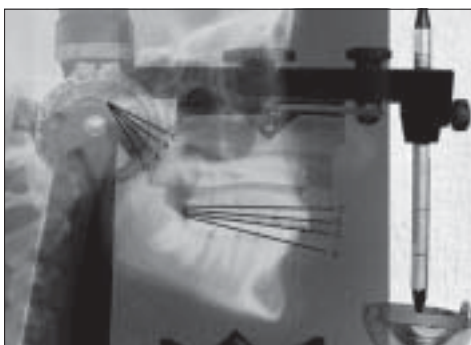


Figure 9: Lateral cephalometric radiograph was overlapped over photograph of mounting using Orbitale as anterior reference point. Protrusive condylar guidance registrations were found to change with inclination of occlusal plane when mounted using (A) Orbitale, (B) Orbitale minus 7 mm, (C) superior annular notch, and (D) inferior annular notch as anterior reference points

for the right and left side were different and hence considered separately for analysis. The mean protrusive condylar guidance values registered on right side for mountings with Orbitale, Orbitale minus 7 mm, superior annular notch, and inferior annular notch references were 41.8 ± 7.4 degrees, 33.3 ± 9.8 degrees, 30.0 ± 7.1 degrees, and 49.4 ± 8.1 degrees respectively. The mean protrusive condylar guidance values registered on left side for mountings with Orbitale, Orbitale minus 7 mm, superior annular notch, and inferior annular notch references were 36.9 ± 7.5 degrees, 30.1 ± 6.7 degrees, 26.2 ± 5.8 degrees, and 44.8 ± 7.9 degrees respectively. The protrusive condylar guidance values registered on the right side for mountings with Orbitale, Orbitale minus 7 mm, and superior annular notch reference were significantly different from the radiographic values (*P* < 0.05), and the difference was not significant for inferior annular notch reference (*P* = 0.31); whereas on the left side the protrusive condylar guidance values registered for mountings with Orbitale minus 7 mm and superior annular notch reference were significantly different (*P* < 0.05), and those for Orbitale (*P* = 0.07) and inferior annular notch reference (*P* = 0.12) were not significantly different from those of radiographic tracings.

DISCUSSION

However, the standard deviation (± 6.4 and ± 6.5) and the range of differences (-9 to 15 and -5 to 15) were less when the Orbitale reference was used for mounting the casts. The mean protrusive condylar guidance value obtained for mountings using the inferior annular notch reference was closer to the radiographic value, followed by that of the Orbitale reference. But the range of variation was more for

Table 2: Results of paired *t* test for protrusive condylar guidance values of left side obtained on mountings using 4 different anterior reference points and those obtained from radiographic tracings (*P* < 0.05)

Technique	Mean±SD	Difference from radiographic values					
		Mean	SE	95% CL	Range	SD	CV (%)
Radiograph	41.0±8.1	-	-	-	-	-	-
Orbitale	36.9±7.5	4.1*	1.9	0.4 to 7.8	-5 to 15	±6.5	158
Orbitale – 7mm	30.1±6.7	10.7	2.3	6.1 to 15.3	-1 to 21	±7.9	74
Superior annular notch	26.2±5.8	14.8	2.6	9.6 to 20.1	-5 to 28	±9.1	62
Inferior annular notch	44.8±7.9	-3.8**	2.0	-7.7 to 0.2	-14 to 10	±6.9	183

*Not significant (*P* = 0.07); **Not significant (*P* = 0.12); Paired *t* test; Wilcoxon's signed rank test; SE = Standard error; CL = Confidence level; SD = Standard deviation; CV = Coefficient of variance

Table 3: Third points of references used to mount the casts that registered the protrusive condylar guidance angles closer to the radiographic values as observed for each patient

Subject	1	2	3	4	5	6	7	8	9	10	11	12
Right	IAN	ORB	ORB	IAN	IAN	IAN	IAN	IAN	SAN	ORB	ORB	ORB
Left	IAN	ORB	ORB	ORB	IAN	IAN	IAN	IAN	ORB	ORB	IAN	ORB

IAN = Inferior annular notch; SAN = Superior annular notch; ORB = Orbitale

inferior annular notch than for the Orbitale when used as the anterior point of reference.

The analysis of data obtained from the study did not support the null hypothesis. Various anterior reference points resulted in different protrusive condylar guidance values.

The protrusive condylar guidance values for right and left side with inferior annular notch (49.4 degrees and 44.8 degrees) and Orbitale (41.8 degrees and 36.9 degrees) when used as anterior reference points were closer to the radiographic values (47.0 degrees and 41.0 degrees) [Figure 8]. However, the angles were greater (2 degrees to 4 degrees) for inferior annular notch reference and lesser (4 degrees to 5 degrees) for Orbitale reference than those of the radiographic values. Weinberg^[15] observed that a 9-degree decrease in the condylar path inclination resulted in a 0.2-mm reduction in the nonworking cusp height. Hence a variation of 2 to 5 degrees would be clinically not significant. Significant differences ($P < 0.05$) were found between the condylar guidance angles registered for mountings with the superior annular notch and Orbitale minus 7 mm reference points when compared to the radiographic values. The casts were found to be closer to the anatomic position on the mountings with the Orbitale reference.

Gonzales and Kingery^[10] observed the lack of parallelism between the Frankfort horizontal plane and the axis-orbital plane. The 7-mm correction was suggested by the authors. However, the orbital pointer is placed 7 mm above the level of the condylar plane in the newer Hanau articulators.^[13] The mountings with the inferior annular notch registered the protrusive condylar guidance values closer to the radiographic values than did those with the superior annular notch, supporting the findings of Lauciello and Appelbaum.^[12]

The protrusive condylar path angles changed proportionately with the plane of orientation on mountings using different anterior points of references. The casts were found to be closer to the radiographic position in relation to the Frankfort horizontal plane when mounted using Orbitale as anterior point of reference [Figure 9].

The study conducted by Bailey and Nowlin^[2] showed that the middle notch on the incisal pin was a better third point of reference than the Orbitale. The authors found that the mean angle between the occlusal plane and the Frankfort horizontal plane was 7.5 degrees greater when Orbitale (12 degrees) was used as the third point of reference and 4.7 degrees lesser when incisal notch (-0.2 degrees) was used as anterior reference point when compared to the radiographic value (4.5 degrees) for the above conclusion. Lauciello and Appelbaum^[12] recommended using Orbitale as an anterior point of reference and then adjusting

the pointer 7 mm above the condylar plane as the most accurate method for anatomically orienting the maxillary cast to an articulator. However, the orbital plane in the Hanau Wide Vue articulator is situated 7 mm above the condylar plane.^[13] Hence Orbitale could safely be used as the third point of reference for a facebow transfer.

It was observed that 50% of the subjects showed that the protrusive condylar guidance values were closer to the control when inferior annular notch was used as an anterior reference point, and the other 50% of subjects showed that the protrusive condylar guidance values were closer using Orbitale as an anterior reference point [Table 3].

Although the mean protrusive condylar guidance values registered on the mountings with the inferior annular notch references were closer to the mean radiographic values, they showed a wide range of variation from individual to individual. The next closer values were with that of Orbitale reference point. The range of variation was found to be lesser from individual to individual when compared to the inferior annular notch reference. Hence the Orbitale is considered to be the better anterior point of reference for the facebow records whenever Hanau Wide Vue articulator is used.

It was also observed that the protrusive condylar guidance values were consistently lesser on the left side than the right side. However, no definitive reason could be specified for this variation. More definitive conclusion could be derived with increased number of subjects.

CONCLUSIONS

Within the limitations of this study, the following conclusions were drawn:

1. A change in anterior reference point in a facebow transfer caused a change in orientation of the occlusal plane and resulted in different protrusive condylar guidance values.
2. The casts were significantly closer ($P < 0.05$) to the anatomic (radiographic) position whenever Orbitale was used as anterior reference point and right and left external auditory meati were used as posterior reference points for mounting casts on Hanau Wide Vue articulators with Hanau SpringBow.
3. The protrusive condylar guidance values registered for inferior annular notch and Orbitale as anterior points of references were significantly closer ($P < 0.05$) to the radiographic values.
4. The inferior annular notch references registered highest protrusive condylar guidance values. However, the values did not differ significantly from the radiographic values ($P = 0.31$ for right

side and $P = 0.12$ for left side).

5. The superior annular notch references registered lowest protrusive condylar guidance angles, and the values differed significantly from the radiographic values ($P < 0.05$).
6. The mountings, with Orbitale minus 7 mm references, registered the protrusive condylar guidance values which were significantly differing from the radiographic values ($P < 0.05$).

REFERENCES

1. The glossary of prosthodontic terms. *J Prosthet Dent* 2005;94:10-92.
2. Bailey JO Jr, Nowlin TP. Evaluation of the third point of reference for mounting maxillary casts on the Hanau articulator. *J Prosthet Dent* 1984;51:199-201.
3. Krueger GE, Schneider RL. A plane of orientation with an extracranial anterior point of reference. *J Prosthet Dent* 1986;56:56-60.
4. Stade EH, Hanson JG, Baker CL. Esthetic considerations in the use of face-bows. *J Prosthet Dent* 1982;48:253-6.
5. Wilkie ND. The anterior point of reference. *J Prosthet Dent* 1979;41:488-96.
6. Christensen RL. Rationale of the face-bow in maxillary cast mounting. *J Prosthet Dent* 1959;9:388-98.
7. Brandraup-Wognsen T. The face-bow: Its significance and application. *J Prosthet Dent* 1953;3:618-30.
8. Starcke EN. The history of articulators: The appearance and early history of facebows. *J Prosthodont* 2000;9:161-5.
9. Salzmänn JA. *Orthodontic practice and techniques*. Philadelphia: JB Lippincott Co; 1957. p. 139.
10. Gonzalez JB, Kingery RH. Evaluation of plane of reference for orienting maxillary casts on articulators. *J Am Dent Assoc* 1968;76:329-36.
11. Zarb GA, Bergman B, Clayton JA, MacKay HF. *Prosthetic treatment for partially edentulous patients*. St. Louis: Mosby; 1978. p. 193.
12. Lauciello FR, Appelbaum M. Anatomic comparison to arbitrary reference notch on Hanau articulators. *J Prosthet Dent* 1978;40:676-81.
13. Winkler S. *Essentials of complete denture prosthodontics*. 2nd ed. St. Louis: Elsevier; 2000. p. 156-66.
14. Hobo S, Ichida E, Garcia KT. *Osseointegration and occlusal rehabilitation*. Tokyo: Quintessence Publishing Co; 1996. p. 329-30.
15. Weinberg LA. An evaluation of the face-bow mounting. *J Prosthet Dent* 1961;11:32-42.

Source of Support: Nil, **Conflict of Interest:** None declared.

