

Clinical Report

Natural tooth pontic: A temporary immediate provisional for a difficult esthetic situation

Anuj Chhabra, I. V. Rudraprasad, D. B. Nandeeshwar

Department of Prosthodontics, Bapuji Dental College and Hospital, Davangere, India

For correspondence

Dr. Anuj Chhabra, Department of Prosthodontics, Bapuji Dental College and Hospital, Davangere-577 004, Karnataka, India.
E-mail: i_ac80@yahoo.co.in

For each patient who requires extraction of anterior teeth, there are a multitude of treatment considerations. Cosmetic demands, functional needs, treatment sequencing, timeliness and affordability are some primary concerns that must be addressed on an individual basis. A patient will generally want a cosmetic and functional prosthesis at the earliest possible opportunity. Providing the most appropriate interim prosthesis for a given patient is both challenging and recording. Here, a clinical technique for immediate interim tooth replacement is being presented, utilizing the clinical crown to assist the clinician in providing an esthetically acceptable treatment option.

Key words: Immediate provisional, natural tooth pontic

INTRODUCTION

Dentists occasionally are faced with the difficult esthetic situation of having to remove an anterior tooth because of trauma, advanced periodontal disease, root resorption or failed endodontic therapy. Although a permanent replacement, such as a metal framework removable partial denture, may be planned after the tissues have healed, the options available for a good esthetic temporary prosthesis are limited. Acrylic removable partial dentures placed immediately after the tooth is extracted are bulky, may be uncomfortable for the patient and may impede healing. Prefabricated denture teeth used as a pontic bonded to the adjacent teeth can present challenges with regard to matching color, size and shape, and often require substantial modification to achieve an acceptable appearance.

Using the natural tooth as a pontic offers the benefits of being the right size, shape and color. Moreover, the positive psychological value to the patient in using his or her natural tooth is an added benefit. When the crown of the tooth is in good condition, it can be temporarily bonded easily to the adjacent teeth with light cured restorative material.

CASE REPORT

A 45-year-old man was referred to the department of prosthodontics, with localized pain and edema in the area of maxillary right lateral incisor [Figure 1]. Clinical and radiographic examination revealed severe

mobility, purulent exudate, and excessive bone loss on all aspects of the tooth. All maxillary anterior teeth responded positive to an electric pulp tester. Because of the extensive nature of the periodontal lesion, it was decided to extract the tooth and use the clinical crown as an immediate temporary replacement until complete healing. Then a fixed partial denture could be made.

Clinical procedure

An immediate temporary fixed partial denture, having the clinical crown of the patient's natural tooth as the pontic, includes the following steps:

1. Matrix formation
2. Tooth extraction
3. Root removal and pontic contouring
4. Pontic attachment - acid etch/bonding procedure
5. Finishing and polishing
6. Verification of occlusal relationship

Matrix fabrication

A custom matrix index is made from silicone impression putty. Silicone impression putty (Speedex; Coltene/Whaledent, Inc, Ohio) base and accelerator is kneaded according to the manufacturer's instructions and adapted to the existing arch contour on the diagnostic cast [Figure 2], obtained by pouring alginate (irreversible) hydrocolloid impression of the maxillary dentate arch. The matrix includes one tooth on each side of the tooth to be extracted. Matrix is then cross

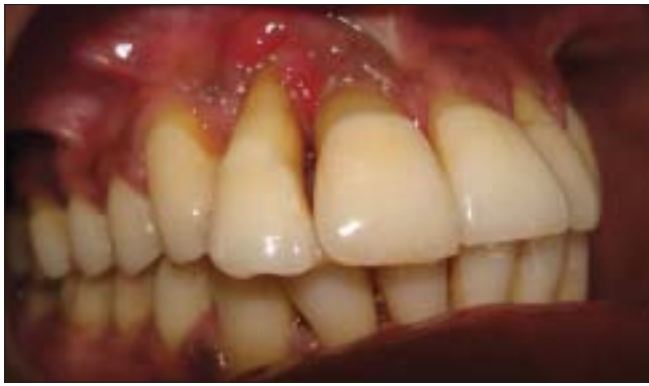

Figure 1: Preoperative Intraoral view

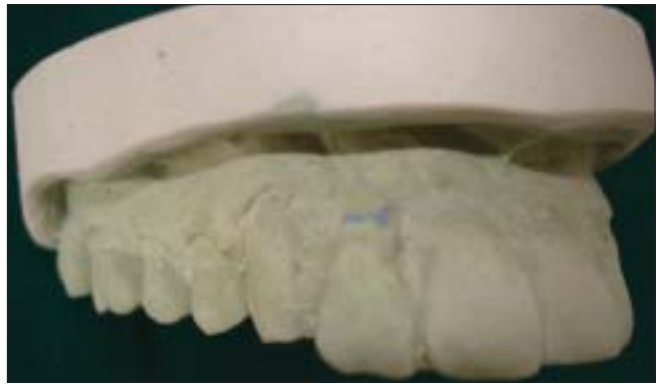


Figure 2: Preoperative Diagnostic cast

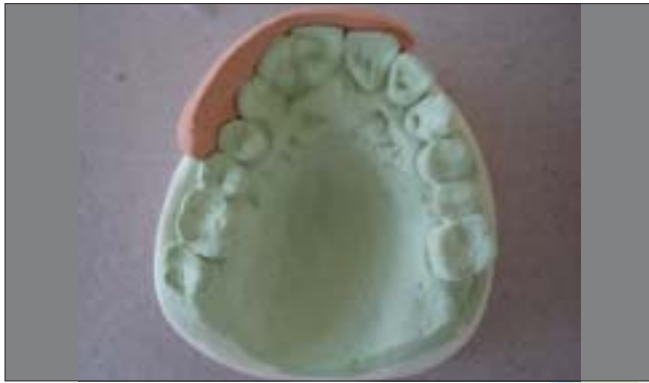

Figure 3: Putty matrix sectioned incisally

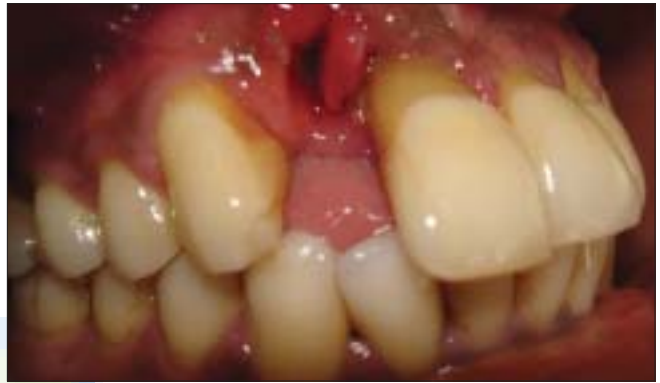

Figure 4: Post extraction Intraoral view

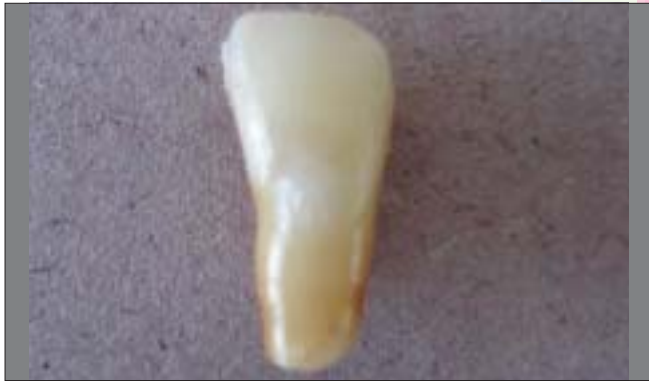

Figure 5: Contoured natural tooth pontic

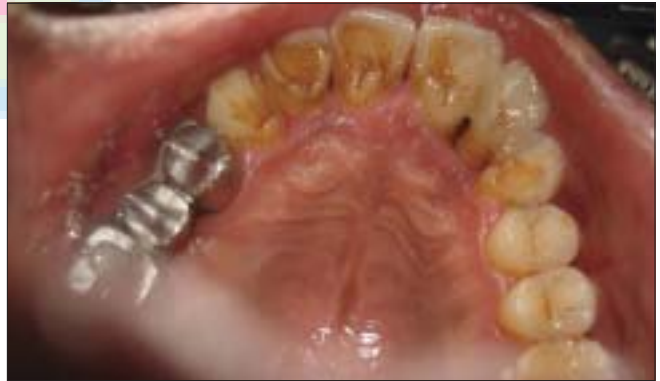

Figure 6: Postoperative palatal view of splinted tooth

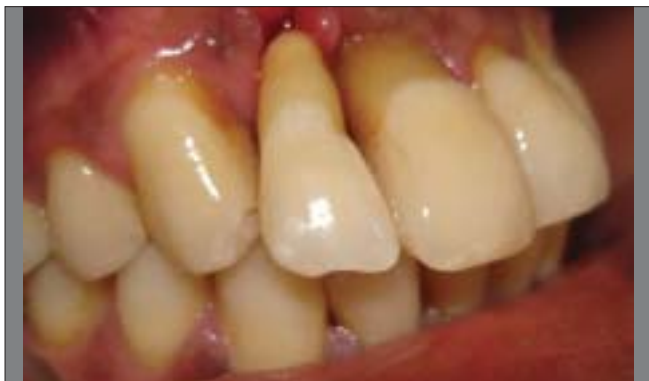

Figure 7: Postoperative labial view

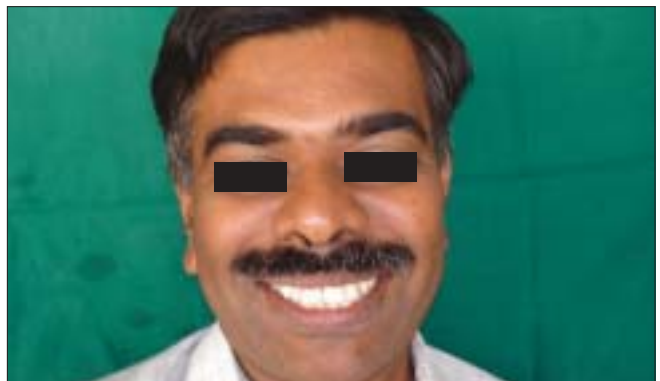

Figure 8: Definitive result

sectioned incisally into the labial and palatal half [Figure 3].

Tooth extraction

Prior to tooth extraction, an evaluation is made to help guide reshaping the pontic for proper ridge relationship. A pencil line is drawn on the tooth cervically, so as to later determine the length of natural pontic tooth. A copal resin varnish is applied over the pencil line with a small sable hair brush, to help preserve the line during extraction. The maxillary right lateral incisor is then extracted.

Root removal and pontic contouring

Following extraction [Figure 4], cervical extension of the crown is contoured, with the pencil line acting as a guide, providing contact on the facial slope of the ridge, to minimize any inflammatory response beneath the pontic.^[1] The root is removed apical to the cervical pencil line with a No. 700 bur, at ultra speed with air-water coolant. The cervical portion of the pontic is then contoured to provide the desired design, making sure that it is not in contact with the healing tissues [Figure 5]. The canal in the root is cleaned and debrided, and the apical opening of the root canal is sealed with light cure composite resin restorative material. For added mechanical retention, the grooves are placed on the lingual aspect of the extracted crown.

Pontic attachment - acid etch/bonding procedure

Acid-etch/bonding is used to attach the extracted tooth pontic to the remaining adjacent teeth. A light cure polymerizing composite resin is used (Clearfil AP-X, Kuraray America, Inc.).

The extracted tooth pontic and abutment teeth are cleaned with pumice, washed and air-dried. The proximal areas (adjacent to the extraction site) and approximately 2 to 3 mm of the facial and lingual surfaces are acid-conditioned. The adhesive resin is applied to the acid-conditioned surfaces and polymerized. The facial matrix/index, with the pontic is oriented and held in place in oral cavity. A layer of Adhesive (Clearfil SE Bond, Kuraray America, Inc.) using is again applied to the proximal and lingual surfaces of the pontic and the abutment teeth and polymerized [Figure 6]. Composite resin is added in increments to the proximal and lingual surfaces. Each increment of the composite resin is polymerized, and the facial matrix/index is removed.

Finishing and polishing

Excess composite resin material is removed with a fine diamond instrument. The composite resin is contoured in the interproximal area, to protect the gingival papilla and allow optimal maintenance^[2]

[Figure 7]. Following the contouring, the composite resin material is finished and polished on the palatal aspect.

Verification of occlusal relationship

Following final finishing and polishing of composite resin, occlusal relationship is checked and inspected for any interference to be eliminated [Figure 8].

The patient is instructed to avoid excessive chewing pressure or habits that could dislodge the natural tooth replacement. Fractures may occur between the bonded pontic and the abutment teeth, but repair can be made by an additional bonding procedure. The facial matrix should be retained for repair when the pontic is completely dislodged.

DISCUSSION

An immediate temporary fixed replacement is an ideal interim restoration, since it can be made in the dental office, following an emergency tooth extraction. With the loss of anterior teeth, the patient's primary concern is generally the restoration of an aesthetic appearance. This type of temporary replacement will satisfy the patient's cosmetic requirements until a more definitive total treatment plan can be developed.

One of the most dramatic immediate interim services is the transitional acrylic resin removable partial denture.^[3] Such a replacement however has the disadvantage of possibly traumatizing the underlying extraction site by food impaction, plaque retention, or mechanical retention. In addition, its long term use often produces irritation of palatal mucosa.^[4]

Another popular technique is the immediate fixed partial denture (FPD).^[5] Current methods of immediate temporary fixed tooth replacement may include the use of the patient's natural tooth or a plastic denture tooth. These teeth may be incorporated into temporary fixed replacements by means of a combination of resin and wire or acid-etch/bonding resin techniques. Protera^[6] described additional aids for pontic retention, i.e. small lingual preparation on the abutment teeth and a lingual groove on the pontic.

The use of the patient's natural tooth with an acid-etch/bonding resin technique offers several advantages:

Resin and wire splints which may require the grooving of teeth to facilitate wire placement are often bulky and unaesthetic. In addition, they are sometimes difficult to clean interproximally.^[2]

In a dental clinical office, there may be a limited selection of plastic denture teeth available to satisfy esthetic, size and form requirements

A natural tooth is readily available. It is aesthetic and can be easily modified for a temporary fixed replacement.

The technique is practical, economically feasible, requires limited laboratory support and materials, and can be accomplished in a single appointment.

Summary

A clinical technique for the immediate replacement of an extracted anterior tooth is presented. The clinical crown of the patient's extracted tooth is used as a pontic by attaching it to the adjacent teeth with acid-etch bonded resin. This technique provides a practical and esthetic immediate fixed tooth replacement that requires minimum materials and time.

REFERENCES

1. Stein RS. Pontic- residual ridge relationship. *J Prosthet Dent* 1966; 16:251-85.
2. Prichard JF. Advanced periodontal disease: surgical and prosthetic management, 2nd ed. Philadelphia: W.B. Saunders Co.; 1972.
3. Weintraub GS. Provisional removable partial and complete prosthesis. *Dent Clin North Am* 1989;33:399-421.
4. Ettinger RL. The etiology of inflammatory papillary hyperplasia. *J Prosthet Dent* 1975;34:254.
5. Christensen LC, Koudelka BM, Norland G. The immediate fixed partial denture. *Clin Prev Dent* 1986;8:23-6.
6. Protera JJ. Immediate fixed temporization utilizing extracted natural dentition. *J Prosthet Dent* 1981;45:286-8.

Source of Support: Nil, Conflict of Interest: None declared.

