

The prosthodontist's role in head and neck cancer and Introduction - Oncologic dentistry

Zafrula Khan, Allan G. Farman*

Departments of Maxillofacial/Oncologic Dentistry, *Maxillofacial/Oral Radiology, The James Graham Brown Cancer Center, University of Louisville, Louisville, Kentucky

For correspondence

Zafrula Khan, Maxillofacial Dental Oncology, The James Graham Brown Cancer Center, Suite 125 529, South Jackson Street, Louisville, Kentucky - 40202-3267. E-mail: zafkhan@louisville.com

A comprehensive oral and dental screening should be part of the pre-treatment workup of patients with cancer, especially those who have head and neck tumors. This screening needs to be performed by a Prosthodontist who is familiar with the pathologic process of disease and the type of treatment being rendered; and who comprehends the morbidities associated with eradicating malignancy. Oftentimes, this is a specially trained prosthodontist. According to WHO statistics, individuals living in the Indian subcontinent have the highest prevalence of oral and upper aero-digestive tract malignancies. The afflicted may develop oral complications of cancer treatment, especially from systemic chemotherapy and head and neck radiation therapy. The trend toward people maintaining their teeth longer, coupled with the rising age of the population, suggest that dentists may frequently be treating patients with cancer and should be informed about the aspects of oncologic care that will affect oral health. Unfortunately however, when the cancer curricula of dental schools was investigated, it was found that deficits in "oncologic dentistry" education included failure to provide practical clinical oncology experience in diagnosis, the decision-making process, referral procedures, management of oral complications of cancer therapy, maxillofacial rehabilitation; and psychosocial training in oncology. This article is intended as a primer for prosthodontists, most of whom undoubtedly will need to deal with cancer patients. It is suggested that the prosthodontic curriculum in India include all aspects of "oncologic dentistry."

Key words: Oncologic dentistry, cancer treatment

WHAT IS "ONCOLOGIC DENTISTRY"?

The "oncologic dentist" is responsible for:

1. Assuring that the oral cavity is prepared to reduce potential untoward effects of cancer treatment;
2. Educating the cancer patient as to the possible short- and long-term complications, no matter what anti-cancer therapies are used;
3. Training the cancer patient in oral hygiene methods and therapeutics needed to preserve oral health;
4. Where necessary, producing intra-oral shields and positioners for radiation therapy;
5. Provision of services to correct surgical defects consequent to cancer treatment (often requiring special training in prosthodontics); and
6. Long term follow-up, evaluation and treatment of the cancer patient for complications of therapy – always with an eye to the possibility of lesion recurrence.^[1-3,6-10] The prosthodontist/oncologic dentist should provide timeline for the head and neck surgeon, medical oncologist and radiation oncologist,

in which all necessary dental treatment will be completed.^[1]

The prosthodontist/oncologic dentist plays an important role in the prevention, stabilization and treatment of oral and dental problems that can compromise the cancer patient's health and quality of life during and after the cancer treatment. Moizan *et al* sent a questionnaire to 164 practitioners caring for head and neck cancer patients and evaluated dental treatments and related ethical considerations.^[11] The absence of a dental consultation was considered a serious problem that could reduce the patient's preventive care and prosthetic rehabilitation, thereby reducing the quality of life for these patients.

The frequency of oral cancer as a percentage of all cancers, varies tremendously among different geographic regions. The oral sites affected also vary. In India the percentage can be one-third or more, whereas in the United States and Europe, oral cancer represents approximately 3 to 5% of all cancers. Oral cancers found in the US and European populations are

most frequent on the lower lip, due to solar radiation and floor of the mouth, or upper aero-digestive tract through smoking. Lesions of the cheek mucosa are more common in persons from India, perhaps due in part, to the habit of chewing betel nut combined with tobacco and slaked lime. [Figure 1] illustrates typical clinical features of fairly advanced oral squamous cell carcinomas. Approximately 85% of all upper aero-digestive tract malignancies are squamous cell carcinomas.

Radiology is a major tool in the hands of the prosthodontist/oncologic dentist [Figure 2]. In addition to sometimes providing the first evidence of maxillofacial cancer, a panoramic radiograph provides a valuable overview of the baseline conditions of the teeth and jaws. This baseline can help in pre-therapy dental treatment planning and also acts as a source of comparison for subsequent radiographs made during post-therapy dental and jaw evaluations. Of particular concern are dental infections that can be exacerbated during therapy and occasionally may produce osteoradionecrosis. The prosthodontist/oncologic dentist also needs to look out for tumor recurrences, metastatic lesions and new primary tumors that might occur following cancer treatment.^[12]

CANCER THERAPY EFFECTS ON ORAL TISSUES

Radiation therapy and chemotherapy are particularly effective in destroying rapidly dividing cells, hence they have value in cancer treatment.^[13] The tissues of the oral mucosa, the salivary glands and blood vessels can be damaged as the result of such therapies. Head and neck cancer patients often experience unwanted oral effects that have both short and long-term implications.

Oral mucositis

Oral mucositis is a common side-effect of radiation and certain chemotherapy agents [Figure 3]. Luglie *et al* made a longitudinal evaluation of 30 patients undergoing antineoplastic chemotherapy.^[14] 5-fluorouracil was always involved. The study lasted one year. The research subjects underwent professional oral hygiene, were educated in home oral hygiene and were prescribed antibacterial rinses. The control group of 33 patients was not provided supplemental dental services. Visible plaque and gingival bleeding were taken from each patient and the state of the mucosa was evaluated according to the WHO recommendations. The values of the bleeding and plaque indices were considerably diminished between the first and the last visit, in nearly all the patients; the incidence of oral mucositis in the treated group was 20%, while in the control group it was 66%. It was concluded that pro-

fessional and home oral hygiene and the use of antibacterial rinses can reduce the incidence of oral mucositis, as a side effect of chemotherapy.^[14]

Xerostomia and radiation caries

Xerostomia, commonly called "dry mouth," is not infrequent among patients who have been treated with head and neck radiation therapy.^[15] It may also be a complication of certain medications and of connective tissue or immunological disorders (e.g., Sjögren's syndrome). Xerostomia from Radiation therapy often is associated with a reduction in salivary flow. Complications of xerostomia include increased dental caries experience – "radiation caries," candidiasis and difficulty with the use of removable dentures.^[15] Remedies for xerostomia usually are palliative. There may also be impediment of speech and swallowing.

Periodontal disease

Marques and Dib studied periodontal changes in patients undergoing head and neck radiation therapy.^[16] Clinical periodontal parameters (probing depth, clinical attachment level, gingival recession, plaque index and bleeding on probing) were assessed on 27 patients, before and 6 to 8 months following radiation therapy. The greatest changes occurred in clinical attachment level: overall, 70% of the patients showed a loss, with 92% of these having loss in the mandible. Attachment loss was directly related to the field of radiation and was greater when the jaws were actually included in the irradiated area. It was concluded that periodontal status should be evaluated prior to and following radiation therapy in the oral and maxillofacial region, to help ensure that periodontal health is maintained in oncology patients.

The infected periodontium can act as a focus for systemic infection in cancer patients suffering neutropenia as a result of high-dose chemotherapy.^[17] Raber-Durlacher *et al* concluded that assessment of a patient's periodontal condition before the onset of profound neutropenia is critical to the diagnosis and the management of potentially life-threatening infections.^[17]

Osteonecrosis

Late complications such as osteoradionecrosis, are attributed to radiation therapy^[18-20] [Figure 4]. The long-term problems largely arise from blood vessel damage, essentially endarteritis obliterans and reducing tissue vascularity [Figure 5].

The interpretation of data derived from particular series can be difficult, due to the different scoring methods and classification systems used for the evaluation of post-radiation bone damage.^[19] The incidence of osteoradionecrosis in head and neck cancer patients managed with radiation therapy varies widely

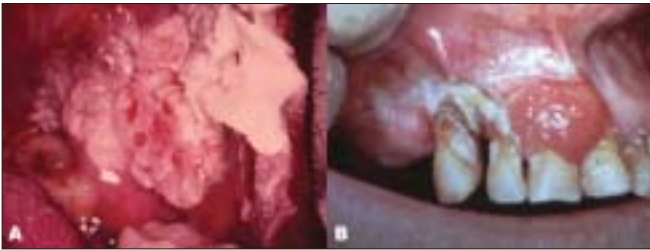

Figure 1: Clinical features of advanced oral squamous cell carcinoma. A. Buccal mucosa – note the mixed leukoplakia and erythroplakia (white and red patches) in this case; B. Gingival carcinoma

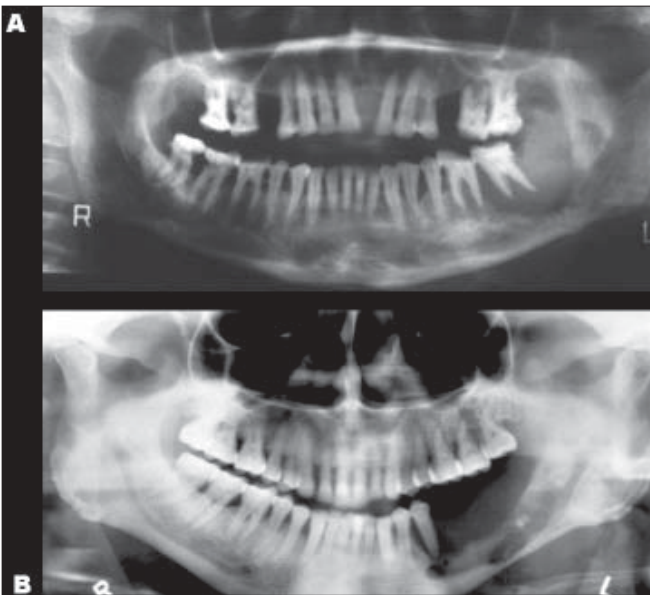


Figure 2: Panoramic radiographs from patients having advanced oral cancer with secondary invasion of the mandible. Note the “saucerization” of the upper surface of the left side of the mandible in both of these cases. Both cases also show “floating teeth” where supporting bone has been resorbed. Case B shows invasion of the mandibular canal.

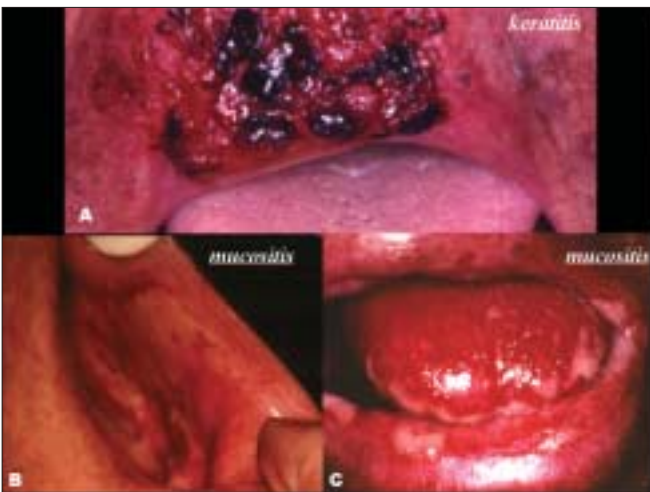

Figure 3: Post-irradiation keratitis and mucositis

in the literature from 0.4% to 56%.^[19] Although osteoradionecrosis occurs typically in the first three years after radiation therapy, patients probably remain at indefinite risk. Factors that may be associated with the risk of osteoradionecrosis include treatment-related variables such as radiation therapy dose, field size and volume of the mandible irradiated with a high dose; patient-related variables such as periodontitis, pre-irradiation bone surgery, oral hygiene, alcohol and tobacco abuse and dental extraction following radiation therapy and tumor-related factors such as lesion size and lesion proximity to bone.

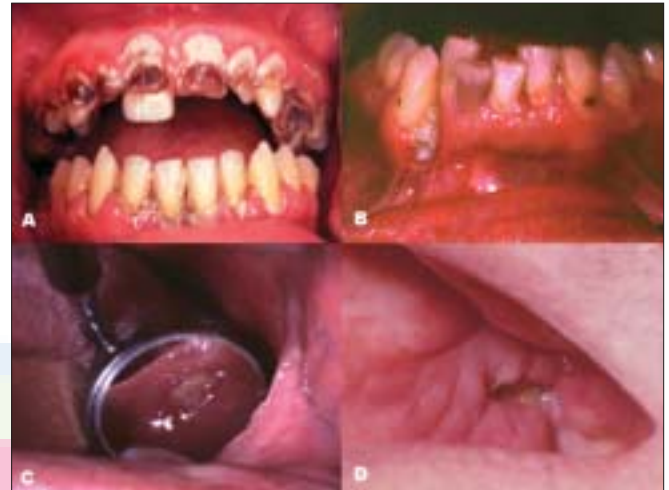

Figure 4: “Radiation caries” can result from reduced salivary flow and discomfort in tooth brushing due to mucositis (A). Necrotic bone sequestration is an ominous sign of osteoradionecrosis post-radiation to the jaws (C-D).

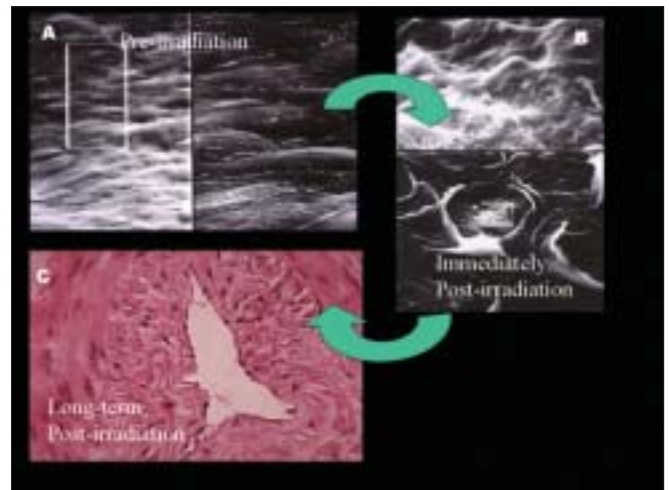


Figure 5: Vascular changes are key to post-irradiation complications. The normal and immediately post-irradiated endothelial cell linings of a rabbit artery are illustrated in the scanning electron micrographs, A and B respectively. Long term changes are luminal narrowing due to endarteritis obliterans (C) – H and E stained histologic slide.

In a recent study, the incidence of osteoradionecrosis of the jaws after irradiation using modern three-dimensional planning as well as hyperfractionation or moderately accelerated irradiation, was evaluated and compared with the incidence in earlier times.^[21] Studer *et al* reviewed the records of 268 head and neck cancer patients irradiated with a dose to the mandible of at least 60 Gy. All patients had computerized dose calculation with isodose charts. The long-term cumulative incidence of osteoradionecrosis needing mandibular resection after conventional fractionation was 6.2% (60-66.6 Gy target dose) or 20.1% (> 66.6-72 Gy); 6.6% after hyperfractionated irradiation with a target dose 72-78.8 Gy; no case after concomitant boost irradiation according to the MD Anderson regime with a dose of 63.9-70.5 Gy; and 17+% (small patient number) after 6 x 2 Gy/week or 7 x 1.8 Gy/week and a total target dose of 66-72 Gy. Comparison of the incidence of osteoradionecrosis during the period 1980-90 with the following period 1990-98, showed a decrease in risk to approximately 5% using modern three-dimensional techniques as well as hyperfractionation, or moderately accelerated fractionation.^[21]

Oh *et al* conducted a chart review in an attempt to establish whether unerupted third molars should be removed or left in place, in patients requiring radiation therapy for cancer.^[22] Patients were divided into 2 groups on the basis of pre-irradiation extraction. Group 1 comprised patients who had impacted third molars extracted before radiation therapy (n = 55). Group 2, comprised patients in whom impacted third molars were left in place (n = 38). Before radiation therapy, 99 impacted third molars were extracted from the 55 patients in Group 1, while 55 impacted third molars were left in place in the 38 patients in Group 2. Only 4 patients (2 from Group 1 and 2 from Group 2) subsequently developed osteoradionecrosis and so, no notable difference in the incidence of osteoradionecrosis could be attributed to prophylactic removal of unerupted third molars prior to radiation therapy. Sulaiman *et al* investigated irradiated head and neck patients to evaluate those patients who developed osteoradionecrosis through dental extraction.^[23] 1,194 patients with a history of radiation to the head and neck, treated at Memorial Sloan-Kettering, were reviewed. Of these patients, 187 had subsequent dental extractions and only four of these developed osteoradionecrosis. It could be concluded that healthy teeth should be retained in patients undergoing radiation therapy.

Osteonecrosis is not only a complication of radiation therapy; it can also occur with certain chemotherapeutic regimens.^[24] Ruggiero *et al* reported that long-term use of bisphosphonates, widely used in the management of metastatic disease to the bone and in the treat-

ment of osteoporosis, can also result in osteonecrosis. The necrosis detected is otherwise typical of osteoradionecrosis. Sixty three patients were identified with refractory osteomyelitis and a history of chronic bisphosphonate therapy (56 had received intravenous bisphosphonates for at least one year and seven patients were on chronic oral bisphosphonate therapy).^[24] The typical presentation was either a nonhealing extraction socket, or an exposed jawbone refractory to conservative debridement and antibiotic therapy. The biopsy showed no evidence of metastatic disease. The majority of the patients required surgical removal of the necrotic bone. In view of the widespread use of chronic bisphosphonate therapy, the observation of an associated risk of osteonecrosis of the jaw should alert practitioners to monitor for this potential complication. Early diagnosis might reduce morbidity resulting from advanced destructive lesions of the jawbone. Periodic panoramic radiography is warranted in such patients.

Local application of high concentrations of fluoride gel, as well as good oral hygiene are the most appropriate measures to implement, for prevention of dental caries and other complications in patients treated by radiation or chemotherapy.^[6,25] Pasquier *et al* carried out a systematic review on the peer-reviewed literature concerning the use of hyperbaric oxygen therapy in the treatment of radiation-induced lesions.^[18] They concluded that, while more controlled randomized trials are needed, the level of evidence supports use of hyperbaric oxygen therapy for treatment of osteoradionecrosis and in prevention of osteoradionecrosis after dental extractions. A parallel systematic review, concluded that there is a lack of reliable clinical evidence for or against the therapeutic use of hyperbaric oxygen for irradiated dental implant patients.^[26]

CHILDHOOD THERAPY

While childhood malignancies are comparatively uncommon, they do occur. Treatment for malignancies, in childhood – particularly if radiation therapy is employed – can affect growth and development. Radiation to the jaws during the period of tooth formation, though comparatively rare these days, can lead to hypodontia and teeth with stunted roots.

Oguz *et al* investigated the late effects of chemotherapy treatment for childhood non-Hodgkin's lymphomas, on oral health and dental development.^[27] Thirty-six long-term survivors were included in this study and 36 volunteers with similar age and sex distribution served as controls. Both groups underwent a complete oral and dental examination for decayed, missing and filled teeth and surfaces, gingival and periodontal health, according to standard periodontal and plaque indi-

ces, enamel defects and discolorations, root malformations, eruption status, agenesis, premature apexifications and microdontia. Non-Hodgkin's lymphoma patients had significantly higher plaque index, more enamel discolorations and root malformations than did the controls, oral and dental disturbances that may be attributed to the chemotherapy regimens. It should be noted that patients with Non-Hodgkin's lymphoma sometimes receive limited (mantle field) head and neck radiation.

DENTAL RESTORATIONS AFFECTING RADIATION THERAPY PLANNING AND APPLICATION

Fuller *et al* studied dose effects of metallic dental alloys during head and neck irradiation with intensity modulated radiation therapy (IMRT), for base of tongue squamous cell carcinoma.^[28] Significant CT artifact was induced by metallic alloy and non-removable dental restorations in both the mandible and maxilla. Simultaneously with IMRT, thermoluminescent dosimeters (TLDs) were placed in the oral cavity. After a series of three treatments, the data from the TLDs and software calculations were analyzed. Analysis of mean *in vivo* TLD dosimetry revealed that differentials from software predicted dose calculation that fell within acceptable dose variation limits. IMRT dose calculation software proved to be a relatively accurate predictor of dose attenuation and augmentation, due to dental alloys within the treatment volume, as measured by intra-oral thermoluminescent dosimetry.

Dental outcomes

Allison *et al* studied the relationship between dental status and health-related quality of life in upper aerodigestive tract cancer patients.^[29] The investigation aimed to investigate the hypothesis, that dental status is a predictor of quality of life. A cross-sectional study design was used with a sample of 188 subjects. Data were collected on socio-demographic, disease, treatment and dental status. Linear multiple regression analysis was used to determine those variables with a significant independent association with quality of life. Two multivariate models were developed, each containing age, gender, employment status, cancer site and disease stage, plus either the dental status category "partially dentate with no prosthesis" (F-value = 7.31; $P < 0.0001$; $r^2 = 0.20$) predicting a significantly worse health-related life quality, or the dental status category "edentulous with prostheses" (F-value = 7.56; $P < 0.0001$; $r^2 = 0.20$), predicting a significantly better quality of life. Furthermore, the "partially dentate with no prosthesis" group reported significantly more "problems with their teeth" (ANOVA, $P = 0.0004$), significantly more "trouble eating" (ANOVA, $P = 0.024$) and

significantly more "trouble enjoying their meals" (ANOVA, $P = 0.01$). The results of this study indicate that dental status has an important effect on health-related quality of life in post-therapeutic upper aerodigestive tract cancer patients.

Many head and neck cancer patients are treated with high-dose radiation therapy to the oral cavity and surrounding structures. Significant side effects occur in both the acute phase and in the long term. A dedicated multidisciplinary team of medical and radiation oncologist, head and neck surgeon, rosthodontist/oncologic dentist, dietician, physical therapist, social worker and in some instances, plastic surgeon and psychologist, is needed to provide the optimal supportive care for these patients.^[30] Osseointegrated implants used in the rehabilitation of patients who have undergone head and neck surgery, have provided a reliable means of retaining intraoral and extraoral prostheses.^[1] With close communication between the head and neck surgeon and the prosthodontist/oncologic dentist and careful patient selection, optimized outcomes are more likely.

The techniques to fabricate intraoral radiation shields/positioners and care for xerostomia, will be discussed in an article to follow.

REFERENCES

1. Maureen S. The expanding role of dental oncology in head and neck surgery. *Surg Oncol Clin N Am* 2004;13:37-46.
2. Harrison JS, Dale RA, Haveman CW, Redding SW. Oral complications in radiation therapy. *Gen Dent* 2003;51:552-60.
3. Huber MA, Terezhalmay GT. The head and neck radiation oncology patient. *Quintessence Int* 2003;34:693-717.
4. Meraw SJ, Reeve CM. Dental considerations and treatment of the oncology patient receiving radiation therapy. *J Am Dent Assoc* 1998;129:201-5.
5. Rankin KV, Burznski NJ, Silverman S Jr, Scheetz JP. Cancer curricula in U.S. dental schools. *J Cancer Educ* 1999;14:8-12.
6. Barillot I, Horiot JC. Prevention of caries and osteoradionecrosis in patients irradiated in oncology. Critical review. *Rev Belge Med Dent* 1999;54:205-7.
7. Cengiz M, Ozyar E, Ersu B, Akyol FH, Atahan IL. High-dose-rate mold brachytherapy of early gingival carcinoma: A clinical report. *J Prosthet Dent* 1999;82:512-4.
8. Oelgiesser D, Levin L, Barak S, Schwartz-Arad D. Rehabilitation of an irradiated mandible after mandibular resection using implant/tooth-supported fixed prosthesis: A clinical report. *J Prosthet Dent* 2004;91:310-4.
9. Taniguchi H. Radiation therapy prostheses. *J Med Dent Sci*. 2000;47:12-26.
10. Schiodt M, Hermund NU. Management of oral disease

- prior to radiation therapy. *Support Care Cancer* 2002;10:40-3.
11. Moizan H, Meningaud JP, Giumelli B, Herve C. Head and Neck Cancer Committee. Committee on cancer of the upper aerodigestive tract and survey on buccodental aspects. Report of 164 teams. *Rev Stomatol Chir Maxillofac* 2003;104:5-9.
 12. Marsiglia H, Haie-Meder C, Sasso G, Mamelle G, Gerbaulet A. Brachytherapy for T1-T2 floor-of-the-mouth cancers: The Gustave-Roussy Institute experience. *Int J Radiat Oncol Biol Phys* 2002;52:1257-63.
 13. Shaw MJ, Kumar ND, Duggal M, Fiske J, Lewis DA, Kinsella T, *et al.* Oral management of patients following oncology treatment: literature review. *Br J Oral Maxillofac Surg* 2000;38:519-24.
 14. Luglie PF, Mura G, Mura A, Angius A, Soru G, Farris A. Prevention of periodontopathy and oral mucositis during antineoplastic chemotherapy. *Minerva Stomatol* 2002;51:231-9.
 15. Guggenheimer J, Moore PA. Xerostomia: Etiology, recognition and treatment. *J Am Dent Assoc* 2003;134:61-9.
 16. Marques MA, Dib LL. Periodontal changes in patients undergoing Radiation therapy. *J Periodontol* 2004;75:1178-87.
 17. Raber-Durlacher JE, Epstein JB, Raber J, van Dissel JT, van Winkelhoff AJ, Guiot HF, *et al.* Periodontal infection in cancer patients treated with high-dose chemotherapy. *Support Care Cancer*. 2002;10:466-73.
 18. Pasquier D, Hoelscher T, Schmutz J, Dische S, Mathieu D, Baumann M, *et al.* Hyperbaric oxygen therapy in the treatment of radio-induced lesions in normal tissues: A literature review. *Radiother Oncol* 2004;72:1-13.
 19. Jereczek-Fossa BA, Orecchia R. Radiation therapy-induced mandibular bone complications. *Cancer Treat Rev* 2002;28:65-74.
 20. Reuther T, Schuster T, Mende U, Kubler A. Osteoradionecrosis of the jaws as a side effect of Radiation therapy of head and neck tumour patients - A report of a thirty year retrospective review. *Int J Oral Maxillofac Surg* 2003;32:289-95.
 21. Studer G, Gratz KW, Glanzmann C. Osteoradionecrosis of the mandible in patients treated with different fractionations. *Strahlenther Oncol* 2004;180:233-40.
 22. Oh HK, Chambers MS, Garden AS, Wong PF, Martin JW. Risk of osteoradionecrosis after extraction of impacted third molars in irradiated head and neck cancer patients. *J Oral Maxillofac Surg* 2004;62:139-44.
 23. Sulaiman F, Huryn JM, Zlotolow IM. Dental extractions in the irradiated head and neck patient: a retrospective analysis of Memorial Sloan-Kettering Cancer Center protocols, criteria and end results. *Oral Maxillofac Surg* 2003;61:1123-31.
 24. Ruggiero SL, Mehrotra B, Rosenberg TJ, Engroff SL. Osteonecrosis of the jaws associated with the use of bisphosphonates: a review of 63 cases. *J Oral Maxillofac Surg* 2004;62:527-34.
 25. Piret P, Deneufbourg JM. Mandibular osteoradionecrosis: Sword of Damocles of Radiation therapy for head and neck cancers? *Rev Med Liege* 2002;57:393-9.
 26. Coulthard P, Esposito M, Worthington HV, Jokstad A. Therapeutic use of hyperbaric oxygen for irradiated dental implant patients: A systematic review. *J Dent Educ* 2003;67:64-8.
 27. Oguz A, Cetiner S, Karadeniz C, Alpaslan G, Alpaslan C, Pinarli G. Long-term effects of chemotherapy on orodental structures in children with non-Hodgkin's lymphoma. *Eur J Oral Sci* 2004;112:8-11.
 28. Fuller CD, Diaz I, Cavanaugh SX, Eng TY. In vivo dose perturbation effects of metallic dental alloys during head and neck irradiation with intensity modulated radiation therapy. *Oral Oncol* 2004;40:645-8.
 29. Allison PJ, Locker D, Feine JS. The relationship between dental status and health-related quality of life in upper aerodigestive tract cancer patients. *Oral Oncol* 1999;35:138-43.
 30. Specht L. Oral complications in the head and neck radiation patient. Introduction and scope of the problem. *Support Care Cancer* 2002;10:36-9.