

# Validity of soft tissue landmarks in determining the occlusal plane

K. Shigli<sup>1</sup>, B. R. Chetal, J. Jabade

<sup>1</sup>Department of Prosthodontics and K.L.E.Society's Institute of Dental Sciences, Karnataka, India

For correspondence

Kamal Shigli, A-9, J.N.M.C. Staff Quarters, Nehru Nagar, Belgaum - 590010, E-mail:kamalshigli@yahoo.co.in

The orientation of the occlusal plane is an important clinical procedure in prosthodontic treatment for edentulous patients. Various intraoral and extraoral landmarks have been used for the orientation of the occlusal plane, but none of them give sufficient guidelines for that purpose. Therefore, a study was carried out to ascertain the role of intraoral and extraoral soft tissue landmarks in determining the occlusal plane. 30 Indian subjects ranging in age from 19-23 years were selected from a group of approximately 200 dental students. The soft tissue landmarks considered in the study were retromolar pad, parotid papilla, commissure of the lips, buccinator groove, and ala-tragus line. An indigenously fabricated "Occlusal plane relator" was used to find out the relative parallelism of the ala-tragus line and the occlusal plane. This device had a base with a vertical arm over which a sliding ball and socket joint was placed. This joint had a direct connection with the anterior occlusal plane indicator and ala-tragus line indicator. Absolute mean was taken of the two readings on ala-tragus line indicator on either side of the face. The line in which the difference between the two readings was least was parallel to the occlusal plane. The lower 1/3rd of the retromolar pad was observed to be consistent with the mandibular occlusal plane. The mean distance of the parotid papilla was 2.56 mm above the maxillary occlusal plane. The mean values of all readings of buccinator groove was 0.94 mm below the mandibular occlusal plane. In this study close correlation was observed between the mandibular occlusal plane and the commissure of the lips; the mandibular occlusal plane and the buccinator groove. The line drawn from the ala of the nose to the middle of the tragus was found to be parallel to the maxillary occlusal plane.

**Key words:** soft tissue landmarks, Occlusal plane

## INTRODUCTION

The determination of the occlusal plane is one of the most important clinical procedures in prosthodontic rehabilitation of edentulous patients. The position of the occlusal plane of orientation forms the basis for ideal tooth arrangement.

The glossary of prosthodontic terms (1999)<sup>[1]</sup> defines occlusal plane as "the average plane established by the incisal and occlusal surfaces of the teeth". Generally, it is not a plane but represents the planar mean of the curvature of these surfaces.

A plane is determined by at least three reference points that are not in a straight line. The occlusal plane is determined anteriorly by the maxillary incisor teeth and posteriorly by the retromolar pads. The junction of the upper and middle thirds of the retromolar pads are the usual posterior landmarks.<sup>[2]</sup>

Anteriorly, occlusal plane mainly helps in achieving esthetics and phonetics while posteriorly, it forms a

milling surface, where tongue and buccinator muscle are able to position the food bolus onto it and hold it there during mastication. Faulty orientation of the occlusal plane will hamper this interaction between tongue and buccinator muscle and result at one extreme in food collection in the sulcus and other extreme in biting of the cheek or tongue.<sup>[3]</sup>

Incorrect record of the occlusal plane would hamper esthetics, phonetics, and mastication. It may affect the stability of a complete denture and ultimately result in alveolar bone resorption.

Various methods utilizing the extraoral and intraoral landmarks have been advocated for the orientation of the occlusal plane. Prothero<sup>[4]</sup> suggested placing the occlusal plane 1 to 3mm below the resting upper lip line anteriorly while keeping it parallel to the ala-tragus line posteriorly. However, the length of the upper lip is variable and may not always constitute a reliable guide.

The other concepts utilize the intraoral landmarks

in the determination of the occlusal plane. These include height of the retromolar pad,<sup>[5,6,7]</sup> the lateral borders of the tongue,<sup>[6]</sup> the position of the parotid papilla,<sup>[5,8]</sup> commissures of the lips,<sup>[5]</sup> and buccinator grooves.<sup>[5,9]</sup> Sloane and Cook<sup>[10]</sup> oriented the plane on the basis of two anatomic landmarks, the anterior nasal spine and the hamular notch, and devised an instrument that projected this plane onto the edentulous maxillary cast. Boccaletti<sup>[7]</sup> modified the occlusal plane according to its relation to the inclination of the condylar path as well as according to the individual requirements of the kinematics of the lower jaw. Swenson<sup>[7]</sup> stated that the relative size and shape of the bearing area of the mandible and maxillae influence the decision as to the position of the occlusal plane. The leverage is reduced for the denture having the more unfavorable ridge size by placing the plane closer to that ridge. Rich<sup>[11,12]</sup> found a close relationship between the occlusal plane and the Hamular notch incisive papilla (H.I.P. plane). The use of the ala-tragus line to orient the occlusal plane has been controversial. This controversy is primarily due to disagreement on the exact point of reference for this line.<sup>[13]</sup> Spratley<sup>[14]</sup> described it as running from the center of ala to the center of the tragus. Sharry<sup>[15]</sup> recommended the concept without defining or illustrating it. Texts by Basker et al.,<sup>[16]</sup> Grant and Johnson,<sup>[17]</sup> and Neill and Naim<sup>[18]</sup> depicted the ala-tragus line pictorially as extending to a point at the center of tragus of ear. Boucher<sup>[19]</sup> defined Camper's line as an imaginary line that runs from the inferior border of the ala of the nose to the superior border of the tragus of the ear.

Kazanoglu and Unger<sup>[20]</sup> designed a device called Camper's plane indicator to be used for establishing the plane of occlusion in complete dentures. The device was simple, practical and accurate with all the necessary parts assembled in one instrument and the procedure could be performed by one operator.

"Cephalometrics<sup>[3,7,12,21,22]</sup> can be used to reestablish the spatial position of lost structures such as the teeth. This is achieved by identifying predictable relationships between the teeth and other cranial landmarks that are not subject to postextraction changes.

It is evident that the various concepts reported in the literature for determination of occlusal plane in complete dentures unfortunately allow variation in its location from operator to operator in the same patient.

No study has been done for the Indian population considering all the accessible landmarks. So a need was felt to evaluate the relationship between the occlusal plane, the extraoral and intraoral landmarks.

A clinical study was undertaken in young dentulous Indian subjects with the following aims and objectives, (1) to assess the relationship of intraoral and

extraoral soft tissue landmarks with the occlusal plane, (2) to determine the consistency of intraoral soft tissue landmarks, like retromolar pad, parotid papilla, commissure of lip and buccinator groove with the occlusal plane, and (3) to recommend validity of soft tissue landmarks.

## METHODOLOGY

The study was carried out in 30 Indian subjects ranging in age from 19-23 years selected from a group of approximately 200 dental students. Written consent of the subjects was taken and the subjects participated for this study voluntarily.

The subjects were selected as per the following criteria, (1):-with permanent components in ideal arch form and alignment, (2) with no history of orthodontic treatment, (3) with angle's class I relationship, (4) the maxillary central incisors and the mesiopalatal cusp of the maxillary first molars contacting a flat occlusal plane indicator, (5) with no class II operative restorations, (6) minimal attrition and (7) normal tooth form.

Impressions of maxillary and mandibular arches were made with irreversible hydrocolloid (Alginoplast; Heraeus Kulzer Dental India Private Limited, New Delhi, India) and the casts were poured in dental stone (Labstone, Kalabhai Karson Private Ltd, Mumbai). The casts were separated from the impression material 45 minutes after pouring.

### 1. Relationship of the occlusal plane to the retromolar pad

The location of the retromolar pad in relation to the plane of occlusion was determined by placing a 19 gauge straight (the straightness of the wire was determined by rolling it on a glass slab) stainless steel wire (Dento Kem, Faridabad, India), 6 inches in length, on the tip of the mandibular cuspid and by posteriorly extending the wire to the distolingual cusp tip of the mandibular 2<sup>nd</sup> or 3<sup>rd</sup> molar. The relationship of the plane of occlusion to the retromolar pad was determined by the intersection of the wire and the retromolar pad. The vertical height of the pad was divided into 3 parts (lower, middle and upper 1/3<sup>rd</sup>). Initially, this procedure was accomplished both intraorally and on the cast. Because of the consistent correlation of these two determinations, the intraoral procedure was utilized. This procedure was carried out both on the right and left sides. [Figure 1]

The distolingual cusp tip of the mandibular distal most molar was used as the distal reference as it has a closer anatomic relationship to the retromolar pad than does the distobuccal cusp. The line from the mandibular cuspid to the distobuccal cusp tip was always found lateral to the retromolar pad, therefore it was not used.



## 2. Relationship of the occlusal plane to the parotid papilla, commissure of lips and the buccinator groove

The relationship existing among the parotid papilla, the commissure of the lips, the buccinator groove and the plane of occlusion was determined by an intraoral vestibular impression.

An oral screen of autopolymerizing acrylic resin (DPI; Dental Products of India Ltd, Mumbai, India) was fabricated for each subject which extended from the distal aspect of the mandibular 2nd molar on one side to that on the other side. A single sheet of modeling wax (HDP; Hindustan Dental Products, Hyderabad, India) was placed as a spacer beneath the screen.

A loop of 21 gauge stainless steel wire (Dento Kem, Faridabad, India) which would serve as a handle was made and placed at the level of maxillary central incisors. The perforations were made at the periphery on each side of the oral screen with a no.6 round bur to facilitate mechanical interlocking of the irreversible hydrocolloid impression material. The oral screen was used to support irreversible hydrocolloid material for the vestibular impression.[Figure 2]

The subject was seated in an upright position on the

dental chair and was instructed to occlude the teeth in centric occlusion. The oral screen was checked in the subject's oral cavity for vestibular extension and care was taken to avoid soft tissue impingement. The subject was then explained the procedure in a language he/she understood the best.

The oral screen was then removed from the subject's oral cavity and the position of the parotid papillae were located, dried and marked with an indelible pencil. The oral screen was then reinserted into the subject's oral cavity. A thin mix of irreversible hydrocolloid was injected completely around the vestibule with a disposable 2ml syringe (Unolok; Hindustan Syringes and Medical Devices Ltd., Faridabad,India). It was made certain that the distal aspects of the buccal vestibules on both sides were filled. The subject was then asked to pucker his/her lips as in sucking with the lips slightly separated by the impression material, but without the loss of occlusal contact of teeth.. When set, a fine mark using an indelible pencil was placed at the commissure of the lips on either side of the vestibular impression. It was seen that the position of the papillae on either side were transferred on the vestibular impression. If not, they were marked again, the previous marking helped to mark the exact location of the parotid papilla.[Figure 3]

The impression was then removed from the mouth, washed with water and trimmed as required, until both the maxillary and mandibular casts accurately fit the impression made in centric occlusion..

Two fine marks were also placed at the starting and the distal termination of the buccinator groove on either side of the vestibular impression.[Figure 4]

A stone index was then poured over the vestibular impression to obtain the record of the parotid papilla, the commissure of the lips and the buccinator grooves. The index was joined to the periphery of the base of the maxillary and mandibular casts. After the stone had set, the vestibular impression, the maxillary and mandibular casts were removed.

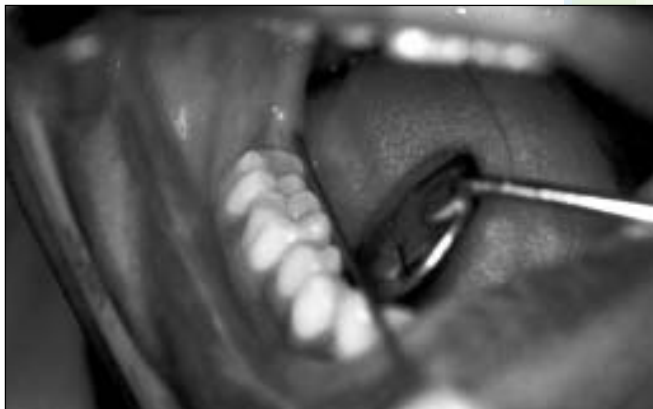

Figure 1: Relation of the occlusal plane to the retromolar pad

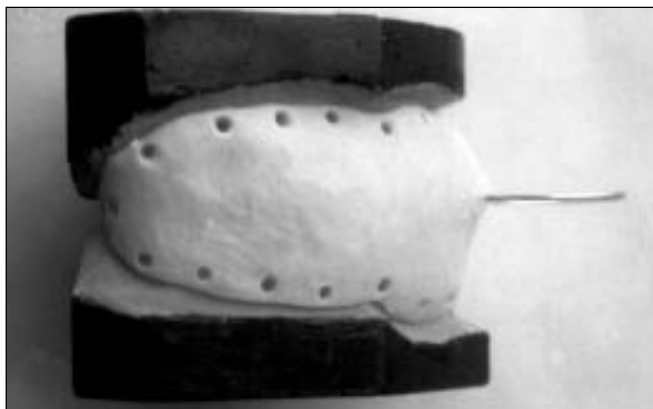


Figure 2: Oral screen placed on casts in centric occlusion

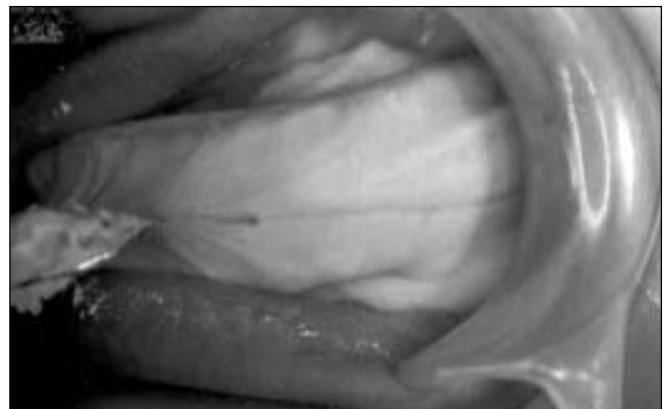

Figure 3: Vestibular impression showing marking of commissure of lip and buccinator groove

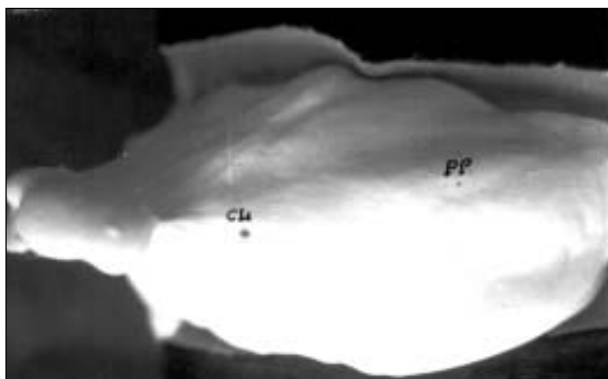


Figure 4: Vestibular impression showing commissure of lip (CL), buccinator groove and parotid papilla (PP) placed on casts in centric occlusion

The casts with the index was then transferred onto the Bego's surveyor where the occlusal plane was marked with a custom-made marking accessory. [Figure 5]

The linear distance of the commissure, starting and termination of the buccinator groove and the parotid papilla from the occlusal plane were measured with a divider and scale, the readings were recorded, as per performa attached. (Appendix)

### 3. Relationship of the occlusal plane to the ala-tragus line

In order to find out the relative parallelism of the ala-tragus line and the occlusal plane an apparatus was devised which would directly indicate the parallelism if any between the two planes. An instrument was specially designed and fabricated indigenously for

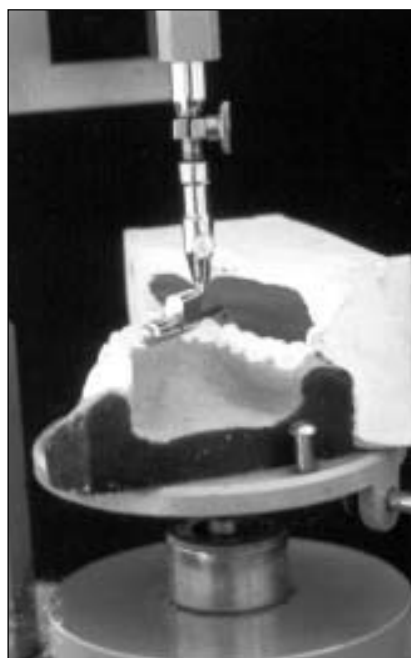

Figure 5: Procedure for marking the occlusal plane with a custom-made marking accessory

the purpose of this study and was called the 'Occlusal Plane Relator'; hereafter referred to as OPR. [Figure 6]

The occlusal plane relator consisted of, (1) base, (2) vertical arm, (3) horizontal arm carrying the occlusal plane indicator, (4) thumb screw, (5) ball and socket joint, (6) anterior occlusal plane indicator (AOPI), (7) hinge joints, (8) right and left ala-tragus line indicators (ATLI), (9) occlusal plane indicator (OPI) and (10) screws to maintain height of ala-tragus line indicator

The subject was seated in an upright position on the dental chair. Three lines were drawn on either side of the subject's face from the prominent part of the ala of the nose to the inferior, middle and superior parts of the tragus with a wet thread coated with dental stone powder.

The OPI was placed in the subject's mouth. The anterior occlusal plane indicator was made parallel to the subject's inter-pupillary line. The mesial surface of maxillary central incisors and the mesiopalatal cusp of the maxillary 1<sup>st</sup> molars contacted the OPI. This denoted the occlusal plane of the subject. The subject held the OPI firmly under biting pressure thus maintaining the contact with the maxillary central incisors and first molars. [Figure 7]

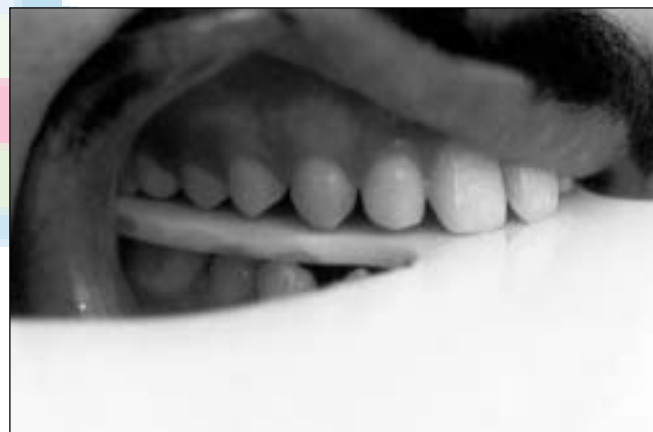

Figure 6: OPI in relation to occlusal plane

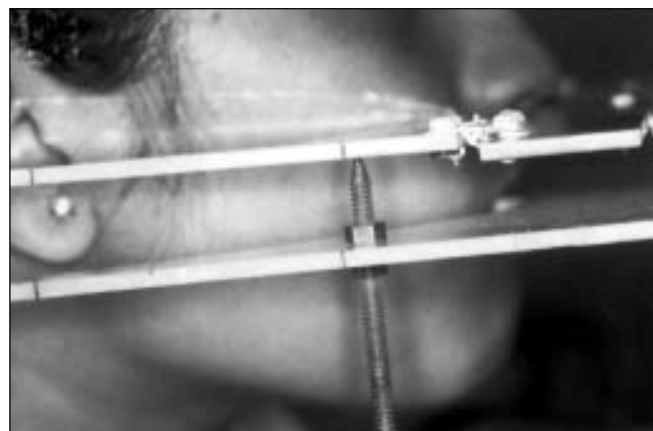

Figure 7: Right ala-tragus line indicator showing parallelism with inferior ala-tragus line





The right ATLI was first adjusted according to the line drawn on the subject's face from ala of the nose to the inferior part of the tragus. The readings at two marked points on the ATLI were taken both anteriorly and posteriorly by three different operators and their means were noted down. The readings were taken with a vernier caliper (Dentaurum, Germany) with a correction scale of 1/10th mm. [Figure 8] Then the left ATLI was adjusted to a similar line and the readings recorded. This procedure was repeated on either side, for middle and superior ala-tragus lines and the readings were noted down.

The difference of the two readings recorded for the inferior, middle and superior parts of the tragus was taken out separately on the right and left sides of the subject's face to see the parallel line. The line in which the difference between the two readings was least was taken as parallel to the occlusal plane.

Statistical analysis was carried out as mean, standard deviation, "t" value and coefficient of variation (C of V) for intraoral and extraoral landmarks.

## RESULTS

The results obtained were subjected to statistical analysis.

### Relation to the retromolar pad

In 56.7% of subjects, the mandibular occlusal plane coincided with the lower part of the retromolar pad. In 43.3%, it coincided with the middle part of the retromolar pad and in none it coincided with the upper part of the retromolar pad.

These findings suggest that the mandibular occlusal plane coincided with lower 1/3<sup>rd</sup> of the retromolar pad in the majority of cases. It is also evident that mandibular occlusal plane is always inferior to upper 1/3<sup>rd</sup> of retromolar pad.

### Relation to the parotid papilla

The mean distance of the parotid papilla was 2.56

mm above the maxillary occlusal plane.

### Relation to the commissure of the lips

In this study, it was observed that the commissure of the lip was inferior to the mandibular occlusal plane by 1.37 mm.

### Relation to the buccinator groove

The determination of the occlusal plane by the vestibular impression was adapted from the work of Merkeley<sup>[9]</sup> who stated, "Of great interest to the prosthodontist was the fact that the bottom of the groove cut by the buccinator muscle proved to correspond with the occlusal plane".

The mean values of all readings of buccinator groove was 0.94 mm below the mandibular occlusal plane.

Since the occlusal plane and the buccinator groove have been found to be closely related and do not vary appreciably from each other, the buccinator groove can serve as a guide in determination of the occlusal plane.

Buccinator groove proved to be the most reliable intraoral landmark with C of V value as 53.66%. Commissure of the lip was observed to be the next reliable landmark with C of V value as 64.46%. Parotid papilla had C of V value of 180.57%.

### Relation to the ala-tragus line

This study concluded that the line drawn from the ala of the nose to the middle of the tragus was parallel to the maxillary occlusal plane with an absolute mean of 0.21 cm. The line drawn from the ala to the inferior part of the tragus was the next parallel to the occlusal plane with an absolute mean of 0.27 cm. The line from the ala to the superior part of the tragus had an absolute mean of 0.50 cm.

## DISCUSSION

The location of soft tissue landmarks are extremely difficult to accurately measure. The above results are presented with the knowledge that some errors might have been incorporated. However, a determined effort was made to reduce soft tissue distortion to a minimum.

The lower 1/3<sup>rd</sup> of the retromolar pad was observed to be consistent with the mandibular occlusal plane. It is a prominent and stable anatomical landmark which is easily accessible.

In this study, close correlation was observed between the occlusal plane and the buccinator groove; the occlusal plane and the commissure of the lips. Therefore, a vestibular impression technique is suggested for determining the location of the occlusal plane after establishing the vertical dimension and centric relation in completely edentulous patients.

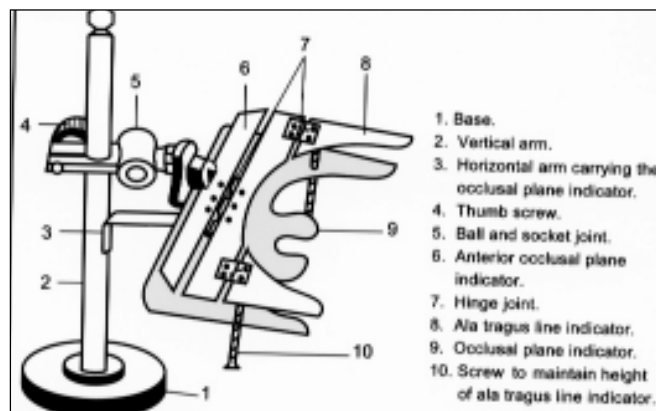


Figure 8: Occlusal plane relator (OPR)

**Table 1: Relationship of the mandibular occlusal plane to the retromolar pad in 30 subjects**

Part of retromolar pad	Percentage	
Lower part	17 17	56.7%
Middle part	13 13	43.3%
Upper part	0 0	0.0%

**Table 2: Mean vertical distance of parotid papilla above the maxillary occlusal plane in 30 subjects**

Side	Mean vertical distance	Overall Mean
Right	2.5 mm	2.56 mm
Left	2.6 mm	

**Table 3: Mean vertical distance of commissure of the lip to the mandibular occlusal plane in 30 subjects**

Side	Mean vertical distance	Overall mean
Right	-1.68 mm	-1.37 mm
Left	-1.05 mm	

**Table 4: Vertical distance of the mandibular occlusal plane to the buccinator groove in mm) in 30 subjects**

Right side		Left side		Overall mean
Canine	First molar	Canine	First molar	
-1.95	+0.28	-1.90	-0.18	-0.94

**Table 5: Table of analysis by coefficient of variation (C of V) for the intraoral landmarks in 30 subjects**

Intraoral landmark	C of V
Parotid papilla	180.57%
Commissure of lip	64.46%
Buccinator Groove	53.66%

**Table 6: Table of 't' values for the intraoral landmarks on the right and left sides in 30 subjects**

Intraoral landmarks	t value	Inference
Parotid papilla	0.31	Not significant
Commissure of the lip	1.12	Not significant
Buccinator groove (canine region)	0.09	Not significant
Buccinator groove (molar region)	0.68	Not significant

**Table 7: The mean linear measurement of maxillary occlusal plane from ala of the nose to inferior, middle and superior borders of the tragus (in cm) in 30 subjects**

Border of the tragus	Side	
	Right	Left
Superior	2.57	2.42
Middle	2.16	2.00
Inferior	1.70	1.53

**Table 8: Table of analysis by 'coefficient of variation' (C of V) for the superior, middle and inferior borders of the tragus in 30 subjects**

Border of the tragus	C of V
Superior	178.98%
Middle	96.65%
Inferior	117.55%

**Table 9: Absolute mean (in cm) of the lines drawn from ala of the nose to superior, middle and inferior borders of the tragus relative to the maxillary occlusal plane in 30 subjects**

Border of the tragus	Absolute mean
Superior	0.50
Middle	0.21
Inferior	0.27

**Table 10: Table of 't' values for the inferior, middle and superior borders of the tragus on the right and left sides in 30 subjects**

Border of the tragus	t value	Inference
Inferior	1.50	Not significant
Middle	1.33	Not significant
Superior	1.24	Not significant

However, this procedure requires a lot of time and patience. May be because of these reasons, it has not gained much of popularity, though it was reported to be a more reliable guide.

The buccinator groove should also be carefully employed as a guide line in edentulous patients where there is progressive loss of muscle tone due to aging process.

## CONCLUSION

From this study, we could not conclude to any single method for determining the occlusal plane. But using more than one of these parameters along with a judicious clinical judgment, we can be very close to the ideal occlusal plane level for an edentulous patient.

Further study is suggested considering higher age group, facial forms, Indian population of a specific race and considering both sexes so that norms for occlusal plane can be specified.

## ACKNOWLEDGMENT

Condensed from thesis presented for the partial fulfillment of the requirement for MDS (Prosthetics) submitted to Karnataka University, Dharwad.

This paper was presented at the 29th IPS Conference held at Ramoji film city, Hyderabad, November 2001.

## REFERENCES

1. Academy of Denture Prosthetics: Glossary of Prosthodontic Terms. 1977, The C. V. Mosby Co: St.Louis; J Prosthet Dent 1999.
2. Curtis TA, Shaw EL, Curtis DA. The influence of removable prosthodontic procedures and concepts on the esthetics of complete dentures. J Prosthet Dent 1987;57:315-23.
3. Monteith BD. A cephalometric method to determine the angulation of the occlusal plane in edentulous patients. J Prosthet Dent 1985;54:81-7.





4. Augsburger RH. Occlusal plane relation to facial type. *J Prosthet Dent* 1953;3:755-70.
5. Lundquist DO, Luther WW. Occlusal plane determination. *J Prosthet Dent* 1970;23:489-98.
6. Yasaki M. The height of the occlusion rim and the interocclusal distance: *J Prosthet Dent* 1961;11:26-31
7. Ismail YH, Bowman JF. Position of the occlusal plane in natural and artificial teeth. *J Prosthet Dent* 1968;20:407-11.
8. Foley PF, Latta GH. A study of the position of the parotid papilla relative to the occlusal plane. *J Prosthet Dent* 1985;53:124-6.
9. Merkeley HJ. Lower denture technic based on a proper understanding of the accessory muscles of mastication. *J Am Dent Assoc* 1957;54:769-82.
10. Sloane RH, Cook J. A guide to orientation of the occlusal plane. *J Prosthet Dent* 1953;3:33.
11. Rich H. Evaluation and registration of the H.I.P. plane of occlusion. *Aust Dent J* 1982;27:162-8.
12. Karkazis HC, Polyzois GL. Cephalometrically predicted occlusal plane: Implications in removable prosthodontics. *J Prosthet Dent* 1991;65:258-64.
13. D'Souza NL, Bhargava K. A cephalometric study comparing the occlusal plane in dentulous and edentulous subjects in relation to the maxillomandibular space. *J Prosthet Dent* 1996;75:177-82.
14. Spratley MH. A simplified technique for determining the occlusal plane in full denture construction. *J Oral Rehabil* 1980;7:31
15. Sharry JJ. Complete denture prosthodontics. 3<sup>rd</sup> Ed. McGraw-Hill: New York; 1974. p. 235.
16. Basker RM, Davenport JC, Tomlin HR. Prosthetic treatment of the edentulous patient. 1<sup>st</sup> Edn. Macmillan: London; 1976. p. 112.
17. Grant AA, Johnson W. An introduction to removable denture prosthetics. Churchill Livingstone: Edinburgh; 1983. p. 180.
18. Neill DJ, Naim RI. Complete denture prosthetics. Br John Wright Sons: 1975. p. 72-3.
19. Boucher CO. Current clinical dental terminology. 3<sup>rd</sup> Edn. CV Mosby: St. Louis; 1982. p. 175.
20. Kazanoglu A, Unger JW. Determining the occlusal plane with the Camper's plane indicator. *J Prosthet Dent* 1992;67:499-501.
21. Abrahams R, Carey PD. The use of the ala-tragus line for occlusal plane determination in complete dentures. *J Dent* 1979;7:339-41.
22. L'Estrange PR, Vig PS. A comparative study of the occlusal plane in dentulous and edentulous subjects. *J Prosthet Dent* 1975;33:495-503.

